

*Original Research Article***Histomorphological Study of Gastric Lesions: A Study of Endoscopic Biopsies at a Tertiary Care Centre**Vidya Kedarisetti¹, Perada Vasavi²¹Specialist, Department of Pathology, ESIC Super Specialty Hospital, Sanath Nagar, Telangana, India.²Assistant Professor, Department of Pathology, MNR Medical College, Fasalwadi, Sangareddy, Telangana 500019, India.**Corresponding Author:****Perada Vasavi**, Assistant Professor, Department of Pathology, MNR Medical College, Fasalwadi, Sangareddy, Telangana 500019, India.**E-mail:** drpvasavi@gmail.com**How to cite this article:**

Vidya Kedarisetti, Perada Vasavi. Histomorphological Study of Gastric Lesions: A Study of Endoscopic Biopsies at a Tertiary Care Centre. Indian J Pathol Res Pract 2020;9(2 Part I):73–76.

Abstract

Introduction: Endoscopy is a commonly done procedure among the patients presenting to gastroenterology department. Of the biopsies taken from Upper GI tract, gastric lesions constitute the majority. The present study was undertaken to determine the prevalence of gastric lesions seen on endoscopic biopsies and to estimate the usefulness of these biopsies in patient care.

Materials and Methods: The present study consisted of endoscopic biopsies from stomach received over a period of four years from May 2014 to June 2018 at the department of pathology, MNR Medical College, Sangareddy. The biopsies were fixed with 10% buffered formalin, tissue processing and H&E staining (and special stains where necessary) were done before reporting.

Results: A total of 260 cases of endoscopic biopsies from stomach were received, among which non-neoplastic lesions were slightly higher than neoplastic lesions, seen affecting male more than female. Maximum cases were in the 5th decade of life. Epithelial malignancies constituted the majority of neoplastic lesions and were categorized into various histological subtypes.

Conclusion: Even though the non-neoplastic lesions were slightly higher, the majority of neoplastic lesions were malignant. Endoscopic biopsy in correlation with imaging carries a benefit of early detection of the malignancy and thus a better outcome.

Keywords: Endoscopic biopsies; Gastric neoplasm; Histopathology.

Introduction

Endoscopic imaging has become a revolutionary tool in managing the patients with gastrointestinal lesions.¹ Imaging along with biopsy helps in the diagnosis, determination of extent and severity of lesions and also in monitoring the course of the disease with particular reference to the effects of therapy. Among the upper GI lesions, gastric lesions constitute the majority of cases.² The present study thus intends to observe the varied lesions in

gastric biopsies, their patterns of presentation and to assess the usefulness of these biopsies in patient management.

Materials and Methods

The study included endoscopic biopsies from stomach received over a period of four years from May 2014 to June 2018 at the Department of pathology, MNR Medical College, Sangareddy. The

biopsies were gently teased from the endoscopy forceps into a bottle containing 10% buffered formalin. The biopsy specimen was wrapped in a piece of filter paper and processed in a perforated capsule. After processing, the biopsies were embedded in paraffin, 4 to 5 microns thick sections were cut and 4-5 sections were taken on each slide, stained with hematoxylin and eosin. The sections were mounted with DPX and studied microscope. Special stains and IHC were used wherever necessary. The tumors were categorized as per WHO classification.

Results

From a total of 400 upper gastrointestinal endoscopic biopsies, lesions from the stomach were 260 cases accounting for 65% of the cases. Of the 260 cases involving the stomach, 133 cases were non-neoplastic lesions which constitute both inflammatory and tumor like lesion. The predominant age of presentation in non-neoplastic

cases was in 30-70 years of age (peak incidence in the 5th decade) with M: F ratio of 1.95:1. Of the 127 neoplastic cases, Maximum number of cases in the 6th decade of life (29.13%) with M: F ratio of 2.6:1. Neoplastic lesions presented more in the older age group than the non-neoplastic lesions.

Of the total 133 non-neoplastic lesions majority were in the antrum (98 cases, 73.7%). 112 lesions were inflammatory and 21 lesions were tumor like lesions. Among inflammatory lesions, chronic non specific gastritis constituted the majority with 64 cases (46.6%), followed by 18 cases (13.5%) of acute ulceration, Chronic ulcer (9 cases, 6.8%), acute on chronic gastritis (9 cases, 6.8%), H. pylori gastritis 8 cases (6.0%), atrophic gastritis (2 cases, 1.5%), and fundic gland polyp (4 cases, 3.0%).

Among 127 neoplastic cases, 125 (98.4%) were epithelial malignancy and 2 cases (1.6%) were benign neoplasms. The predominant carcinoma being tubular type of adenocarcinoma (Fig. 1, Fig.2) constituting 109 (87.2%) were located at antrum, followed by 15 cases of signet ring cell carcinoma

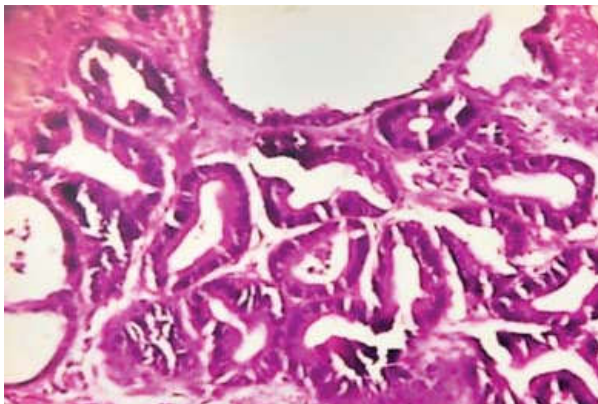


Fig. 1: Well differentiated Adenocarcinoma (H&E x400)- Tumor with well formed glands are seen to infiltrate the muscular layer.

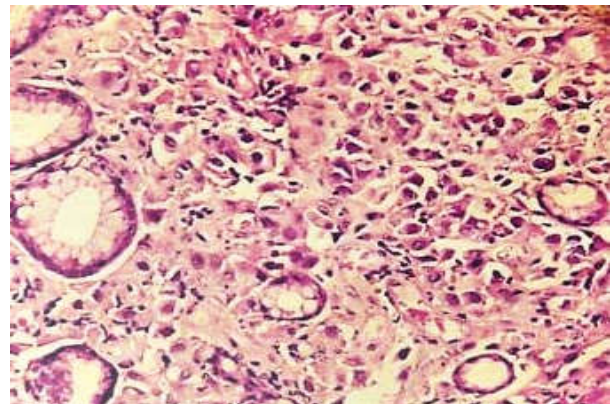


Fig. 2: Infiltrating poorly differentiated adenocarcinoma. (H&E X400) - Sheets of pleomorphic looking tumor cells arranged in sheets with little gland formation.

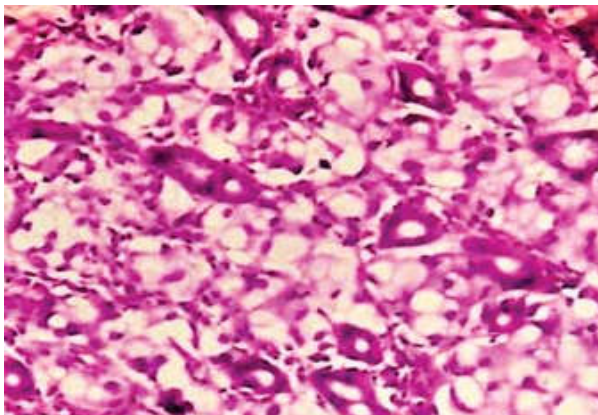


Fig. 3: Signet ring cell carcinoma (H&E x400)-Mucin filled Signet ring cells are seen to infiltrate the stroma with eccentrically placed nuclei.

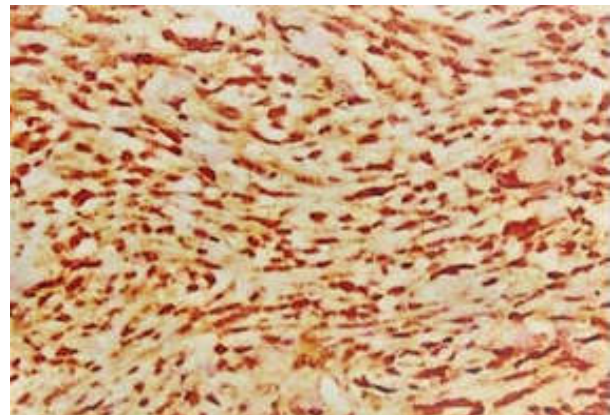


Fig. 4: Gastrointestinal stromal tumor cells showing positivity for CD117 on IHC.

(12%) in the antrum and body (Fig. 3). There was 1 case (0.8%) of papillary carcinoma involving fundus region.

Among the benign neoplastic lesions one case was an adenomatous polyp and the other one was a benign GIST (Fig. 4).

The predominant Endoscopic finding in Gastric lesions was ulcerated mucosa; followed by fungating growth was seen in 94 cases (74.0%) of the total cases. Also seen were some findings like friable, flattened mucosa, polyp or nodule.

Discussion

Endoscopy proves to be a suitable approach as the exact site of the lesion can be sampled under direct visualization. Endoscopy bits, even though very small can provide good information about the disease process. Adequate sampling is one of the most important prerequisite. Gastrointestinal lesions are one of the common causes of morbidity. Endoscopy screening may detect mucosal lesions at an early stage and measures can be taken to prevent progression of these lesions. Biopsy provides an excellent opportunity for the clinician and histopathologist to correlate, endoscopic findings and pathological features.

The spectrum of non neoplastic lesions showed majority of chronic nonspecific gastritis,³ H. pylori gastritis, acute ulceration and acute erosive gastritis which was consistent with study by Qureshi et al⁴, but the percentages were different. In the tumor-like conditions hyperplastic polyps were most common followed by Fundic gland polyp. The age and sex distribution was in accordance with study by Sandhya et al⁵ (Table 1) and Saeed et al⁶.

Table 1: Comparison of Spectrum of non neoplastic lesions in stomach.

Parameter	Sandhya et al	Saeed Afzal et al ⁶	Shaheen et al	Present Study
Acute ulceration	7/153	10/686	40/995	18/133
Chronic ulcer	-	-	-	9/133
Acute erosive gastritis	23/153	-	83/995	4/133
Chronic Gastritis	114/153	201/686	485/995	62/133
H.Pylori gastritis	7/153	475/686	391/995	8/133
Acute on chronic gastritis	-	-	-	9/133
Atrophic gastritis	-	-	-	2/133
Chronic superficial gastritis	2/153	-	-	-

Table 2: Comparison of Spectrum of neoplastic lesions in Stomach.

Parameter	Sandhya P yet al	Saeed Afzal et al	Present study
Adenocarcinoma	9/10	42/48	125/127
MALToma	1/10	-	-
GIST	-	3/48	1/127
Adenomatous polyp	-	2/48	1/127
DLBCL	-	1/48	-

In the neoplastic lesions tubular adenocarcinoma was the most common pattern accounting for 85.8%, followed by signet ring cell carcinoma, which accounts for 11.8%. This was in accordance with the study done by Saeed Afzal study⁶ (Table 2) and Wang et al⁷ which showed predominance of adenocarcinoma. These findings had similarity with L Jose et al⁸ and Byrne⁹ et al in age/sex presentation.

A study by Dilaram et al¹⁰ showed 72% cases had ulceration on endoscopy with majority of ulcers being non-neoplastic, similar to the present study. Majority of neoplastic lesions presented as fungating growth in the present study, in accordance with Olearchyket al¹¹.

Both the neoplastic and non neoplastic lesions affected mostly the antrum in 59.8% (76 of 127 cases) and 73.7% (98 of 133 cases) respectively. This was in accordance with Sandhya P et al study and Quereshi et al.

There were 48.8% of malignant cases, emphasizing the need for biopsy to be taken at the time of imaging for early detection of disease and better patient management ,which was consistent with Veena venkatesh study.¹²

Conclusion

Though the non-neoplastic lesions (51.2%) were slightly more than the neoplastic conditions, majority of neoplastic lesions showed epithelial malignancies. Adequate sampling from the lesion site can help early diagnosis hence proving the endoscopic biopsy as a useful tool in the diagnosis and further management of patient.

References

1. Edmonson J. 1991 "History of the instruments for gastrointestinal endoscopy" *Gastrointestinal endoscopy*, 37:S27-S56.
2. Histopathological spectrum of lesions of upper gastrointestinal tract: A study of endoscopic biopsies Dr. Ganga H and Dr. Indudhara PB DOI: <https://doi.org/10.33545/pathol.2018.v1.i2a.06>.

3. Shaheen A. Bhattay et al. Histopathologic spectrum of upper gastrointestinal endoscopies Medical Channel, October - December, 2009;Vol.15No.4.
4. Nafees A Qureshi, Michael T Hallissey and John W Fielding Outcome of index upper gastrointestinal endoscopy in patients presenting with dysphagia in a tertiary care hospital-A 10 years review .Birm BMC Gastroenterology 2007, 7:43.
5. Sandhya Panjeta Gulia, I Madhusudan Chaudhury. Interpretation of Upper Gastro Intestinal Tract Endoscopic Mucosal Biopsies - A Study Conducted In Teaching Hospital In Puducherry, India.J Med Health Sci. July 2012,Vol-1;Issue-3.
6. Saeed Afzal, Mumtaz Ahmad, Azhar Mubarik, et al Morphological spectrum of gastric lesions - endoscopic biopsy findings. Army Medical College, Rawalpindi, June, 2006.
7. Wang HH, Antonioli DA. Comparative features of oesophageal and gastric adenocarcinomas. Human Pathol 198;17:482-7.
8. L Jose et al A Clinicopathological Study of Carcinoma Stomach. Indian Journal of Pathology and Microbiology 38:1995:73-79.
9. J P Byrne, J M Mathers, J M Parry, Site distribution of oesophagogastric cancer J ClinPathol 2002;55: 191-194.
10. Dilaram et al Gastric carcinoma : Location, Morphological and histological profile. JPMI 2012 vol.26 No 2:170-175.
11. Olearchky A et al "Gastric carcinoma a critical review of 243 cases" Am. J. Gastroenterol, 1978, 70: 25-45.
12. Histopathological Spectrum of Lesions in Gastrointestinal Endoscopic Biopsies: A Retrospective Study in a Tertiary Care Center in India Veenaa Venkatesh * Riyana R Thaj *Department of Pathology, Karpagam Faculty of Medical Science and Research, Othakkalmandapam, Coimbatore 641032 Tamil Nadu, India.

