

## Clinico-pathological Study of Appendicectomy Specimens

VD Dafle<sup>1</sup>, Abhishek Das<sup>2</sup>, Sunil V Jagtap<sup>3</sup>, SS More<sup>4</sup>, Saswati Boral<sup>5</sup>, VA More<sup>6</sup>

<sup>1</sup>Assistant Professor, <sup>2</sup>PG Student, <sup>4</sup>Professor and Head, <sup>6</sup>Tutor, Department of Pathology, D Y Patil Medical College, Kolhapur, Maharashtra 416006, India. <sup>3</sup>Professor, <sup>5</sup>Assistant Lecturer Department of Pathology, Krishna Institute of Medical Sciences, Karad, Maharashtra 415539, India.

### Corresponding Author:

Abhishek Das, PG Student, Department of Pathology, DY Patil Medical College, Kolhapur, Maharashtra 416006, India.

E-mail: [adteenking@gmail.com](mailto:adteenking@gmail.com)

Received on 12.11.2019

Accepted on 29.01.2020

### Abstract

The appendicitis is a very common surgical emergency and for which appendicectomy is the treatment of choice. Appendicitis can cause morbidity and mortality which is related to appendicular perforation, gangrene, peritonitis, sepsis, etc. *Aims and Objectives:* To study the histomorphological features of the appendicectomy specimens and its clinical correlation. *Materials and Methods:* This is prospective, observational type of study. The total 270 specimens of appendicectomy received at pathology department of our tertiary care hospital were studied over a period of 2 years from 1/1/2016 to 31/12/2017. *Results:* Total of 270 appendicectomy specimens were studied. The common gross findings in appendicectomy specimens were inflamed appendix, other were perforation, obliteration gangrene. Among these 98.51% were involved by non-neoplastic lesions and 1.49% by neoplastic lesions. Non-neoplastic lesions were acute appendicitis 219 cases (81.19%), chronic appendicitis 29 cases (10.74%), perforation in 04 cases (1.49%), gangrenous in 02 cases (0.74%) etc. Neoplastic lesions includes 2 cases of low grade mucinous neoplasm and 02 cases of carcinoid tumor. *Conclusion:* The careful and systematic study of all the surgically removed appendicectomy specimens are very important. The most common histopathological finding in our study was acute appendicitis followed by chronic appendicitis. The neoplastic lesions were very low. The clinical diagnosis, relevant investigations and histopathological diagnosis are important for patients of appendicular lesions in the treatment and to reduce the morbidity and mortality.

**Keywords:** Histopathology; Appendicitis; Clinical features; Pain abdomen.

### How to cite this article:

VD Dafle, Abhishek Das, Sunil V Jagtap et al. Clinico-pathological Study of Appendicectomy Specimens. Indian J Pathol Res Pract. 2020;9(1 Part II):221-227.

### Introduction:

Appendicitis is a common acute surgical emergency all over the world.<sup>1</sup> The acute appendicitis is the most common abdominal emergency in childhood,

adolescents and young adults.<sup>2</sup> The pathological examination of appendicular specimen provides the definitive diagnosis for most resected specimen.<sup>2,3</sup>

The histopathological examination still remains the gold standard for the confirmation of

appendicitis. In the appendix not only neoplastic lesions are common it can also be the site of a variety of neoplasms and various unusual conditions. The pathological evaluation of the appendix after appendectomy is routine and can identify unexpected findings. This study is to determine the various lesions of the appendix and to find the clinicohistopathological correlation.

## Materials and Methods

The study was done at Pathology Department, Dr. DY Patil Medical College, Kolhapur Maharashtra, India. The study period was from 1/1/2016 to 31/12/2017. A period of two years. All surgically resected specimen of appendix both emergency and interval appendectomies performed were included in this study.

The study is prospective, observational type. All the relevant clinical data include patients age, gender, clinical presentation, related radiological and laboratory investigations were studied. The operative findings were noted. The specimens were fixed in 10% buffered formalin.

The gross findings are noted carefully for congestion, exudates perforation, gangrene, adhesions etc. The cut sections were looked for luminal patency, mucosal abnormalities, fecolith, blood, pus, mucus, worms etc. The sections including one transverse from middle-third, one from resection margin and one longitudinal section from the tip were studied for histopathology. The tissue sections were stain with haematoxylin and eosin stain. Special stain were done whenever required. The gross and microscopic findings were analyzed. The various histopathological diagnoses of the appendectomy specimens were done and

classified. For every case clinical findings were correlated with histopathological diagnosis.

## Results

All the detailed demographic data and histopathologic findings of patients who underwent appendectomy at our hospital were analyzed in this study. The findings were as follows. The data obtained from the study were transferred to the SPSS program (Version 16.0; SPSS) and then analyzed. The number, percentage, mean and standard deviation values were utilized for the evaluation of descriptive statistics. The interpretation of observations was done and discussed.

## Discussion

The appendicitis is one of the more common causes of acute abdominal pain. The appendicitis remains a clinical emergency despite diagnostic and therapeutic advancement in medical field. In our study total of 270 cases were studied as showed in Table 1. Out of which 145 (53.7%) were males and 125 were females (46.3%) as showed in Table 2. A male preponderance exists, with a male to female ratio of 1.16:1. The range from 11 year to 78 year. We observed maximum number of appendectomies were the age group of 20 to 29 which constitute 109 cases (40.37%). Addiss D et al. observed that appendicitis is most common between the ages of 10 and 20 years, but no age is exempt.<sup>4</sup> Appendicitis is noted only 5-1-0% of cases in the elderly population by study of Lunca S et al.<sup>5</sup> Buckius MT et al. in his study showed that in recent years, the number of cases in patients aged 30-69 has increased to 6.3%.<sup>6</sup>

**Table 1:** Agewise Distribution of Appendectomy Cases

| S. No.       | Age in years | No. of Cases | Percentage |
|--------------|--------------|--------------|------------|
| 1            | 10-19        | 67           | 24.81      |
| 2            | 20-29        | 109          | 40.37      |
| 3            | 30-39        | 48           | 17.78      |
| 4            | 40-49        | 22           | 8.15       |
| 5            | 50-59        | 16           | 5.93       |
| 6            | 60-69        | 04           | 1.48       |
| 7            | 70-79        | 04           | 1.48       |
| <b>Total</b> |              | 270          | 100.00     |

**Table 2:** Genderwise Distribution of Appendectomy Cases

| Gender       | No. of Cases | Percentage |
|--------------|--------------|------------|
| Male         | 145          | 53.7       |
| Female       | 125          | 46.3       |
| <b>Total</b> | 270          | 100.00     |

The etiological factors are mostly obstruction of lumen of appendix by fecolith, calculi, worms, foreign body, tumor etc. On clinical findings the triad of right lower abdominal pain and tenderness, fever and leukocytosis is present in not most of the patients. Others are loss of appetite, constipation, nausea, vomiting, diarrhea, inability to pass gas etc.

The most common symptom noted in our study was generalized pain in abdomen (87.4%)

followed by right iliac fossa pain and fever while incidental finding in 0.37% as showed in (Table 3). For acute appendicitis differential diagnoses include, acute gastro-enteritis, biliary colic, cystic fibrosis deciduosis, diverticular disease, acute intestinal obstruction, intussusception, perforated peptic ulcer, renal calculi, pelvic inflammatory disease, ectopic pregnancy, acute mesenteric adenitis etc.

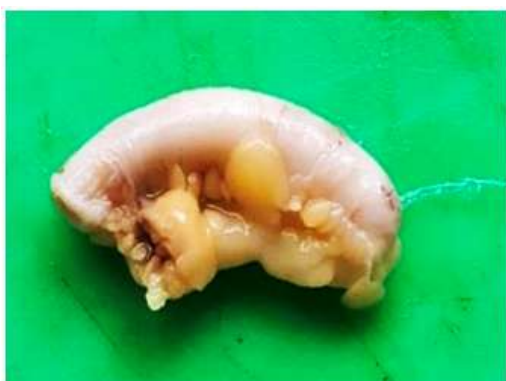**Table 3:** Clinical Presentation of Appendicectomy Cases

| Sr. No.      | Clinical Presentation      | No. of Cases | Percentage    |
|--------------|----------------------------|--------------|---------------|
| 1            | Generalised Abdominal Pain | 231          | 85.55         |
| 2            | Pain in Right ILLIAC Fossa | 34           | 12.59         |
| 3            | Constipation               | 02           | 0.74          |
| 4            | Vomiting                   | 02           | 0.74          |
| 5            | Incidental                 | 01           | 0.37          |
| <b>Total</b> |                            | <b>270</b>   | <b>100.00</b> |

On histopathological diagnosis acute appendicitis (Fig. 1) was noted in most of cases (81.11%). Followed by chronic appendicitis in 10.74%, perforated in 1.49%, gangrenous in 0.74%, (Figs. 2,4) suppurative in 1.85% as showed in (Table 5). In study by Emre A et al. the histopathologic findings indicated that 94% of the appendectomy specimens were diagnosed as acute appendicitis. Shrestha R et al. observed maximum frequency of histologic diagnoses was acute appendicitis, followed by acute suppurative and gangrenous appendicitis.<sup>8</sup>

If there is delay in diagnosing appendicitis it

may lead to complications like perforation, sepsis, shock, gangrene etc. The incidence of perforation in appendicitis was noted 1.49% in our study as showed in (Table 4). Korner H et al. observed that the perforated appendicitis occurred in 19%, with higher rates in children and the elderly, irrespective of gender.<sup>9</sup> The incidence of perforation in appendicitis was noted 8.7% by Gofrit O et al.<sup>10</sup> The rate of gangrenous appendicitis was 0.74% in this study. Study by Kulkarni M et al. and Nabipour F respectively found it to be 1.53 to 8% of all cases of appendicitis.<sup>11,12</sup>



**Fig. 1:** Gross specimen of acute appendicitis.



**Fig. 2:** Gross specimen of acute appendicitis with gangrenous change.

**Table 4:** Gross Findings in Appendicectomy Specimens

| S. No. | Gross Findings in Appendicectomy Specimens | No. of Cases | Percentage |
|--------|--|--------------|------------|
| 1      | Inflamed                                   | 257          | 95.19      |
| 2      | Perforated                                 | 04           | 1.49       |

| S. No. | Gross Findings in Appendectomy Specimens | No. of Cases | Percentage |
|--------|--|--------------|------------|
| 3      | Fecolith                                 | 02           | 0.74       |
| 4      | Obliterated                              | 01           | 0.37       |
| 5      | Dilated                                  | 03           | 1.11       |
| 6      | Gangrenous                               | 02           | 0.74       |
| 7      | Normal                                   | 01           | 0.37       |
| Total  |  | 270          | 100.00     |

**Table 5:** Histopathological Findings in Appendectomy Specimens

| S. No.       | Histopathological Findings  | No. of Cases | Percentage |
|--------------|-----------------------------|--------------|------------|
| 1            | Acute Appendicitis          | 219          | 81.11      |
| 2            | Chronic Appendicitis        | 29           | 10.74      |
| 3            | Perforation                 | 04           | 1.49       |
| 4            | Gangrenous                  | 02           | 0.74       |
| 5            | Suppurative                 | 05           | 1.85       |
| 6            | Eosinophilic                | 1            | 0.37       |
| 7            | Obliterative                | 04           | 1.49       |
| 8            | Mucocele                    | 01           | 0.37       |
| 9            | Normal                      | 01           | 0.37       |
| 10           | Low Grade Mucinous Neoplasm | 02           | 0.74       |
| 11           | Carcinoid Tumor             | 02           | 0.74       |
| <b>Total</b> |                             | 270          | 100.00     |

**Table 5:** Histopathological Findings in Appendectomy Specimens

| S. No.       | Histopathological Findings  | No. of Cases | Percentage |
|--------------|-----------------------------|--------------|------------|
| 1            | Acute Appendicitis          | 219          | 81.11      |
| 2            | Chronic Appendicitis        | 29           | 10.74      |
| 3            | Perforation                 | 04           | 1.49       |
| 4            | Gangrenous                  | 02           | 0.74       |
| 5            | Suppurative                 | 05           | 1.85       |
| 6            | Eosinophilic                | 1            | 0.37       |
| 7            | Obliterative                | 04           | 1.49       |
| 8            | Mucocele                    | 01           | 0.37       |
| 9            | Normal                      | 01           | 0.37       |
| 10           | Low Grade Mucinous Neoplasm | 02           | 0.74       |
| 11           | Carcinoid Tumor             | 02           | 0.74       |
| <b>Total</b> |                             | 270          | 100.00     |

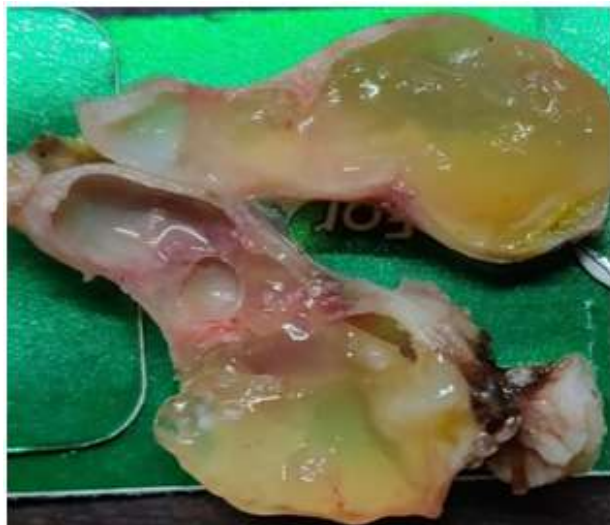Eosinophilic gastroenteritis is one of the rare conditions and its etiology is poorly understood. Diagnosis of eosinophilic enteritis requires a high index of suspicion and exclusion of various disorders that are associated with peripheral eosinophilia. Eosinophilic appendicitis requires specific criteria as described however definitive diagnosis can only be made by histopathology confirming eosinophilic infiltration of all the layers of appendix.<sup>13,14</sup>

Mucocele is a descriptive clinical term for an

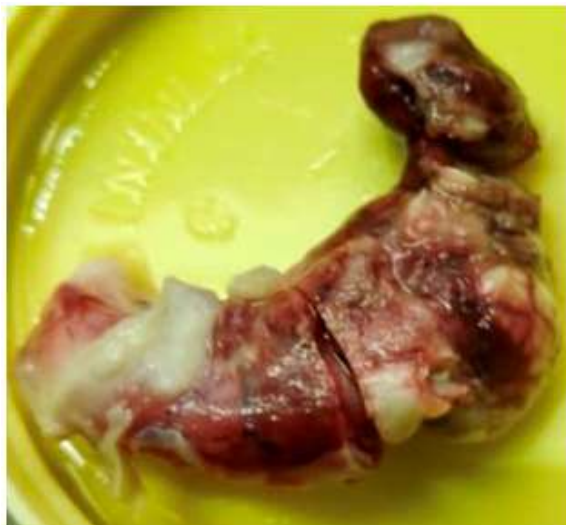abnormal mucous accumulation distending the appendicular lumen. Eosinophilic appendicitis may rarely present as mucocele due to obstructive symptoms.<sup>15,16</sup> As in our study one case of mucocele was noted. (Fig. 3) The appendiceal tumors are uncommon and most often present as appendicitis. These are mostly benign in nature and can be managed by appendectomy. The 0.9% appendiceal tumors were identified in large study by Connor SJ et al. from 7970 appendectomies.<sup>17</sup> In our study 1.49% cases showed neoplastic lesions consist

of low grade mucinous neoplasm and carcinoid tumor. The carcinoid tumors of the appendix are often asymptomatic and found incidentally during

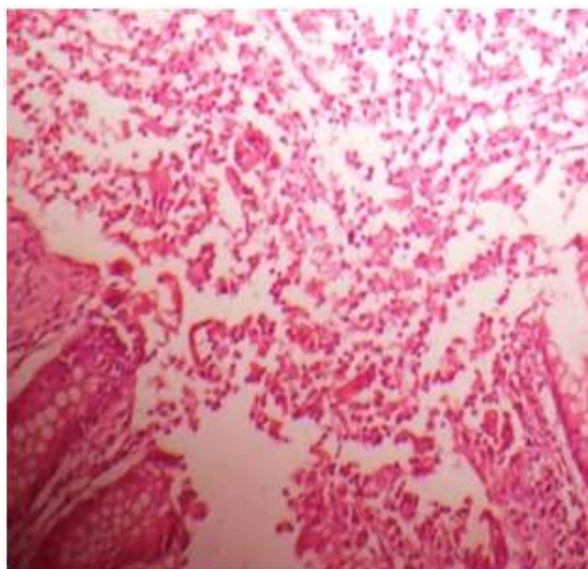
histopathological examination of appendectomy specimen. Carcinoid tumors are found in 0.3–0.9% of patients of appendectomy.



**Fig. 3:** specimen of mucocele appendix.



**Fig. 4:** specimen of appendix inflamed with gangrene and perforation.

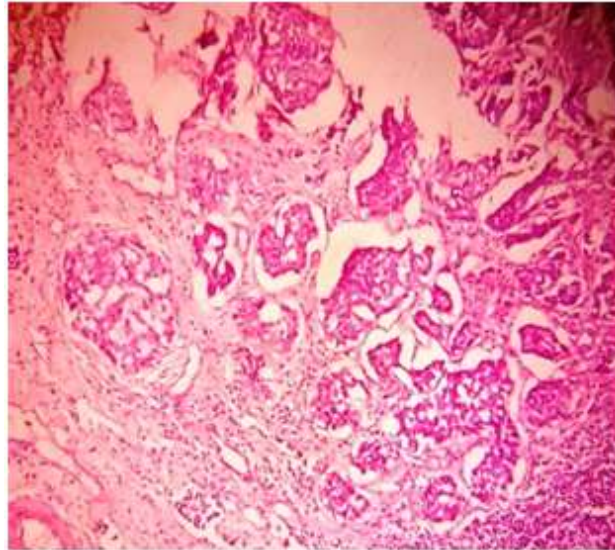


**Fig. 5:** Photomicrograph showing acute appendicitis.(H & E stain, 100x).

We have two case of carcinoid showing tumor in insular, solid islands growth pattern of uniform polygonal cells with minimal pleomorphism (Fig. 6). These tumor appear in the subepithelial neuroendocrine cells and have an indolent course. They clinically being indistinguishable from an acute appendicitis.

The negative appendectomy is term used for an operation done for suspected appendicitis, in which

the appendix is found to be normal on histological evaluation. Recently there has been a consistent decline in negative appendectomy because of better diagnostic imaging tools.<sup>19</sup> We notice one such case in this study. Appendectomy is the usual and most common treatment performed for appendicitis. The pathological examination of appendicular specimen provides the definitive diagnosis for most resection specimen and helps in patient care.



**Fig. 6:** Photomicrograph showing carcinoid tumor in insular, solid islands growth pattern of uniform polygonal cells with minimal pleomorphism. (H & E stain, 100x)

## Conclusion

The appendectomy specimens removed from patients with suspected appendicitis are important to study for its histopathological analysis to reveal definite underlying pathology. The careful and systematic study of all the surgically removed appendectomy specimens are very important. The most common histopathological finding in our study was acute appendicitis followed by chronic appendicitis. The neoplastic lesions observed were low. The clinical diagnosis, relevant investigations and histopathological diagnosis are important for patients of appendicular lesions for better care.

## References

1. Marudanayagam R, Williams GT, Rees BI: Review of the pathological results of 2660 appendectomy specimens. *J Gastro* 2006;41(8):745-9.
2. Shepherd NA, Warren BF, Williams GT (Eds). *Morson and Dawson's Gastrointestinal Pathology*. 5<sup>th</sup> edition. Wiley-Blackwell Science 2013.
3. Swank HA, Eshuis EJ, Ubbink DT, et al. Is routine histopathological examination of appendectomy specimens useful? A systematic review of the literature. *Colorectal Dis* 2011;13(11):1214-21.
4. Addiss DG, Shaffer N, Fowler BS, et al. The epidemiology of appendicitis and appendectomy in the United States. *Am J Epidemiol* 1990;132:910-25.
5. Lunca S, Bouras G, Romedea NS. Acute appendicitis in the elderly patient: Diagnostic problems, prognostic factors and out-comes. *Rom J Gastroenterol* 2004;13:299-303.
6. Buckius MT, McGrath B, Monk J, Grim R, et al. Changing epidemiology of acute appendicitis in the United States: Study period 1993-2008. *J Surg Res* 2012;175:185-90.
7. Emre A, Akbulut S, Bozdog Z, et al. Routine histopathologic examination of appendectomy specimens: Retrospective analysis of 1255 patients. *Int Surg* 2013;98:354-62.
8. Shrestha R, Ranabhat SR, Tiwari M. Histopathological analysis of appendectomy specimens. *J Pathol Nepal*. 2012;2(3):215-19.
9. Körner H, Söndena K, Söreide JA, et al. Incidence of acute nonperforated and perforated appendicitis: Age-specific and sex-specific analysis *World J Surg* 1997;21(3):313-7.
10. Gofrit ON, Abu-Dalu K. Perforated appendicitis in the child: Contemporary experience *Isr Med Assoc J* 2001;3(4):262-5.
11. Kulkarni MP, Sulhyan KR, Barodawala SM et al. Histopathological study of lesions of the appendix. *Int J Health Sci Res* 2017;7(4):90-95.
12. Nabipour F. Histopathological Features of Acute Appendicitis in Kerman-Iran from 1997-2003. *Am J EnvSci* 2005;1:130-32.
13. Jagtap Sunil V, Nikumbh D, Kshirsagar A. Unusual presentation of eosinophilic enteritis as multiple strictures of small intestine. *ClinPract* 2012 Jan 1; 2(1):e24.
14. Kshirsagar AY, Jagtap SV, Kanojiya RP, et al. Eosinophilic enteritis presenting as a rare cause for ileo-ileal intussusception. *World J Gastroenterol* 2007;13:6444-45.
15. Federle MP, Anne VS. Mucocoele of the appendix. In:

- Federle MP, editor. Diagnostic Imaging: Abdomen. Salt Lake City, UT: Amirsys 2004. pp.26-27.
16. Jagtap SV, Nikumbh DB, et al. Eosinophilic appendicitis presented as mucocele: A rare clinical entity. International Journal of Health Sciences & Research- IJHSR 2012;2(2):99-103.
  17. Connor SJ, Hanna GB, Frizelle FA. Appendiceal tumors: retrospective clinicopathologic analysis of appendiceal tumors from 970 appendectomies. Dis Colon Rectum. 1998;41(1):75-80.
  18. Goede AC, Caplin ME, Winslet MC. Carcinoid tumour of the appendix. Br J Surg 2003;90:1317-1322.
  19. Seetahal SA, Bolorunduro OB, Sookdeo TC, et al. Negative appendectomy: A 10-year review of a nationally representative sample. The American Journal of Surgery 2011;1;201(4):433-37.

