

## Management of Recurrent Horseshoe Fistula-in-ano by Ksharasutra

TS Dudhamal, Shailley Maurya

**Author Affiliation:** <sup>1</sup>Associate Professor, and HOD, <sup>2</sup>Postgraduate Student, Department of Shalya Tantra Institute of Teaching and Research in Ayurveda(INI), Jamnagar 361008, Gujarat, India.

**Corresponding Author: Shailley Maurya**, Postgraduate Student, Department of Shalya Tantra Institute of Teaching and Research in Ayurveda(INI), Jamnagar 361008, Gujarat, India

**E-mail:** shaillymaurya09@gmail.com

### Abstract

Horseshoe fistula-in-ano is a challenging problem for the proctologist due to the sepsis of the posterior anal space. There is a high chance of recurrence along with potential incontinence following surgery. To address such a grievous outcome after surgery, Ksharasutra threading was found to be beneficial in such a case. Ksharasutra not only helped in draining the fistulous tract but, it also maintained the integrity of the sphincter by simultaneously cutting and promoting fibrosis thereby resulting in maintenance of continence and was effective in draining the post anal sepsis resulting in no recurrence of the disease.

**Keywords:** Bhagandara; Horseshoe fistula-in-ano; Ksharasutra; Medicated seton.

### How to cite this article:

TS Dudhamal, Shailley Maurya/Management of Recurrent Horseshoe Fistula-in-ano by Ksharasutra. Indian J Ancien Med Yog. 2021;14(1): 29-33

### Introduction

Horseshoe fistula-in-ano is an aggressive form of anorectal fistula due to its circumferential spread of the sepsis which results in one or several secondary openings. This spread is in the deep postanal space and then to the ischio-rectal spaces. Therefore, a typical horseshoe fistula is composed of bilateral external openings joined by a deep postanal communication in the posterior midline, resulting in a U or horseshoe-shaped configuration.<sup>1</sup>

Ksharasutra (Ayurvedic medicated seton) is being used in India by many colorectal surgeons to treat complex and high anal fistula-in-ano. The same principle is also adopted by Japan and prepared the Kanazawa Sutra which is practiced in Fistula-in-ano by surgeons.<sup>2</sup> The scientific validation of Ksharasutra was done by the Indian Council of Medical Research (ICMR) based on a multicentric clinical research trial. The trial concluded that Ksharasutra is better than conventional surgery in fistula-in-ano in terms of early recovery,

minimal invasiveness, day-care surgery, and cost-effectiveness.<sup>3</sup> Previous studies also reported that complex fistula i.e. recurrent fistula, high anal fistula, multiple tract fistulae, horseshoe fistula can be as well managed through Ksharasutra.<sup>4</sup>

### Case History

A 60-year-old male was admitted to the hospital with complaints of recurrent boils in the perianal region for 1 year. He also had associated complaint of fever during the collection of pus followed by its remission upon spontaneous bursting of an abscess. He had a past surgical history of incision and drainage of perianal boil in 2001 and 2015. He had no history of major systemic illness. On examination, there were external openings at 10 o'clock, 7 o'clock and two openings at 4 o'clock. On digital rectal examination, a single internal opening was palpated at 6 o'clock and clinically was diagnosed as horseshoe fistula-in-ano. To confirm the diagnosis and extent of the tract,

TRUS(Trans-rectal ultrasonography) was advised. The findings of the TRUS report read as, "11 to 12 cm horseshoe-shaped branching fistula, seen in the perianal region with one external opening at 10 o'clock position, another at 7 o'clock position, another two external opening at 4 o'clock position and one internal opening at 6 o'clock position. The maximum depth of the fistula at 6 o'clock position is 9 mm. Internal opening is 10mm proximal to the anal verge". The patient was briefed about the procedure and written informed consent was taken. Preoperatively, intra-venous crystalloids and antibiotics were administered. Surgery was performed under spinal anesthesia.

The primary opening was confirmed by injecting methylene blue dye from the external opening which came out from the internal opening at 6 o'clock. Retrograde probing was done from the internal opening at 6 o'clock and a window was created at the inter-sphincteric plane posteriorly followed by Ksharasutra threading for drainage of the primary crypt. Then, the probe was inserted from the external opening at 4 o'clock and the whole tract was excised along with its ramification using coring technique up to the midline posteriorly.

Similarly, probing was done from 10 o'clock and partial fistulectomy was performed. Ksharasutra threading was done from 8 to 6 o'clock. The

postoperative course was uneventful. From the first post-operative day, a sitz bath with Panchvalkal decoction was advised twice a day. The daily aseptic dressing was done with Jatyadi Taila. Ksharasutra was changed every week by rail-road technique until complete cutting of the fistulous tract.

## Result

The weekly assessment was done on postoperative pain, discharge from the wound, and perianal itching. The right external fistulous tract (8 to 6 o'clock) got cut through on the 43rd post-operative day. The Ksharasutra at 6 to 6 o'clock was kept loose after changing to provide adequate drainage until the external tract was cut through completely. Thereafter, the Ksharasutra was tightened up after each sitting. This fistulous tract got cut through on the 55th post-operative day. The wound was completely healed on the 68th post-operative day. (clinical images fig 1-6) Thereafter, the patient was called for follow up on every 15th day for two months and then, monthly follow up was taken for 8 months. During the follow-up period, the patient had no complaints of pain, discharge and itching in the perineal region neither did he encounter incontinence or sphincter dysfunction.

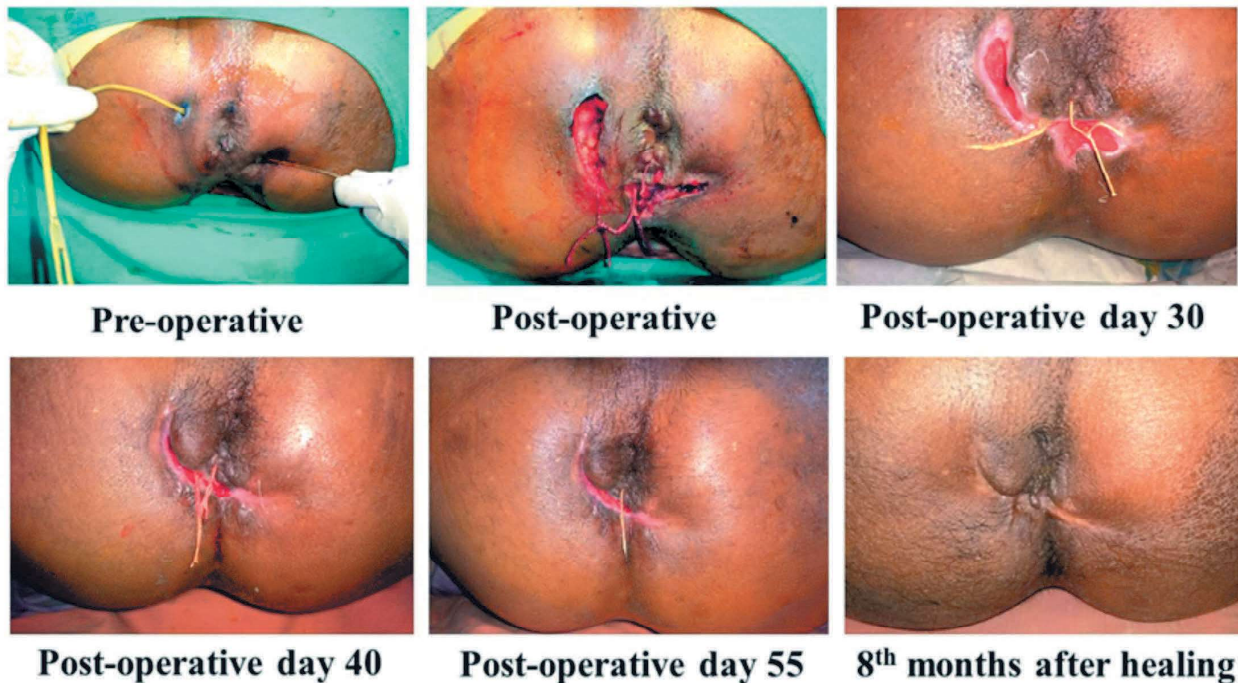


Fig 1-6: Clinical Images

## Discussion:

The widely practiced surgical technique for the treatment of horseshoe type of fistula is Hanley's procedure,<sup>5-6</sup> use of cutting seton along with Hanley's procedure,<sup>7-8</sup> and modified Hanley's procedure.<sup>9</sup> It is of utmost importance that there should be adequate drainage of the retro-anal region to cure a posterior horseshoe fistula. Hence, to address this, Ksharasutreading was done from 6 to 6 o'clock. Ksharasutra is a medicated thread that is alkaline thereby possesses the action of chemical cauterization of the tissue.<sup>10</sup> Subsequently, tightening of the thread after each sitting cause mechanical pressure which results in the cutting of the tract. Latex of Euphorbia neriifolia used during the coating of Ksharasutra is reported to have wound healing activity.<sup>11</sup> The thread also has a coating of Cucurcuma longata, has anti-inflammatory and anti-microbial properties.<sup>12-14</sup> Panchvalkal decoction sitz bath helped to clean the pus discharge and associated debris from the tract and promoted drainage of pus from the tract. It also helps to reduce local congestion and inflammation and thus, relieves associated pain by enhancing local circulation which is necessary to promote healing.<sup>15-16</sup> Jatyadi Taila has Vatashamakand Vranaropaka (wound healing) properties thus, it not only reduces pain but also lubricates the anal canal preventing constipation, eases the passage of stool and promotes wound healing.<sup>17</sup> Though, it took a longer period for complete healing, the main advantage of this procedure was that the patient was ambulatory during the whole course of treatment and eventually returned to work in 10 days following surgery. The right ramification of the tract was also threaded to have the minimal division of external sphincters, to provide adequate drainage and to chemically cauterize the tract, thereby cleaning the unhealthy granulation tissue of the tract. Ksharasutra not only helps to prevent recurrence but also maintains the integrity of the sphincters by cutting and fibrosing the muscles.<sup>18</sup> This is an important aspect of Ksharasutra as conventional surgeries lead to larger wounds and an abundant division of sphincters causing incontinence. Thus, there is a minimum or absence of incontinence to the patient and the quality of life is not hampered.

*Conflicts of interest:* There are no conflicts of interest.

*Acknowledgement:* The authors convey their gratitude to Prof. Anup B. Thakar, Director of

Institute of Teaching and Research in Ayurveda, Jamnagar for their kind support and assistance during the study.

## Conclusion:

The case study concluded that recurrent horseshoe fistula can be well treated with Ksharasutra without recurrence.

## References

1. Inceoglu R, Gencosmanoglu R. Fistulotomy and drainage of deep postanal space abscess in the treatment of posterior horseshoe fistula. *BMC Surgery*. 2003; 3:10
2. Yoshimitsu M., Mikage M., Nakagawa Y., Yamamoto K., Tazawa K. Preparation of Kshara Sutra in Japan. *J. Trad. Medicine*. 2005; 22: 15-18.
3. Shukla NK, Narang R, Nair NG, Radhakrishna S, Satyavati GV. Multicentric Randomized controlled clinical trial of Ksharasutra (Ayurvedic Medicated thread) in the management of Fistula in ano. *Indian Journal of Medical Research* 1991; 94: 177-85.
4. Shreshtha M, Dudhamal T.S. Management of recurrent, complex, and high anal horseshoe fistula-in-ano by partial fistulectomy with Ksharasutra: a case report. *European Journal of Medical Case Reports*. 2018; 2(3):117-120.
5. Hanley PH. Conservative surgical correction of horseshoe abscess and fistula. *Dis Colon Rectum* 1965; 85: 364-368
6. Hanley PH, Ray JE, Pennington EE, Grablowsky OM. Fistula-in-ano: a ten-year follow-up study of horseshoe-abscess fistula-in-ano. *Dis Colon Rectum* 1976; 19: 507-515
7. Browder LK, Sweet S, Kaiser AM. Modified Hanley procedure for management of complex horseshoe fistulae. *Tech Coloproctol*. 2009; 13: 301-306
8. Ustynoski K, Rosen L, Stasik J, Riether R, Sheets J, Khubchandani IT. Horseshoe abscess fistula: seton treatment. *Dis Colon Rectum*. 1990; 33:602-605
9. Leventoglu S, Ege B, Menten BB, Yorubulut M, Soydan S, Aytac B. Treatment for horseshoe fistula with the modified Hanley procedure using a hybrid seton: results of 21 cases. *Tech Coloproctol* 2013; 17:411-417
10. Raut Subhash, Kedar Nita, Akulwar Akanksha. Effectiveness of Ksharasutra Ligation Followed by Fistulectomy in the Management of Bhagandara (Fistula InAno). *International Journal of Ayurveda and Pharma Research*. 2017;5(1):1-5.

11. Rasik A.M, Shukla A, Patnaik B.N, Dhawan D.K, Srivastava K.S. Wound healing activity of latex of *Euphorbia neriifolia*. Indian Journal of Pharmacology. 1996; 28: 107-109
12. Arora R.B, Basu N, Kapoor V, Jain A.P. Anti-inflammatory studies on *Curcuma longa* (Turmeric). Indian J. Med. Res. 1971; 59: 1289-1295
13. Banerjee A, Nigam S.S. Antimicrobial efficacy of the essential oil of *Curcuma longa*. Indian J. Med. Res. 1978; 68: 864-866
14. Lutomski J, Kedzia B, Debska W. Effect of an alcohol extract and of active ingredients from *Curcuma longa* on bacteria and fungi. Planta Med. 1974; 26: 9-19
15. Bhat KS, Vishwesh BN, Sahu M, Shukla VK. A clinical study on the efficacy of Panchavalkala cream in VranaShodhanaw.s.r to its action on microbial load and wound infection, Ayu. 2014; 35(2): 135-40.
16. Dhurve VA, Dudhamal TS. Formulations of PanchavalkalaAs VranaShodhana and VranaRopana:A Brief Review. Indian J Ancient Med Yog. 2020;13(1):17-22.
17. Kulkarni YS, Shashidhar V. Emmi, Tajahmed N. Dongargaon, Amruta A. Wali. Wound healing effect of Vimlapana karma with Jatyaditailam in diabetic foot. Ancient Science of Life. 2015; 34(3):171-74.
18. Nema A, Gupta SK, Dudhamal TS, Mahanta V. Transrectal Ultra Sonography based evidence of Ksharasutra therapy for Fistula-in-ano- A case series. Journal of Ayurveda and Integrative Medicine. 2017;8: 113-121.

