

Axillary Approach Versus Infraclavicular Approach In Ultrasound-Guided Brachial Plexus Block: A Comparative Study

TC Balaraju¹, Patil Vishalakshi², Kondikar Lohit³, Naik Harish S⁴

¹Professor, ²Associate Professor, ³Assistant Professor, ⁴Postgraduate 3rd Year, Department of Anesthesiology and Critical Care, Navodaya Medical College, Hospital and Research Centre, Raichur, Karnataka 584103, India.

Abstract

Background: Brachial plexus block (BPB) is a well accepted technique to provide anaesthesia and analgesia for upper limb surgeries. Usage of ultrasound (USG) guided BPB technique has overcome the disadvantages caused by traditional landmark technique. **Objective:** To determine the block performance time, onset time, success rate, and any complications with the USG guided technique in both Axillary and Infraclavicular BPB. **Methods:** For an ultrasound guided brachial plexus block 80 patients undergoing elective upper limb surgeries were randomly allocated into 2 groups group AX (axillary), Group IC (infraclavicular) to receive Ropivacaine 0.75% 25 ml. Block performance time, onset and duration of sensory and motor block and success rate were assessed. **Results:** The mean block performance time of Group IC (6.43 ± 0.38) was significantly shorter compared to Group AX (8.46 ± 0.43). The mean onset time of sensory block (5.33 ± 1.67 vs 7.03 ± 2.01) and motor block (9.23 ± 3.01 vs 17.53 ± 4.10) were significantly faster in Group IC compared to Group AX. Duration of sensory block (290.38 ± 78.65 vs 295.25 ± 35.86) and motor block (356 ± 97.99 vs 357.8 ± 108.13). Success rate was (95%) in group IC and (85%) in group AX. **Conclusion:** Ultrasound guided BPB through infraclavicular approach has shorter performance time, higher success rate and faster onset of sensory and motor block when compared to axillary approach. There was no statistically significant difference in duration of sensory and motor block in both approaches.

Keywords: Brachial plexus Block, Ropivacaine, Ultrasound.

How to cite this article:

TC Balaraju, Patil Vishalakshi, Kondikar Lohit, et al. Axillary Approach Versus Infraclavicular Approach In Ultrasound-Guided Brachial Plexus Block: A Comparative Study. Indian J Anesth Analg. 2020;7(3):720-725.

Introduction

Brachial plexus block (BPB) is a well accepted technique to provide anaesthesia and analgesia for upper limb orthopaedic surgeries¹. Brachial plexus block through traditional nerve localization techniques rely on surface anatomical landmarks, patients' perception of paresthesia or by elicitation of motor twitch by electrical stimulation has got

some disadvantages like inconsistent block success, inadvertent arterial puncture, pneumothorax, nerve injury.

These disadvantages can be overcome by using ultrasound (USG) guided brachial plexus block where there will be real time visualization of nerves and surrounding anatomy, continual observation of the needle tip and spread of local anaesthetic^{2,3,4}.

Corresponding Author: Vishalakshi Patil, Associate Professor, Department of Anesthesiology and Critical Care, Navodaya Medical College, Hospital and Research Centre, Raichur, Karnataka 584103, India.

E-mail: : drvishalakshi_patil@yahoo.co.in

Received on 24.01.2020, **Accepted on** 29.02.2020

Many researchers have compared the ultrasound-guided technique to the nerve stimulator guided technique, but there are not many comparative studies between the various methods for ultrasound-guided nerve blocks so we wanted to compare ultrasound guided infraclavicular block with ultrasound guided axillary block to assess success rate, performance time, onset and duration of sensory and motor blockade and complications if any.

Materials and Methods

After Institutional ethical committee approval and written informed consent, 80 patients between the age group 18-60 years, ASA physical status I and II who were scheduled to undergo elective forearm and hand surgeries in Navodaya Medical College, Hospital And Research Centre were included in the study.

Patients with chest deformity, clavicle fracture, patients with parasthesia and paresis in operating upper limb, patients with coagulopathy, local infection in the area of the block and patients allergic to local anaesthetics, pregnant women or morbid obese patients were excluded from the study.

All patients were randomized by computer generated random number table into two groups: group AX (ultrasound guided Axillary brachial plexus block) and group IC (ultrasound guided Infraclavicular brachial plexus block). All the patients were premedicated with oral tab Alprazolam 0.5mg 30 mins before shifting to the operation theatre. After shifting the patients to the operation theatre, vital signs were monitored by non invasive blood pressure monitoring, pulse oximeter, and electrocardiogram. All the blocks were performed by an anaesthesiologist with minimum experience of 10 ultrasound guided brachial plexus blocks under the supervision of an experienced anaesthesiologist. A standardized local anaesthetic solution of Ropivacaine 0.75 % 25 ml was injected to all the study patients, the anaesthesiologist who performed block was not involved in further monitoring of the patient.

Patients in group AX were made to lie down in the supine position with the arm to be blocked externally rotated more than 90 degrees and the elbow flexed to expose the axillary area. Skin over the axillary area was painted with betadine and all further procedures were done under aseptic technique. Under the guidance of ultrasound (LOGIQ C5 Premium/ GE) a 7.5 to 10 MHz linear probe was positioned in the axillary crease

perpendicular to the axillary artery to visualize axillary artery and surrounding structures. Axillary artery was confirmed by pulsatile motion and with color Doppler image. Once the axillary artery is identified, radial nerve (5-6'o clock position to the artery), median nerve (9-11'o clock position to the artery), and ulnar nerve (2'o clock position to the artery) were located and after local infiltration of the skin, injection Ropivacaine 0.75% 7ml each was given perineurally by using in-plane technique with 22 G 50mm insulated needle (stimuplex^R B/ BRAUN / JAPAN). Then musculocutaneous nerve was identified as a triangular bright echogenic structure between biceps and coracobrachialis muscles and using in-plane technique remaining 4ml injection Ropivacaine 0.75% was given perineurally.

Patients in group IC were placed in supine position with arms at the sides and head slightly rotated to contralateral side of the blocking arm. Skin over the infraclavicular area was painted with betadine and all further procedures were done under aseptic technique. Under the guidance of ultrasound (LOGIQ C5 Premium/ GE) a 7.5 to 10 MHz linear probe was positioned in infraclavicular fossa, axillary artery was located and confirmed by using color Doppler after local infiltration of the skin, by using in plane technique a 21 G 100mm insulated needle (stimuplex^R B/ BRAUN / JAPAN) was inserted above the ultrasound probe and the needle was advanced until the tip was located just posterior to axillary artery. 2ml of injection Ropivacaine 0.75% was injected to visualize hypoechoic bubbles i.e. double bubble sign after that remaining 23 ml was injected.

After completion of the block, the onset of sensory and motor blockade was assessed every 2 min for the first ten minutes, followed by every 5 minutes for the next 20 minutes using pin prick method and Bromage scale respectively. Successful block was defined as complete surgical anaesthesia. Complete surgical anaesthesia is defined as the ability to proceed with surgery without the need for intravenous narcotics or general anaesthesia or even local infiltration by the surgeon. If one or more nerve was spared it was considered as incomplete block and then a rescue block of the concerned nerves at appropriate level was given. If there is no onset of nerve block even after 30minutes post block performance it was considered as failed block. Sensory score was assessed by testing the dermatomes supplied by following nerves by pin prick method using 25g needle

1. Radial nerve - dorsum of hand over 2nd

metacarpophalangeal joint

2. Median nerve – thenar eminence
3. Ulnar nerve – little finger
4. Musculocutaneous nerve – lateral side of forearm
5. Medial cutaneous nerve of forearm – medial side of forearm

Scoring system was taken from KoscielniakNielsen et al for checking sensory block.

(0 – sharp pain, 1 – touch sensation only and 2 – no sensation).

Motor block was evaluated by testing following responses

1. Radial nerve -thumb abduction
2. Median nerve – third finger flexion
3. Ulnar nerve – little finger flexion
4. Musculocutaneous nerve – elbow flexion

Bromage scale used to assess motor block.

- Normal motor function (no effect- 0)
- Decrease motor strength compared to contralateral limb -1
- Complete motor block-2

Intraoperatively patients were monitored for pulse rate, blood pressure, electrocardiogram, spo2 and for complications if any. Block performance time, onset and duration of sensory and motor block, quality of block, success rate and complications such as haematoma, haemorrhage, pneumothorax, and accidental intravascular injections were observed.

Block performance time was defined as the time interval from placement of ultrasound probe to the removal of needle after injection of local anaesthetic. Successful block was defined as complete surgical anaesthesia. Incomplete block was defined as sparing of one or more nerves.

Onset of sensory block was described as the time period between injection of drug and complete loss of pinprick sensation.

Onset of motor block was defined as the time elapsed from injection of drug to complete motor block. Failed block was determined when there is no onset of nerve block 30 minutes after the procedure. Rescue analgesia time When VAS Score is 4 or more. Duration of sensory block was defined as the time interval between the brachial plexus block and the first dose of rescue analgesia. Duration of motor block was defined as the time interval between brachial plexus block and the recovery of one of these movements: thumb

abduction, 3rd finger flexion, little finger flexion, elbow flexion.

Statistical Characteristics

We hypothesized that infraclavicular block would have faster block performance time compared to axillary block. For study to have 91% power and alpha error at 0.05 a minimum of 40 patients would be required in each group to detect a 9% difference in block time, assuming a standard deviation 1.5. Hence we enrolled 40 patients in each group to compensate for possible dropouts.

Data were entered in MS-Excel programme (2007) and were analyzed with IBM Statistical Package For Social Sciences (SPSS) version twenty two.

Descriptive statistics including proportions, measures of central tendency and measures of dispersion were used to describe the data. Further, student's t –test was used to compare proportions. A *p*- value of <0.05 was considered to be statistically significant.

Results

The demographic profile was analyzed and distribution of the age, sex, and weight of the patients in both the groups was compared, results were comparable. In our study mean performance time was shorter in group IC (06.43 ± 0.38) compared to group AX (08.46 ± 0.43). The onset of sensory block was faster in group IC (05.33 ± 1.67) compared to group AX (07.03 ± 2.01). The onset of motor block was faster in group IC (09.23 ± 3.01) compared to group AX (17.53 ± 4.10) 2 (5%) patients had incomplete block in group IC and 6 (15%) patients had incomplete block in group AX. So the success rate was (95%) in group IC and (85%) in group AX. There were no failed blocks. The duration of sensory block in group IC (290.38 ± 78.65) and group AX (295.25 ± 35.86) was comparable. The duration of motor block in group IC was (356 ± 97.99) comparable to group AX (357.8 ± 108.13) and 2 (5%) patients in each group had inadvertent vascular puncture (Table 1, 2 and Figs. 1-3).

Table 1: Demographic data

Demographic data	Group IC	Group AX	<i>p</i> - Value
Age (years)	33.7 + 8.10	36.95 + 8.00	0.0748
Weight (kg)	58.83 + 5.91	57.48 + 3.90	0.231
Height (cms)	157.2 + 5.42	157.1 + 4.73	0.895
Sex (Male/Female)	23/17	21/19	0.822
ASA PS (I/II)	28/12	29/11	0.999

Table 2: Anaesthetic data

Anaesthetic data	GROUP IC	GROUP AX	p - value
Block Performance Time (Min)	6.43 + 0.38	8.46 + 0.43	< 0.001
Onset of Sensory Block (Min)	5.33 + 1.67	7.03 + 2.01	< 0.001
Onset of Motor Block (Min)	9.23 + 3.01	17.53 + 4.1	< 0.001
Duration of Sensory Block (Min)	290.38 + 78.65	295.25 + 35.86	0.722
Duration of Motor Block (Min)	356 + 97.99	357.8 + 108.13	0.913
Success Rate (%)	95%	85%	
Incomplete Block	2/40	6/40	0.263

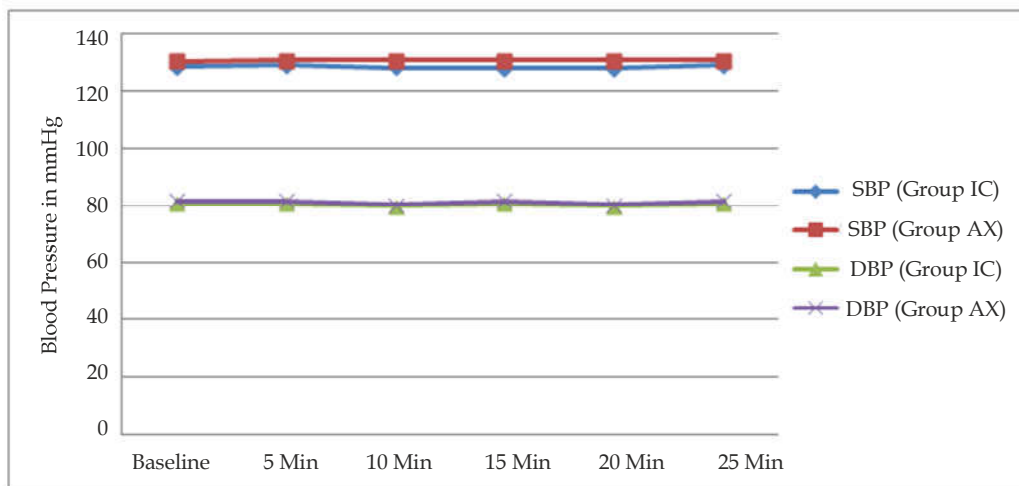


Fig.1: Blood pressure changes during surgery

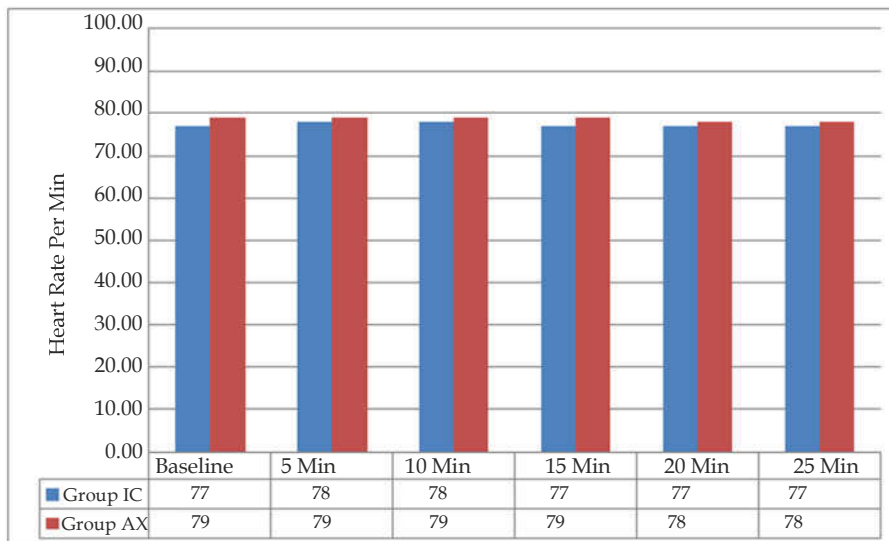


Fig. 2: Heart rate changes during surgery

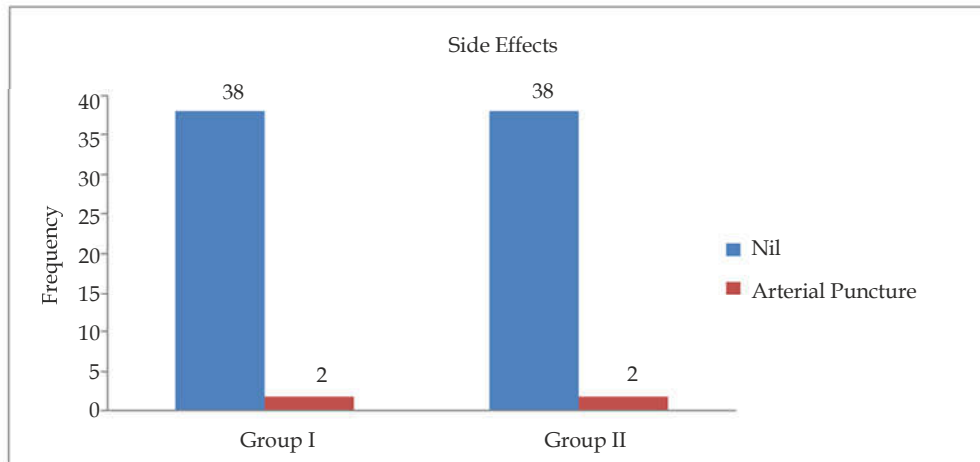


Fig. 3: Side effects

Discussion

Forearm surgeries can be performed under brachial plexus block through supraclavicular approach, infraclavicular approach and axillary approach⁶. Usually anaesthesiologists have an inclination towards supraclavicular or axillary approach over infraclavicular approach because of technical difficulty and chances of increased complication rate in blind infraclavicular approach. With increased use of ultrasonography the complications associated with infraclavicular approach have been reduced because of direct visualization of nerve structures, needle tip and spread of the drug,⁷ so we wanted to compare ultrasound guided infraclavicular approach versus axillary approach. In our study block performance time was shorter in group IC when compared to group AX, this difference was because the additional minutes required for axillary block, may be because the needle was targeted at 3 nerves around the axillary artery and one for the musculocutaneous nerve where as drug was deposited at only one point in infraclavicular block. This was consistent with the results of previous study by In Ae song et al.⁸

We have defined block performance time as the time interval from placement of ultrasound probe to the removal of needle after injection of local anaesthetic.⁹ Whereas In Ae song et al., have defined performance time as from the time betadine was applied onto the skin to the removal of the block needle. Other studies have measured it differently from needle to needle^{10,11,12} as ultrasonographic identifying of nerve plexus and surrounding structures will take some time before performing block, this is more practical way of inducing block.

Onset of sensory block in Infraclavicular Group is (5.33 ± 1.67) and in Axillary Group is (7.03 ± 2.01)

Onset of motor block in group IC (9.23 ± 3.01) and in group AX (17.53 ± 4.1) this earlier onset of sensory and motor block in group IC might be because of infiltration of local anaesthetic solution more proximal to nerves and relative late onset in group AX might be because of infiltration of local anaesthetic solution periphery to nerves.

Duration of sensory and motor block in each study groups was comparable and statistically not different. Duration of sensory block in group IC (290.38 ± 78.65) and in group AX (295.25 ± 35.86). Duration of motor block in group IC (356 ± 97.99) and in group AX (357.8 ± 108.13)

The success rate in our study was ninety five percent with infraclavicular group and eighty five percent in axillary group. Five percent in infraclavicular and fifteen percent in axillary group had incomplete block.

This high success rate for infraclavicular block in our study mirrors findings of previous studies¹³. A success rate of 90-95% for ultrasound guided infraclavicular block was quoted in few studies.^{14,7} A success rate of 97.5% for ultrasound guided axillary block was quoted in study conducted by Rania Maher Hussien et al⁵ and a success rate of 95-100% for ultrasound guided axillary block was quoted by Vincent et al.¹⁵ which was in contrast to the findings of our study (85%). This high success rate in infraclavicular block may be because of use of ultrasound in brachial plexus block not only identifies the anatomical structures but also allows complete identification of the needle passage till local anaesthetic was injected.

The comparatively lower success rate in axillary block is also attributable to relative lack of experience of the anaesthesiology residents and potential variable anatomical position in relevance the axillary artery.¹³

Complications

In each group there were 2 cases of vascular puncture which could be attributed to relative inexperience of the anaesthesiology residents performing the block.

Limitations

Even though the block performer did not participate in further monitoring of the patients, evaluation of study parameters begun immediately after the block and it was not possible to completely remove traces like betadine or the puncture site on the skin for the particular block which could indicate the group to which patient belongs. This could result in bias in recording results and hence we could not conduct a completely blinded study.

We failed to follow up the patients for one week to identify for neurological deficits.

Conclusion

Ultrasound guided brachial plexus block through infraclavicular approach has shorter performance time, higher success rate and faster onset of sensory and motor block when compared to ultrasound guided brachial plexus block through axillary approach. There was no statistically significant difference in duration of sensory and motor block in both approaches.

References

1. Chatrath V, Sharan R, Kheterpal R, Kaur G, Ahuja J, Attri JP. Comparative evaluation of 0.75% ropivacaine with clonidine and 0.5% bupivacaine with clonidine in infraclavicular brachial plexus block. *Anesth Essays Res* 2015;9:189-94.
2. Kapral S, Greher M, Huber G, et al. Ultrasonographic Guidance Improves the Success Rate of Interscalene Brachial Plexus Blockade. *Regional Anesthesia and Pain Medicine* 2008 May-Jun;33(3): 253-258.
3. Marhofer P, Greher M and Kapral S. Ultrasound guidance in regional anaesthesia *Br J Anaesth* 2005; 94:7-17.
4. Liu FC, Liou JT, Tsai YP, et al. Efficacy of Ultrasound-Guided Axillary Brachial Plexus Block: A Comparative Study with Nerve Stimulator-Guided Method. *Chang Gung Med J.* 2005 Jun;28(6):396-402.
5. Hussien RM, Ibrahim DA. Ultrasound Guided Axillary Brachial Plexus Block Versus Supraclavicular Block In Emergency Crushed Hand Patients : A Comparative Study Department of Anesthesia and ICU, Ain Shams University, Cairo, Egypt. *The Open Anesthesia Journal* 2018;12.
6. Padmini, Sevagamoorthy, Rajaprabhu. A prospective randomized comparison between perivascular and perineural ultrasound guided axillary brachial plexus block for upper limb surgeries. *Indian Journal of Clinical Anaesthesia* 2018;5(4):512-517.
7. Ootaki C, Hayashi H, and Amanos M. Ultrasound-Guided Infraclavicular Brachial Plexus Block: An Alternative Technique to Anatomical Landmark-Guided Approaches. *Regional Anesthesia and Pain Medicine* 2000;25(6):600-604.
8. Song AI, Gil N, Choi E, et al. Axillary approach versus the infraclavicular approach in ultrasound-guided brachial plexus block: comparison of anesthetic time *Korean J Anesthesiol* 2011 July 61(1):12-18.
9. Abhinaya RJ, Venkatraman R, Matheswaran P, Sivarajan G. A randomised comparative evaluation of supraclavicular and infraclavicular approaches to brachial plexus block for upper limb surgeries using both ultrasound and nerve stimulator. *Indian Journal of Anaesthesia* 2017 July;61(7):61-66.
10. Minville V, Amathieu R, Luc G, et al. Infraclavicular Brachial Plexus Block Versus Humeral Approach: Comparison of Anesthetic Time and Efficacy. *Anesth Analg* 2005;101:1198-201.
11. Sites BD, Beach ML, Spence BC, et al. Ultrasound guidance improves the success rate of a perivascular axillary plexus block. *Acta Anaesthesiol Scand* 2006; 50:678-68.
12. De QH. Tran, Clemente A, Tran DQ, Finlayson RJ. A Comparison Between Ultrasound-Guided Infraclavicular Block Using the "Double Bubble" Sign and Neurostimulation-Guided Axillary Block. *Anesth Analg* 2008;107:1075-8.
13. Tran DQ, Russo G, Munoz L, et al. A Prospective, Randomized Comparison Between Ultrasound-Guided Supraclavicular, Infraclavicular, and Axillary Brachial Plexus Blocks. *Regional Anesthesia and Pain Medicine* 2009;34(4):366-371.
14. Sandhu NS, Caplan LM. Ultrasound-guided infraclavicular brachial plexus block. *Br J Anaesth.* 2002;89:254-259.
15. Chan VW, Perlas A, McCartney CJ, Brull R, Xu D, Abbas S. Ultrasound guidance improves success rate of axillary brachial plexus block [published correction appears in *Can J Anaesth.* 2007 Jul;54(7):594]. *Can J Anaesth.* 2007;54(3):176-182.