

## A Comparative Study to Assess and Predict the Responsiveness to Conservative Management and Ultrasound Guided Percutaneous Aspiration for Amoebic Liver Abscess

Sundeep A Naik<sup>1</sup>, Sidduraj C Sajjan<sup>2</sup>

**Author's Affiliation:** <sup>1</sup>Associate Professor, <sup>2</sup>Assistant Professor, Department of General Surgery, Vydehi Institute of Medical Sciences and Research Center, Whitefield, Bengaluru, Karnataka 560066, India.

### How to cite this article:

Sundeep A Naik, Sidduraj C Sajjan. A Comparative Study to Assess and Predict the Responsiveness to Conservative Management and Ultrasound Guided Percutaneous Aspiration for Amoebic Liver Abscess. *New Indian J Surg.* 2020;11(2):170-178.

### Abstract

**Background:** Amoebic liver abscess is an important cause of inflammatory space occupying lesion of liver. It is a common condition in India; a serious problem and associated with higher morbidity and mortality; if not managed properly. This study is conducted to know the clinical presentation, management and efficacy of conservative management and percutaneous aspiration in amoebic liver abscess.

**Materials and Methods:** A total of 30 patients of amoebic liver abscess were selected for the study in Vydehi Institute of Medical Sciences and research centre, Bangalore. Their clinical presentation, lab findings and treatment in the form of conservative (in abscess less than 5 cms diameter and volume of 125 cm<sup>3</sup>) and ultrasound guided percutaneous aspiration (in abscess more than 5 cms diameter and volume of 125 cm<sup>3</sup> or more) were studied.

**Results:** This study showed that the amoebic liver abscess was more common in low socioeconomic middle aged male patients. Male to female ratio was 6:1. Mean duration of symptoms 7.5 days in conservative management and 7 days in percutaneous aspiration patients. Pain and fever were the most common symptoms. USG abdomen was very useful

in early diagnosis and assessing prognosis. Most of the abscess was solitary and more common in right lobe of liver. Liver function tests helps in knowing effectiveness of the treatment and the prognosis. None of the patients were positive for cysts in the stool.

All 30 (100%) patients were positive for anti amoebic antibody. Conservative management was more effective in patients with cavities less than 5 cms (125 cm<sup>3</sup> volume). Two patients were converted to percutaneous aspiration. Percutaneous aspiration was more effective in patients with cavities more than 5 cms. In none of the cases of amoebic abscess surgical drainage was employed. There was mortality due to complications.

**Conclusion:** The study conclusion includes Amoebic liver abscess is more commonly seen in young to middle aged males. Ultrasonography helps in early diagnosis and reducing morbidity and mortality. It also confirms the site, size and number of amoebic liver abscess and knowing the prognosis. Liver function tests helps in knowing the effectiveness of the treatment and prognosis.

Amoebic liver abscess less than 5 cms are effectively treated by conservative management and abscess more than 5 cms by percutaneous aspiration. Resolution of abscess cavity is faster in patients treated by percutaneous aspiration as compared to conservative treatment, but duration of hospital stay is more in patients treated by percutaneous aspiration due to retained pigtail catheter for drainage for long duration. Metronidazole effective in most of the amoebic liver abscess.

**Keywords:** Amoebic; Liver abscess; Metronidazole.

**Corresponding:** Sundeep A Naik, Associate Professor, Department of General Surgery, Vydehi Institute of Medical Sciences and Research Center, Whitefield, Bengaluru, Karnataka 560066, India.

E-mail: [anatomyshs@gmail.com](mailto:anatomyshs@gmail.com)

Received on 09.01.2020, Accepted on 14.02.2020

## Introduction

Amoebic liver abscess is an important cause of inflammatory space occupying lesion of liver in the tropics,<sup>1</sup> like India. India being a tropical country and large number of unclean food and alcohol consumption add up to the risk. Decreased immunity secondary to intake of cytotoxic drugs, diabetes mellitus, and HIV infection etc. Further increases susceptibility to liver abscess.<sup>2</sup> Amoebic liver abscess is a serious problem in India. Management of this disease includes anti amoebic drugs, percutaneous aspiration in cases like (secondary infection, fever and pain persisting for more than 3 to 5 days, if rupture is suspected) and occasionally catheter drainage in case of failure of repeated aspiration. In India, however most of the patients present with large abscess cavities and toxic features needing frequent aspiration of the abscess.

The review of literature reveals that the smaller Amoebic liver abscesses (multiple or single) can be treated conservatively.<sup>3</sup> Larger Amoebic liver abscesses or amoebic liver abscess with complications (rupture, jaundice, etc.) require intervention in the form of either percutaneous aspiration, closed or open drainage. Regarding conservative treatment there are no studies indicating draw backs of prolonged conservative treatment and there are no studies which shows efficacy of needle aspiration in such cases. Further there are no studies which show complications and need of reaspiration in patients who have been treated with radiologically guided percutaneous aspiration as an initial line of management. Hence

this study is conducted to know the immediate and late effect of, metronidazole alone and a regimen comprising needle aspiration and metronidazole. The present study was conducted to study the clinical presentations, investigations, diagnosis and management of amoebic liver abscess. To study the efficacy of conservative management in amoebic liver abscess and to study the efficacy of ultrasound guided percutaneous aspiration in amoebic liver abscess.

## Materials and Methods

### Source of Data

All patients diagnosed with liver abscess in Vydehi institute of medical sciences and research Centre, Bangalore. The study conducted on 30 cases amoebic liver abscess. All the patients age above 18 years.

### Methodology

After obtaining clearance and approval from the institutional ethical committee, patients fulfilling the inclusion/exclusion criteria were included in the study, after obtaining informed consent. Detailed history of all patients is taken with thorough clinical examination; required Investigations were done. After establishing diagnosis, Tab. Metronidazole 800 mg TID or Inj. Metronidazole 500 mg IV TID treatment was initiated from day of admission, in case of secondary infection; antibiotics (Fluroquinolones or 3<sup>rd</sup> Generation cephalosporin's) were added in the treatment (Figs. 1,2,3).



Fig. 1: E. Histolytes, iodine stain showing trophozoites.

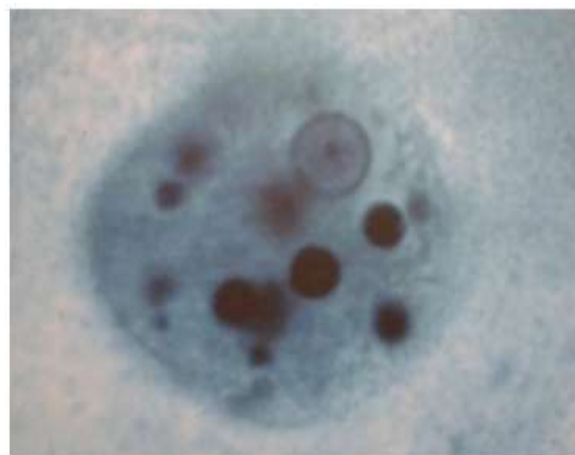


Fig. 2: E. histolytica, trophozoites with ingested red blood cells.

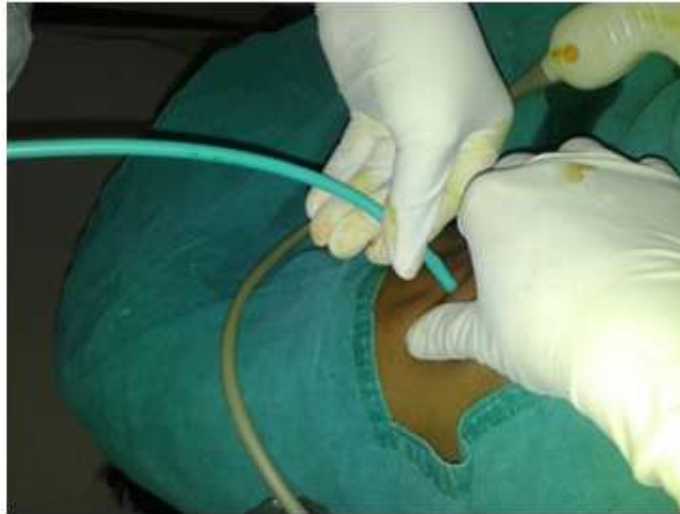

Fig. 3: USG guided pigtail catheterisation of liver abscess.

Therapeutic aspiration reserved for the following cases where: Size of abscess is more than 5 cm in diameter (125 ml). When pain and fever persist for more than 3 to 5 days after starting Antiamoebic therapy. Four clinical variables-abdominal pain, fever, anorexia, and hepatomegaly-were assessed on first, fourth, and 10<sup>th</sup> day. Hematological (ESR, and total and differential counts) and biochemical studies (serum aspartate and alanine aminotransferase activities, and alkaline phosphatase activity) were carried out in all patients on first, fourth, and 10<sup>th</sup> day. A raised ESR rate of more than 30 mm in 1<sup>st</sup> hour, total leukocyte count of  $12.0 \times 10^9/l$ , serum alkaline phosphatase activity of more than 13 King Armstrong units and aspartate aminotransferase activity more than 40 U/l were considered abnormal and successful outcome was marked by a normalization of these variables. The patients were asked to visit for reassessment once a month for 3 months. Each treatment modality studied separately for the proportion of patients with successful outcome under each category were calculated, Chi-square test, Fishers, *t*-test and ANOVA tests were applied.

## Results

A total of 30 patients of amoebic liver abscess were included in Vydehi institute of medical sciences and research Centre, Bangalore. Following data were collected and analyzed. Out of the 30 cases, 21 (70%) patients had right lobe liver abscesses, 5 (17%) Patients had abscesses in left lobe of liver and both lobes of liver in 4 (13%) of patients (Table 1).

Table 1: Lobe of liver involvement

Lobes	No of Cases	Percentage
Right	21	70
Left	5	17
B/L	4	13
<b>Total</b>	<b>30</b>	<b>100</b>

Out of 30 patients, 22 (73%) patients had one abscess, 6 (20%) had two abscesses and 2 (7%) of patients had 3 abscesses (Table 2).

Table 2: Number of abscess

No of Abscess	No of Cases	Percentage
1	22	73
2	6	20
3	2	7
<b>Total</b>	<b>30</b>	<b>100</b>

All patients with amoebic abscess cavity size less than 5 cms were treated conservatively. In Patients treated by percutaneous aspiration, 12 were having cavities ranging 11–25 cms and 5 with cavities ranging 6–10 cms (Table 3).

Table 3: Distribution of size of amoebic liver abscess on the day of admission

Diameter of Abscess Cavity in cms	No of Cases	
	Conservative Group	Aspiration Group
<5	12	0
6–10	0	5
11–25	0	12
>25	0	1

Sixty percent of patients were treated by ultrasound guided percutaneous aspiration and 40% of patients were treated by conservative management (Table 4).

**Table 4:** Treatment modality

Treatment	No of Cases	Percentage (%)
C	12	40
A	18	60
<b>Total</b>	<b>30</b>	<b>100</b>

Ten patients treated by conservative management showed improvement and two patients had no improvement in clinical and laboratory signs and symptoms. Out of 18 patients treated by ultrasound guided percutaneous aspiration 14 patients had improved symptomatically (Table 5).

**Table 5:** Symptoms on day 4<sup>th</sup> of treatment

Symptoms	Conservative	Aspiration
Day 4 Improved	10 (33%)	(14) 47%
Day 4 Not Improved	(2) 7%	(4) 13%

Patients treated by percutaneous aspiration showed marked decrease in size of abscess cavity, as 6 patients were having cavities less than 5 cms and 11 patients in the range of 6–10 cms. Only one patient not improved (Table 6).

**Table 6:** Distribution of size of amoebic liver abscess on 4<sup>th</sup> day of admission and reduction of size of cavity.

Diameter of Abscess Cavity in cms	No of Cases	
	Conservative	Aspiration
<5	12	6
6–10	0	11
11–25	0	0
>25	0	1

**Table 9:** Distribution of LFT on 4<sup>th</sup> and 10<sup>th</sup> day of treatment

LFT (SGOT, SGPT)	I		NI		Total	
	No of Patients	%	No of Patients	%	No of Patients	%
Day 4	16	53.3	14	46.7	30	100.0
Day 10	29	96.7	1	3.3	30	100.0

## Discussion

Worldwide, amoebic liver abscess is the third most common parasitic cause of death. Global incidence of infection is 12% and 50% of asymptomatic people may harbour amoebae in tropical and subtropical regions. The incidence is ten times more common in adults than in children, males are affected 3 to

All patients treated either by conservative or percutaneous aspiration showed statistically significant ( $p < 0.001$ ) symptomatic improvement, except one case with secondary infection in aspiration group (Table 7).

**Table 7:** Symptoms on day 10<sup>th</sup> of treatment

		Treatment		
		C	A	Total
Day 10	I	12 100.0%	17 94.4%	29 96.7%
	NI	0 0.0%	1 5.6%	1 3.3%
<b>Total</b>		12 100.0%	18 100.0%	30 100.0%

All patients treated either by conservative or percutaneous aspiration showed statistically significant ( $p < 0.001$ ) regression in size of amoebic liver abscess cavity, except one case with secondary infection in aspiration group (Table 8).

**Table 8:** Distribution of size of amoebic liver abscess on 10<sup>th</sup> day of admission and reduction of size of cavity.

Diameter of Abscess Cavity in cms	No of Cases	
	Conservative	Aspiration
<5	12	17
6–10	0	0
11–25	0	0
>25	0	1

There is statistically significant ( $p < 0.00$ ) improvement in liver function tests in all patients except one patient with secondary infection both on day 4 and day 10<sup>th</sup> of treatment (Table 9). One patient expired in our study due to complications and remaining patients were recovered from the illness.

10 times more commonly than females<sup>4</sup>. A study conducted by Wells, Christopher D. et al. showed that Amoebic liver abscess is the most common extra intestinal manifestation of infection with Entamoeba histolytica, and it is associated with significant morbidity and mortality<sup>5</sup>. Hence early diagnosis and treatment of the illness can prevent the complication and sequelae.

This study consists of 30 patients admitted to Vydehi institute of medical sciences and research centre, Bangalore. All cases met inclusion and exclusion criteria. The clinical presentations, diagnosis and management of amoebic liver abscess by conservative management in one group of 12 patients and another group of 18 patients by ultrasound guided percutaneous aspiration are discussed. In the present study the common age group was found between 31–50 years comprising 16 (53.3%) cases. Similar results have been reported by several workers, which are comparable with the present study as shown in the following table no:-

**Table 10:** Age incidence of liver abscess in different studies

Authors	Age group	Percentage (%)
Mishra et al. <sup>6</sup>	30–40	82
Turrill & Burnham <sup>7</sup>	20–24	92.0
Barbour & Juniper <sup>8</sup>	21–50	84.0
Present study	31–50	53.3

In our study 30 patients were included, 26 were males constituting 87% of the study population. In the present study the male to female ratio was 6:1. The increased ratio may be due to the fact the patients in our study belonged to the lower socioeconomic status and alcohol intake in the patients.

**Table 11:** Sex incidence of liver abscess in different studies

Authors	Male (%)	Female (%)	Male:Female
Habibullah et al. <sup>9</sup>	91.8	8.2	11:1
Galen et al. <sup>10</sup>	85	15	5:1
Turrill et al. <sup>7</sup>	86	14	6:1
Katzenstein et al. <sup>11</sup>	85	15	5:1
Present study	87	13	6:1

In present study out of 30 patients who had amoebic liver abscess, 26 were males (87%). The results of the present study are comparable with the study done other authors. All the patients in the study were from lower socio economic status. It is well known that amoebiasis is common in slum dwellers due to bad sanitation, poverty, ignorance and their poor nutritional status. Alcohol is believed to be one of the predisposing factors in the pathogenesis with statistics showing a more than five-fold incidence of ALA among drinkers.<sup>12</sup> 47% of patients were alcoholic in present study. History of alcoholism was found in 20–30% of cases by Kini and Mammi.<sup>13</sup> Hai et al. found a history of alcohol consumption in 85% of patients with ALA.<sup>12</sup> Joshi et al.<sup>14</sup> found a higher mortality rate in those consuming large quantities of alcohol.

The commonest clinical feature was pain abdomen in our study. Pain was a complaint in all the cases in this study (100%) it was present in right hypochondriac area of abdomen. The nature of the pain was dull aching in majority of the patients and sharp stabbing nature in few patients. The incidence of pain in various studies is compared with the present study in following table 12.

**Table 12:** Incidence of pain in various studies

Authors	Percentage (%)
Kapoor et al., <sup>14</sup>	100
Mehta & vakil <sup>15</sup>	87.4
Katzenstein et al. <sup>11</sup>	88
Present study	100

Fever was the next common symptom present in 25 cases (83%) in present series. In the majority of cases fever was of low grade and continuous. In 20 (66%) patients belonging to both conservative and percutaneous aspiration groups fever had subsided by day 4<sup>th</sup> of treatment. One case with secondary bacterial infection had persistent fever. The incidence of fever in the literature and the present study is compared in the following table 13.

**Table 13:** Incidence of fever in various studies

Authors	Percentage (%)
Mehta & Vakil <sup>15</sup>	90.0
Galen et al. <sup>10</sup>	94.0
Present study	83.0

In the present study 11 cases (37%) had history of diarrhoea in past week. This finding is comparable with other studies. But there is wide variation in reported studies. Craig has enumerated the findings of various authors. He states that 60–90% give previous history of diarrhoea/dysentery. Raghavan et al. recorded 9.8% of the 193 cases with diarrhoea symptoms.<sup>16</sup> Barbour & Juniper<sup>8</sup> in the study of 33 cases could record history of accompanying dysentery in 50% of cases. Chaves et al. reported 22% of their cases with past history of dysentery.<sup>17</sup> Jaundice was seen in 5 (17%) of cases. Majority of them belonging to aspiration group, Sharma et al. detected jaundice in 30% of the patients. 36% (11) of patients in our study were having hepatomegaly. Kapoor<sup>14</sup> study showed 100%, Ramachandran et al.<sup>9</sup> detected 70.5% to have hepatomegaly.

In our study inter costal tenderness was noted in 8 cases (26%). Mehta & vakil<sup>15</sup> reported 19% of their cases had Intercostal tenderness, where as Barbour & Juniper found in 71.2% of their cases.<sup>8</sup> In the present study one case (3.3%) with secondary

bacterial infection had pleural effusion, which was very minimal in quantity. Raghavan et al.<sup>16</sup> reported pleural effusion in 19 cases (15.5%) and consolidation of the right lung base in 45 of 126 cases studied. Involvement of pleura manifested as dry pleurisy in 5 cases, pleurisy with effusion in 17 cases and bursting of liver abscess into pleura into 2 cases. Lung involvement resulted in collapse in 2 cases, consolidation in 3 cases and bursting of liver abscess into lung in 2 cases.

In the present study, the mean duration of symptoms at presentation in the conservative group was 7.5 days. While the mean duration of symptoms in percutaneous aspiration group was 7 days. Statistically no significant difference was found between the two groups.

In our study duration of symptoms varied from 7 days to 2 months, when compared to other studies mentioned as further: Studies in literature have reported the shortest duration was one day and the average was from ten days to two weeks in acute group; in the chronic group, the longest duration was three years and the average from three to six months.

In other cases, the duration of illness prior to presentation has been reported to be from one day to three years with a median of one to eight weeks.<sup>17</sup> Another study has reported that the duration of illness prior to presentation varied from eight days with a range of three days to four and a half months.<sup>18</sup> Other authors reported the duration of symptoms to vary from 4 days to 12 weeks but majority of patients had presented within two weeks of symptoms.<sup>19</sup> The average duration of symptoms has also been reported to be 2½ months (range 8 days to 9 months)<sup>20</sup>, which is at variance with another report that the average duration of presentation was 2 to 12 weeks.<sup>15</sup> The present average duration of symptoms in our study is, therefore, same as reported in earlier studies.

In our study 18 (60%) patients had elevated WBC counts. Leucocytosis was found to be raised in the range of 4600–19000 cells/cu mm. mean counts were  $8238 \pm 4007$ . This is one of the parameters in assessing the improvement after initiation of the drug therapy. Various workers reported leucocytosis in liver abscess as follows. Katzenstein found leucocytosis in 63 cases of 67 cases studied.<sup>11</sup> Usually polymorpho-nuclear leucocytes predominate.

The correlation between degree of anaemia, leucocytosis and duration of illness reveal that patients with a short history tend to show no

anaemia but appreciable leucocytosis, where as those with long history show appreciable anaemia with less marked leucocytosis.

Anaemia is one of the common findings accompanying liver abscess. Haemoglobin of less than 12 gms was found in 5 cases (17%) in this study. Anaemia is very common in chronic infection. The serum bilirubin was raised (>1 mg/dl) in 7 cases (23%) of the present study. 5.8% of patients treated conservatively and aspiration (16.2%), respectively had raised serum bilirubin. Serum transaminases (>40 IU) were raised in 15 (50%) patients in this study. Serum transaminases was raised in 50% of cases in Katzenstein et al.<sup>11</sup> series.

Out of 30 cases of amoebic liver abscess in the present study none of cases had *Entamoeba histolytica* cysts in the stools. DeBakey & Oschner<sup>21</sup> found *Entamoebahistolytica* trophozoites in 15.4% of cases. In our study Amoebic serology (anti amoebic antibody) was positive in all 30 patients. Kraoul compared the capability of rapid enzyme immuno assay (EIA) to detect Antiamoebic antibodies during hepatic amebiasis with those of indirect haemagglutination and latex agglutination. Enzyme immuno assay of 143 patient's sera yielded a specificity, a sensitivity, and positive and negative predictive values of 100, 93, 100, and 97.1, respectively. This test could thus be considered another valuable tool for the diagnosis of hepatic amebiasis.<sup>22</sup>

A study in central Vietnam had reported a 94.5% prevalence of anti-amoebic antibodies in cases of amoebic liver abscess. Another study had reported 77% cases of liver abscess to be positive for amoebic serology.<sup>23</sup> In another study, 79 out of 82 patients (96.3%) of amoebic liver abscess were reported to be positive for amoebic serology. Up to 10% of the patients with acute amoebic liver abscess may have negative serological findings. Asymptomatic carriers of *E.histolytica* are also known to develop antibodies, thus serological tests are helpful in assessing the risk of invasive amoebas in asymptomatic cyst passers in an endemic area<sup>24</sup>. The value this diagnostic test in the setting of acute disease in endemic areas is less because they remain positive for many years.

In the present study Most of the of patients 21 (70%) had right lobe amoebic liver abscesses; 5 (17%) patients had abscesses in Left lobe and both lobes of liver involved in 4 (13%) of the patients. 22 (73%) out of 30 (100%) patients had one abscess; 6 (20%) had two abscesses. 2 (7%) patients had 3 abscesses. Galen et al. in their studies showed that

the majority of the amoebic liver abscesses were solitary.<sup>10</sup> Our study was consistent with their study. In the present study elevation of right hemi diaphragm was found in 11 patients (36%) and one (3.3%) patient with minimal pleural effusion on right side. Similar findings have been reported by the various workers. In Ramachandran et al., 3.6% were found to have pleural effusion. Habibullah et al. 60% of cases<sup>9</sup> and Chaves found positive results in 60% of the cases.<sup>17</sup> In our study 12 (40%) patients were treated conservatively and 18 (60%) patients were treated by percutaneous aspiration and conservative management. In our study; liver abscess aspiration was done in 20 patients (66.6%) because 2 patients of conservative group didn't responded. The amount of pus drained, varied from 50 to 300 ml. The colour of the pus, which was aspirated from the liver, was anchovy sauce in colour. In one patient it was reddish green that had secondary bacterial infection. Manson-Bahr expresses that the mere presence of anchovy sauce signifies positive diagnosis of amoebic liver abscess.<sup>25</sup> If the abscess is connected with the biliary tree then the aspirate becomes greenish.

In our study the pus in 29 cases was sterile bacteriologically and trophozoites of *E. histolytica* were not demonstrated in any one of them. Barbour and Juniper; in 33 cases of amoebic liver abscess, could find trophozoites in the pus of only 4 cases.<sup>8</sup> 10 cases had trophozoites in the walls of the abscess cavity.

In our study none of the cases of amoebic abscess; surgical drainage was employed. Out of 12 patients who were treated conservatively, 2 cases did not respond to conservative treatment, and ultrasound-guided aspiration was performed. Out of 18; 17 patients who were treated by percutaneous aspiration responded well to the treatment and one patient did not responded to aspiration and died due to complications of secondary infection, signs of right sided pleural effusion and rupture of abscess into pleural and peritoneal cavity and died on 25<sup>th</sup> day due to septicaemia. Miedma and Dineen<sup>26</sup> presented a series of 106 patients with pyogenic hepatic abscess and reported that despite easier diagnosis, the mortality rate remained high (53%).

In our study clinical, biochemical and ultrasound findings at the time of admission, on day 4<sup>th</sup> and on day 10<sup>th</sup> were considered to know the efficacy of conservative management and percutaneous aspiration of amoebic liver abscess. Out of 12 patients who were treated by conservative treatment 2 patients were converted to pigtail catheter

drainage due to persistent of fever, increased WBC count, deranged liver function tests even on day 4 of the treatment. All patients with the initial insertion of pigtail catheter improved and did not require change in the modality of treatment. There was statistically significant decrease in the size of cavity on the 4<sup>th</sup> day and 10<sup>th</sup> day of treatment in case of percutaneous aspiration as compared to patients who were treated by conservatively.

In one study by Kapadia et al., the pigtail drainage was reported to have marked resolution of liver abscess, when it was considered to be successful, ultrasound was suggestive of total resolution or reduction of size to <3 cm. This study had reported the complete resolution of liver abscess in 88% of cases within 4 months. But in this study the pigtail catheter drainage was done in abscess size >5 cm,<sup>26</sup> and there was no comparison with patients of similar size treated by conservative management.

In one study by Sheeny TW et al.<sup>27</sup> open surgical drainage or needle aspiration of pus or both in combination did not appear to shorten the resolution time of an ALA. Rajak CL et al. mentioned that the average time taken by pigtail catheter for reduction of the abscess cavity to 50% of its original size was 5 days<sup>28</sup>. Berry M et al. study had reported complete resolution in only three out of 44 patients (6.8%) after medical therapy.<sup>29</sup> When compared, our study revealed at 3 months of Follow-up of 18 patients out of 30 had complete resolution of cavity, in aspiration Group 13 patients and in conservative Group 5 patients.

In our study 11 patients had lost the Follow-up and one case died and in remaining cases cavity was completely resolved. But resolution of cavity size was earlier in case of percutaneous aspiration as compared to the delayed resolution in case of conservative treatment. On the basis of ultrasound findings; when the size of abscess was found to be markedly decreased; pigtail catheter removal done. The period ranged from 10 to 45 days with the mean of 15.6 days. Kapadia S and Sheen LS<sup>26</sup> studies had reported that the pigtail was removed when the patient had become asymptomatic, pus drainage was less than 10 ml in 24 hours for 2 consecutive days and the sonogram showed a negligible cavity.

Thus our study clearly proves that the improvement in clinical and laboratory parameters in case of conservative treatment (where cavity size less than 5 cms and volume of 125 cm<sup>3</sup>) on day 4<sup>th</sup> and day 10<sup>th</sup> was statistically significant; which is similar to percutaneous aspiration group. However the rate of decrease in size of the abscess cavity was

lesser in the conservative group than in percutaneous aspiration group. The study clearly indicates that uncomplicated abscess measuring less than 5 cms (125 cm<sup>3</sup>) are better treated by conservatively and cavities more than 5 cms (125 cm<sup>3</sup>) are treated by ultrasound guided percutaneous aspiration.

## Conclusion

Amoebic liver abscess is more commonly seen in young to middle aged males. Ultrasonography helps in early diagnosis and reducing morbidity and mortality. It also confirms the site, size and number of amoebic liver abscess and knowing the prognosis. Liver function tests helps in knowing the effectiveness of the treatment and prognosis. Amoebic liver abscess less than 5 cms are effectively treated by conservative management and abscess more than 5 cms by percutaneous aspiration. Resolution of abscess cavity is faster in patients treated by percutaneous aspiration as compared to conservative treatment, but duration of hospital stay is more in patients treated by percutaneous aspiration because of retained pigtail catheter for drainage for longer duration. Metronidazole is effective in all cases of amoebic liver abscess. No complications encountered in case of percutaneous pigtail catheterization. Mortality was encountered in one patient with secondary infection of amoebic liver abscess who had both complication of rupture into peritoneal and pleural cavities.

## References

1. Choudhuri G, Rangan M et al. Amebic infections in humans. *Indian J Gastroenterol* 2012 Jul;31(4):153-62.
2. Mukhopadhyay M, Kumar AK, Sarkara, et al. Amoebic liver abscess: Presentation and complications. *Indian J Surg* 2010 Feb;72(1):37-41.
3. Sharma MP, Dasarathy S, Verma N, et al. prognostic markers in amoebic Liver Abscess: A Prospective Study. *Am J Gastroenterol*, December 1996;91:2584-89.
4. Thomas PG and Garg N. Amebiasis and other parasitic infections: chapter 60; Leslie h. Blumgart, Jacques belghiti, William C. Chapman, Markus W. Bucher, Lucy E. Hann, Michael D. Angelica. Saunders/Elsevier, Philadelphia Fourth edition, 2007.pp.927-950.
5. Wells, Christopher D., Arguedas, Miguel: Amoebic Liver Abscess. *Southern Medical Journal* 2004;97:673-82.
6. Mishra D, Mohante KD. *Ind. J. Paediat* 1960;36:481.
7. Turrill FL, Burnham JR. Hepatic amebiasis. *Am J Surg* 1966;111:424-430.
8. Barbour GL, Juniper K Jr. A clinical comparison of amoebic and pyogenic abscesses of liver in 88 patients. *Am J Med* 1972;53(3):323-34.
9. Habibullah CM, Ramachandran RS, et al. *J. Ind. Med. Ass* 1977;69:247.
10. Galen L., Kerrison Jr., A clinical comparison of amebic and pyogenic abscess of the liver in sixty-six patients. *American Jou. MED Sept* 1972;53(3):323-32.
11. Katzenstein D, Rickerson V, Braude Abraham: New concepts of amoebic liver abscess derived from hepatic imaging, serodiagnosis, and hepatic enzymes in 67 consecutive cases in San Diego. *Medicine* 1982;61(4):237-46.
12. Hai AA, Singh A, Mital VJ, et al. Amoebic liver abscess. Review of 220 cases. *Int Surg* 1991;76(2):81-3.
13. Kini PM, Mammi MI. Hepatic amebiasis in Kerala. *J Ind Med Asso* 1970;55:7-9.
14. Joshi VR, Kapoor OP, Purohit AV, et al. Jaundice in amoebic abscess of liver. *J Assoc Phy India* 1972;20(10):761-4.
15. Vakil BJ, Mehta A. Atypical manifestations of amoebic abscess of liver. *J. Trop. Med. Hyg* 1970;73:63-67.
16. Raghavan P, Kurian J et al., *J Ass. Phys. Ind* 1961;9:568.
17. Chaves DCJZ, Gomes C, Domingues W, et al. Hepatic amoebiasis. Analyzis of 56 cases *Amj Gastroenterol* 1977;68(2):134-40.
18. Sharma MP, Sarin SK. Amoebic liver abscess in a north Indian hospital current trends. *Br J Clin Pract* 1987;41(6):789-93.
19. Salles MJ, Moraes AL, salles CM. Hepatic amebiasis. *Braz J Infect Dis* 2003;7:1-20.
20. Shabot MJ, Patterson M. Amebic liver abscess: 1966-1976. *Dig Dis* 1978;23(2):110-18.
21. Ochsner A, DeBakey M, Murray S. Pyogenic abscess of the liver: II. An Analyzis of forty-seven cases with review of the literature. *Am J Surg* 1938;40(1):293-319.
22. Karaoul et al. Rapid enzyme immunoassay for diagnosis of hepatic amoebiasis. *Journal of clinical microbiology* 1997 Jun;35(6):1530-2.
23. Lodhi S, Sarwari AR, Muzamil M, et al. Features distinguishing amoebic from pyogenic liver abscesses: a review of 577 adult cases. *Trop Med Int Health* 2004;9(6):718-23.



24. Mathur S, Gehlot SR, Mohta A, et al. Clinical profile of amoebic liver abscess. *J Ind Acad Clin Med* 2002;3(4):367-73.
25. Manson-Bahr PH, Manson's tropical disease, Cassell and Co., London 1967.
26. Kapadia S, Duttaroy D, Ghodgaonkar p, et al. Percutaneous catheter drainage of liver abscesses. *Indian J Surgery* 2002;64(6):516-19.
27. Sheeny TW, parmely Jrl F, Johnston GS, et al. Resolution of an Amebic liver abscess. *Gastroenterology* 1968;55(1):26-34.
28. Rajak CL, Gupta S, Jain S, et al. Percutaneous Treatment of liver abscesses: needle aspiration versus catheter drainage. *AM J Radio* 1998;170:1035-39.
29. Berry M, Bajaj R, Bhargava S. Amebic liver abscess: sonographic diagnosis and management. *J Clin Ultrasound* 1986;14:239-42.