

## A Comparative Study on Ultrasound- Guided Supraclavicular Brachial Plexus Block Vs Ultrasound Guided Nerve Stimulated Supraclavicular Brachial Plexus Block

Sugantharaj Anuradha<sup>1</sup>, Carolin Von Mullai A<sup>2</sup>, Sakthi Abirami<sup>3</sup>

<sup>1</sup>Professor <sup>2</sup>Senior Assistant Professor <sup>3</sup>Senior Resident, Institute of Anaesthesiology and critical care, Rajiv Gandhi Government General Hospital, Madras Medical College, Chennai, Tamil Nadu 600003, India

### Abstract

**Background:** The brachial plexus block can be performed by the landmark nerve technique, nerve stimulator guided (NS) or (ultrasound (US)-guided technique. A patient need not be subjected to the discomfort of paresthesia when the nerve is stimulated to produce a motor twitch, because motor fibers have a lower electrical threshold than sensory fibers. The use of the NS technique, however, did not reduce the complication rates. Therefore, the combined nerve stimulator and ultrasound-guided approach are much preferred. For supraclavicular brachial plexus block. **Aim of the Study:** Targeting the individual nerve bundles using a nerve stimulator would obtain a higher success rate for ultrasound-guided supraclavicular brachial plexus block. **Materials and Methods:** 66 patients presenting for upper limb surgeries under USG guided Supraclavicular brachial plexus block were randomly assigned into 2 Groups. Group USG NS- Ultrasound-guided, nerve stimulated Supraclavicular block group USG - Ultrasound-guided Supraclavicular block patients received a mixture of 23 ml of a local anesthetic containing 2% Lignocaine 11.5 ml and 0.75% Ropivacaine 11.5 ml. Group USG NS- ( $n = 33$ ) - half the volume of drug is injected into 'corner pocket' guided by USG, confirmed by nerve stimulation and remaining half the volume is injected into main neural cluster under USG guidance, confirmed by nerve stimulation. Group USG - Under USG guidance half the volume was deposited in 'corner pocket' and half the volume was injected in the main neural cluster. Sensory and motor blockade of ulnar nerve, median nerve, musculocutaneous nerve, and radial nerve was recorded at different time intervals. Surgical anesthesia, number of needles passes, performance time and complications were also recorded. **Results:** Compared with Group USG, Group USG NS had higher success rate of combined sensory-motor block within 15 min (79% vs 52%,  $p < 0.001$ ). The success rate of sensory block of 4 nerves within 15 min is higher in Group USG NS (Ulnar nerve-91 vs 70%, Median nerve - 91 vs 73%, radial nerve-88 vs 67%, Musculocutaneous nerve 88 vs 64%,  $p < 0.001$ ). The performance time is increased by 4 min in USG NS Group ( $14.3 \pm 2.88$  vs  $10.33 \pm 5.69$  min,  $p < 0.001$ ). **Conclusion:** USG guided nerve stimulated supraclavicular brachial plexus block provides higher success rate and complete sensory-motor blockade of all four nerves within 15 minutes of local anesthetic injection.

**Keywords:** Ultrasound; Nerve stimulator; Supraclavicular; Brachial plexus block.

### How to cite this article:

Sugantharaj Anuradha, Carolin Von Mullai A, Sakthi Abirami. A Comparative Study on Ultrasound- Guided Supraclavicular Brachial Plexus Block Vs Ultrasound Guided Nerve Stimulated Supraclavicular Brachial Plexus Block. Indian J Anesth Analg. 2020;7(1 Part -II):400-407.

**Corresponding Author:** Carolin Von Mullai A, Senior Assistant Professor, Institute of Anaesthesiology and critical care, Rajiv Gandhi Government General Hospital, Madras Medical College, Chennai, Tamil Nadu 600003, India.

**E-mail:** mullai.md@gmail.com

**Received on** 09.11.2019, **Accepted on** 03.01.2020

## Introduction

The Supraclavicular approach to the Brachial Plexus Block (SBPB) is preferred in upper extremity surgeries because it has the anatomical advantage of the blockade at a level where the trunks and divisions are tightly grouped.<sup>1,2</sup> State of the art ultrasound technology for supraclavicular blocks helps localize the brachial plexus accurately and improve success rates.<sup>3,4</sup> With the use of nerve stimulators, the needle tip can be positioned adjacent to a nerve by eliciting an appropriate motor response.<sup>5</sup> The aim of the study was to compare the success rate of the block between the ultrasound-guided technique and the combined ultrasound-guided, nerve stimulated technique. The region innervated by the ulnar nerve is often spared as this nerve originates entirely from the inferior trunk of the brachial plexus. In the classical double injection technique described by Tran,<sup>6</sup> the ultrasound is used to block the inferior trunk (the ulnar nerve) and the first increment of local anesthetic is given lateral to the subclavian artery and superior to the first rib (the corner pocket). In the Modified Double Injection Technique (MDI) described by Quechua Luo,<sup>7</sup> in addition to the Ultrasound, a nerve stimulator was used to identify the ulnar nerve by eliciting motor response and the local anesthetic was deposited lateral to the subclavian artery and superior to the first rib (the 'corner pocket').<sup>8</sup> We assumed that a modification of the double - injection technique by combining ultrasound guidance with nerve stimulator would improve the onset and effectiveness of the blockade and used this technique to block all the four nerve including the ulnar nerve.

## Materials and Methods

The study was conducted at the Rajiv Gandhi Government General Hospital, Madras Medical College from July 2018 to November 2018. After obtaining written informed consent, patients belonging to ASA physical status I and II, aged 18-60 years posted for elective orthopedic procedures of the upper extremity were included in this study. Patients who refused consent and Patients with a difficult airway, coagulopathy, neuropathy, infection at the needle insertion site, allergy to the local anesthetic drugs used were excluded from this study. Randomization was done, dividing patients into one of two groups.

Ultrasound-guided supraclavicular brachial plexus block using a classical double-injection technique (Group USG) or Ultrasound-guided supraclavicular brachial plexus block combined with nerve stimulator using a modified double-injection technique. (Group USG-NS).

### Technique

On arrival in the operating room, patients were connected to the standard monitors. Oxygen supplementation was given through nasal cannula at 3-4L/min. The patients were premedicated with Inj. Midazolam 1 mg and inj. Fentanyl 50 µg. A high-resolution ultrasound machine (Sonosite) with a Linear array probe with a 6-13 Hz frequency was used for visualization of the brachial plexus. A 22G, 10 cm stimulating needle with a peripheral nerve stimulator (Braun, Messenger, Germany) was used. All blocks were performed by experienced anesthesiologists.

### Group USG

The classical double-injection technique described by Tran et al.<sup>6</sup> was followed with ultrasound guidance. A 90 mm, 23-G Quincke Spinal needle was inserted in-plane after obtaining a short-axis view of the subclavian artery and the neural clusters close to the artery, (Fig. 1). The needle tip was directed towards the "corner pocket which lies in the angle between the first rib and subclavian artery in a lateral to medial direction. Half the volume (11.5 ml) of a local anesthetic mixture of 0.75% Ropivacaine and 2% lignocaine was injected in the corner pocket after confirming negative aspiration, (Fig. 2). The needle was withdrawn and redirected towards the main neural cluster which was visualized by ultrasound. Here, the remaining Local anesthetic mixture of 11.5 ml was injected.

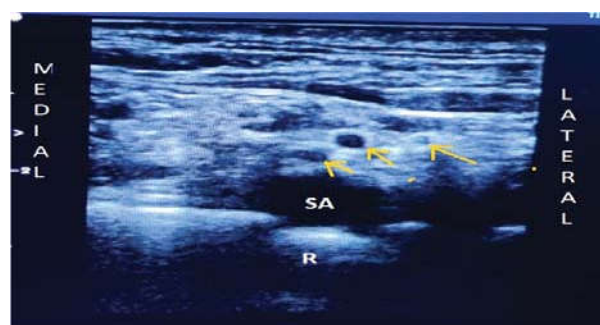
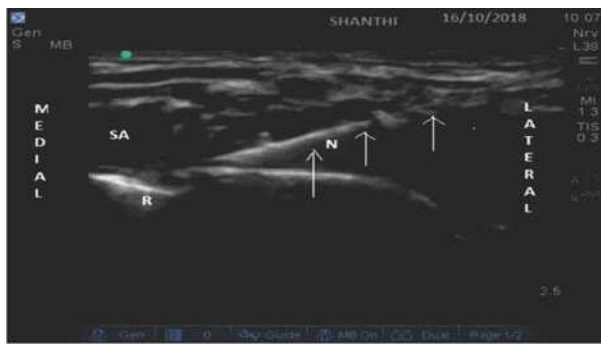


Fig. 1: Transverse Sonogram showing the main neural cluster (arrows) of the brachial plexus which are visualized as hypoechoic circular structures SA-Subclavian Artery, R-First Rib.



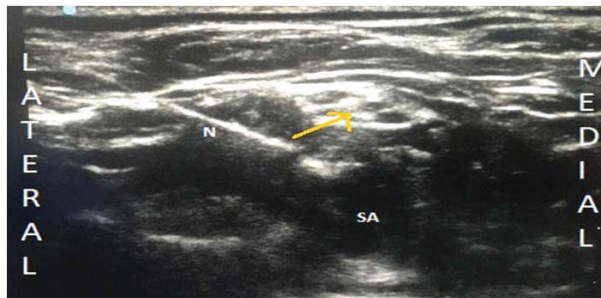**Fig. 2:** Transverse sonogram of the needle (arrows) with the needle tip in the corner pocket N-Needle, R-First Rib, SA-Subclavian Artery.

#### Group-USG-NS

A modification of the double-injection technique was followed for this group. The nerve stimulating needle was directed towards the corner pocket. After obtaining a real-time ultrasound image of the same, the nerve stimulator was turned on and the electric current of 0.4 mA (2 Hz frequency, pulse width 0.1 ms) was used to stimulate the nerve. Muscle twitch response for ulnar nerve was observed i.e. flexion or paresthesia of fourth or fifth finger or thumb adduction. 11.5 ml of the same local anesthetic mixture as described previously was injected at the location after eliciting the desired motor response. The needle was then redirected and repositioned near the main neural cluster. Muscle twitch response was elicited for any one of the following nerves: Flexion of 2<sup>nd</sup> or 3<sup>rd</sup> finger for median nerve, an extension of fingers or wrist extension for radial nerve, flexion of forearm for musculocutaneous nerve. The remaining volume (11.5 ml) was deposited in the neural cluster after obtaining adequate muscle twitch with the same level of electric current, (Fig. 3).

#### Measurements

The sensory-motor blockade of the four nerves (median, radial, ulnar and musculocutaneous



**Fig. 3:** Transverse sonogram showing the needle targeting the neural cluster which is pushed up by the local anesthetic spread. N-Needle, SA-Subclavian Artery

nerve) was evaluated at 3, 6, 9, 12, 15 and 30 min after local anesthetic injection. The primary outcome measure was the sensory and motor block success rate of all four nerves. Both sensory and motor blockade of the median, radial and ulnar and musculocutaneous nerves were assessed using a 3-point scale. An ice bag was used for the sensory testing, this was 0 = normal cold sensation 0 = no block, 1= partially block of cold sensation and 2 = complete anesthesia. No cold sensation: For motor this was 0 = Normal power, 1= Partial paresis, 2 = Paralysis Sensory block was evaluated in the innervated area of the four nerves as follows: Musculocutaneous (lateral forearm), median (palmar aspect of the second finger), radial (dorsum of the hand between the thumb and second finger) and ulnar (fifth finger). Motor blockade was assessed by elbow flexion (musculocutaneous), wrist flexion (median nerve), wrist extension (radial nerve) and flexion of the fourth and the fifth finger (ulnar nerve). A sensory-motor block score of 16 was considered satisfactory. This was possible when sensory and motor block scores of all four nerves reach point 2 (complete anesthesia). The secondary outcomes were the performance time, number of needle passes and success rate of surgical anesthesia. We also recorded the incidence of vascular puncture, paresthesia during the procedure and Horner's syndrome. The performance time was defined as the time from the start of initial scanning to the removal of the needle, for both techniques. Needle pass was defined as the need for the needle tip to be withdrawn and redirected at least 10 mm. Surgical anesthesia is the ability to proceed with surgery without the use of analgesics or general anesthesia. When patients complained of pain during surgery, the block was considered inadequate and general anesthesia was administered.

#### Statistical Analysis:

A pilot study was performed with ultrasound-guided supraclavicular brachial plexus block to estimate the percentage of complete sensory block at 15 min. The rate was 50% at 15 min by this approach. We assumed that combining ultrasound with nerve stimulator would increase this proportion to 80%, with a 95% level of significance and 80% power. Thus, a sample size of 33 in each group was required to accomplish this goal. SPSS Window 16.0 was used for statistical analysis. The normality of the data was tested using the Kolmogorov - Smirnov test and then the Student "t" test was used to compare continuous variables. Sensory block at different times was compared by using Friedman Repeated Measures Analysis of Variance on Ranks for

within-group comparisons and Kruskal - Wallis one-way analysis of variance on ranks for intergroup comparisons, and the P-value was calibrated. Categorical data were analyzed using the Chi-square test. We considered *p* - values of less than 0.05 to be statistically significant.

## Results

There was no statistical difference between groups with respect to age, sex, BMI, ASA-PS classification and the surgical site. In the USG-NS group, the performance time was 4 minutes longer compared to USG Group ( $14.3 \pm 2.88$  Vs  $10.33 \pm 5.69$ ,  $p < 0.001$ ). surgical anesthesia in both groups was similar. Although 3 patients in USG Group required general anesthesia, it was not statistically significant. There was no difference found in terms of number of needle passes, paresthesia during procedure, vascular puncture and Horner's syndrome, (Fig. 4).

A complete sensory block of all four nerves block was achieved within 15 minutes in > 90% of patients in the USG-NS Group in comparison with the USG Group. (Ulnar nerve-91% Vs 70%, Median nerve-91% Vs 73%, Radial nerve-88% Vs 67%, Musculocutaneous nerve-88% Vs 64%,  $p < 0.001$ ), shown as in Figs. 5 and 6. Although significant proportions of patient had achieved complete sensory block at 6 min, 9 min, (2 min respectively in USG-NS Group. No difference was found in success rate of Sensory Block between USG-NS Group and USG Group at 30 min.

Complete motor block of all 4 nerves is significant in > 80% of patients within 15 min in the USG-NS Group compared to the USG Group. (Ulnar nerve-91% Vs 61%, Median nerve-88% Vs 64%, Radial nerve-85% Vs 52%, Musculocutaneous nerve-82% Vs 52%,  $p < 0.001$ ), shown in Fig. 7. The significant motor blockade was achieved in 6, 9, and 12 min in the USG-NS Group ( $p < 0.001$ ), also

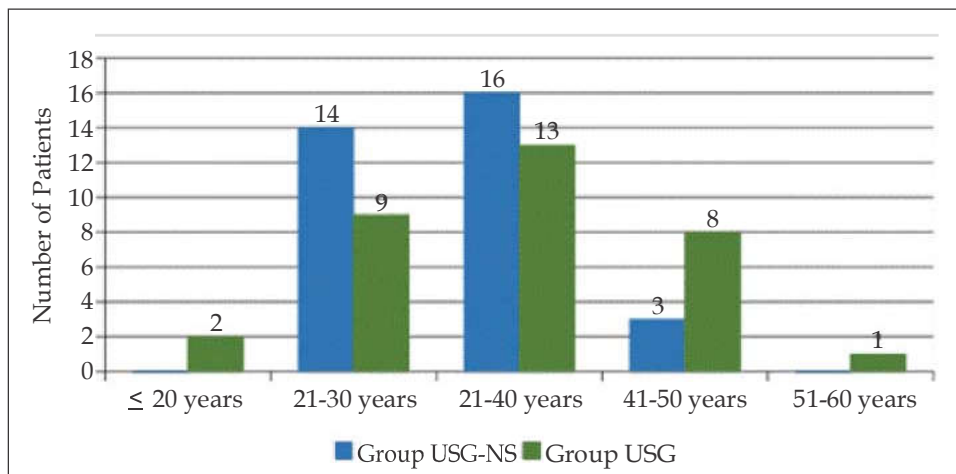


Fig. 4: Age

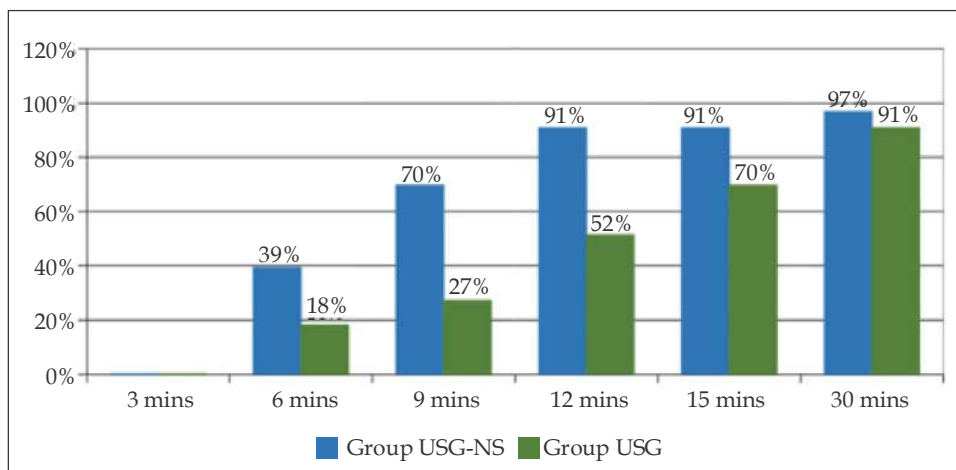


Fig. 5: Sensory Block

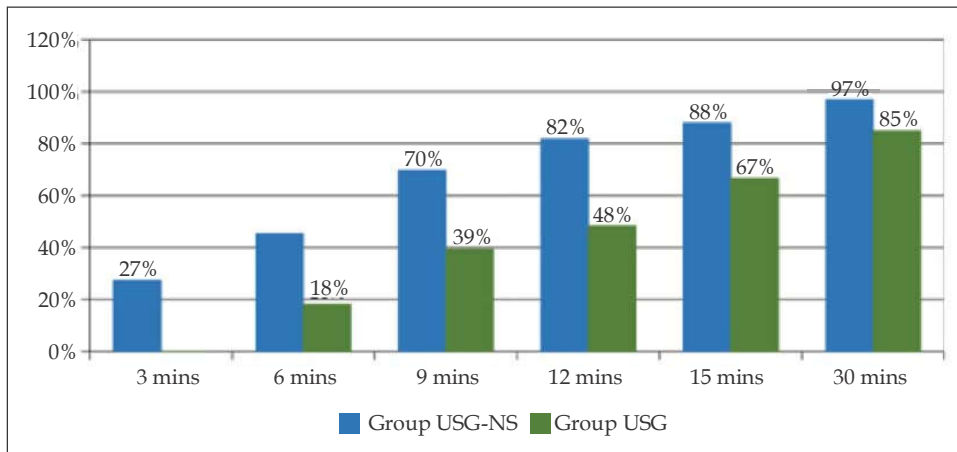
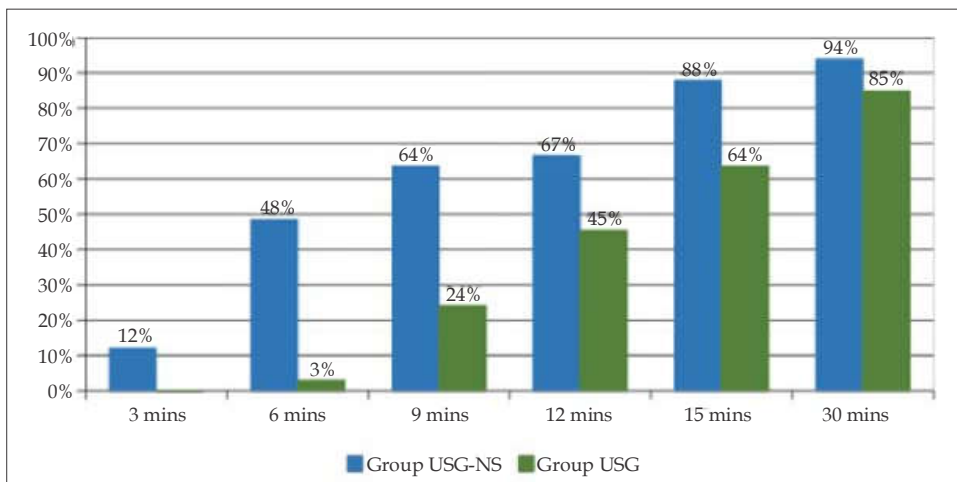
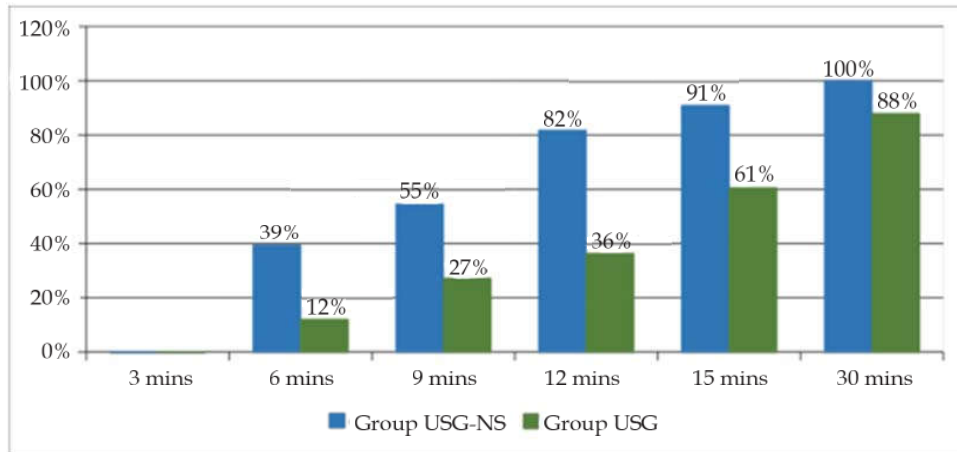
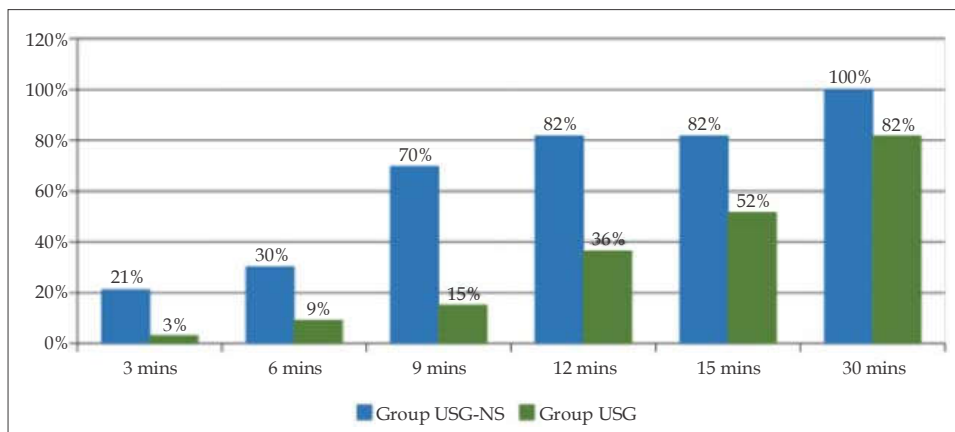
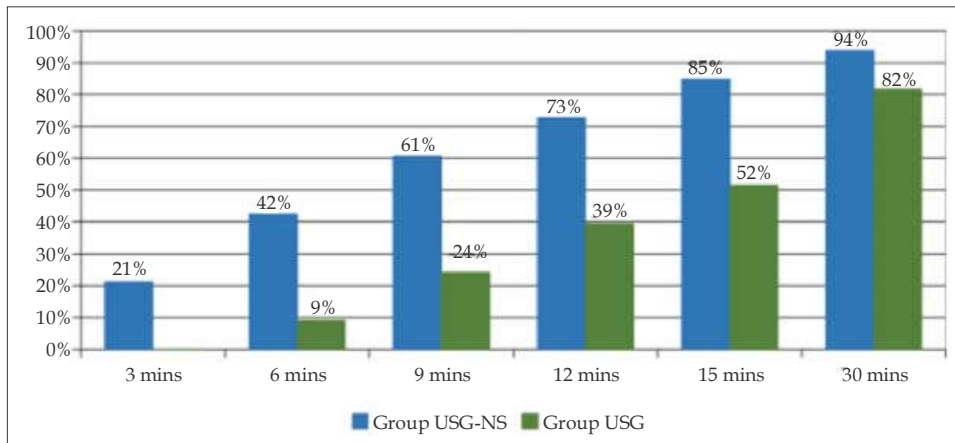
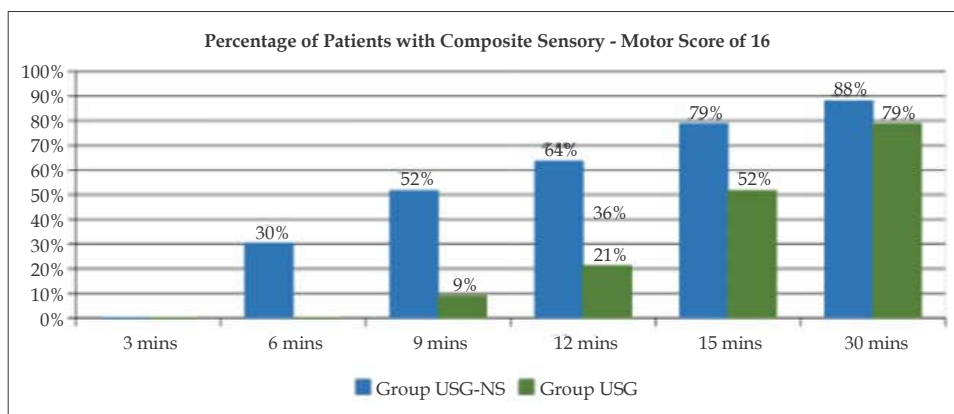


Fig. 6: Showing complete Sensory Block





**Figs. 7-10:** Complete Motor Block



**Fig. 11:** Combined Sensory and Motor Block

shown as in Figs. 8 and 9. However, there was no statistical difference found in success rate of motor block between USG-NS Group and USG Group in 30 min.

The Combined Sensory and Motor Block Score was significantly high in the USG-NS Group compared to the USG Group at 6, 9, 12 and 15 min time intervals ( $p < 0.001$ ). However, no significant difference in Sensory-motor Block was found between Two Groups at 3 min. ( $p = 0.329$ ), (Fig. 11).

## Discussion

In this study, we demonstrated that the USG-NS Group (ultrasound guidance with nerve stimulation) technique is associated with a faster onset of supraclavicular brachial plexus block than the USG Group. The success rate of both sensory and motor blockade of all four nerves was similar at 30 minutes in both groups. We also found that the performance time was slightly longer in the USG-NS Group than the USG Group. In Quechua Luo's study, the time needed to perform the block was about 1 minute longer than the traditional technique. Quechua Luo et al.<sup>7</sup> used the stimulating needle to target only the ulnar nerve. Our performance time was longer by 4 minutes as we targeted and stimulated both the ulnar nerve and the main neural cluster. The success rate of complete blockade was higher in our study in USG-NS Group than the rate that has been shown in a similar study by Quechua Luo et al.<sup>7</sup> Luo et al. modified the classical double injection technique by stimulating the ulnar nerve specifically so, that the ulnar nerve is not spared during the block. Arab et al.<sup>9</sup> showed that the combined sensory block success rate with triple injection technique was 72% as opposed to single-injection technique which had a success rate of 47%. In our study, the success rate of combined sensory and motor block was 90% with double injection technique Haleem et al.<sup>5</sup> used a landmark technique in which the subclavian artery was palpated to locate the injection site. We used state-of-the-art ultrasound technology in which supraclavicular block was performed after obtaining real-time images with high-resolution ultrasound. In addition, complications such as accidental intravascular injection and pneumothorax which are associated with landmark technique can be easily avoided with the use of ultrasound.<sup>15</sup> There were conflicting results with study by Beach et al.<sup>10</sup> which reported that there was no significant increase in the success rate with nerve stimulator technique. But Haleem et al.<sup>5</sup> showed that there is a strong association between

the pattern of motor response and the successful nerve block. In Beach's study,<sup>10</sup> local anesthetic was deposited under ultrasound guidance regardless of the motor response. Compared with Beach, in our USG-NS Group, blocks were given after identifying the brachial plexus with ultrasound guidance and then confirming the needle position by eliciting motor response. Quechua Luo et al.<sup>7</sup> used a modified double injection technique in which only ulnar nerve was identified with ultrasound guidance and muscle twitches were elicited in its distribution. Compared with Quechua, we identified both the ulnar nerve and main neural cluster with ultrasound and injected local anesthetic after obtaining appropriate motor responses. Thus, we were able to obtain a higher success rate of combined sensory-motor block of all the nerves mentioned above.

The success of the nerve block not only depends on the site of injection but also on the effective volume of local anesthetic injected.<sup>16</sup> Although a volume as high as 30 to 35 ml of local anesthetic solution is commonly used for landmark technique, we used 23 ml for our study. A minimum effective volume of 17 ml is sufficient to produce reliable sensory-motor blockade (with 95% confidence interval) determined by Song et al.<sup>11</sup> However, Song et al. determined this local anesthetic volume by single injection technique into corner pocket. We used a double injection technique, in which a total volume of 23 ml was used, of which half the volume was injected at corner pocket and the remaining volume into the main neural cluster. This allowed us to produce similar results under the same conditions. The ideal position of needle tip under ultrasound guidance is the connective tissue matrix between neural elements, determined by Franco et al.<sup>12</sup> Intraneural injection of local anesthetic resulted in higher transient postoperative numbness using double injection technique. Hence, extra fascial technique was determined safer by Bigeleisen et al.<sup>13</sup> The stimulation threshold of 0.4 mA for eliciting motor response in extraneural plane was determined by Bigeleisen et al. We used stimulating current in USG-NS Group, which allowed us to place the needle tip within the brachial plexus sheath but not into the neural cluster. Thus, neural injury and postoperative numbness were totally avoided in our study. The speed of onset of corner pocket supraclavicular brachial plexus block under ultrasound guidance as evaluated by Fredrickson et al.<sup>14</sup> was 22 minutes. In our study, with the modified double injection technique, complete blockade of all four nerves was possible as early as 15 minutes.

## Conclusion

In summary, combining ultrasound with nerve stimulator for supraclavicular brachial plexus block resulted in a complete sensory-motor blockade within 15 minutes after local anesthetic injection. Although the performance time was longer by 4 minutes in this group, higher success rate and early blockade were achievable than the technique in which ultrasound alone was used. The precise location of the brachial plexus with real-time ultrasound imaging and nerve stimulation with desired muscle twitches almost eliminated the possibilities of undesired complications such as inadvertent intravascular and intraneural injections and Horner's syndrome.

## References

1. Neal JM, Hebl JR, Gerancher JC. Brachial plexus anesthesia: Essentials of our current understanding. *Reg Anesth Pain Med* 2002 Jul-Aug;27(4):402-28.
2. Sadowski M, Tulaza B, Lysenko L. Renaissance of supraclavicular brachial plexus block. *Anesthesiol Intensive Ther* 2014 Jan-Mar;46(1):37-41.
3. De Andres J, Sala-Blanch X. Ultrasound in the practice of brachial plexus anesthesia. *Reg Anesth Pain Med* 2002 Jan-Feb;27(1):77-89.
4. Peterson MK, Millar FA, Sheppard DG. Ultrasound-guided nerve blocks. *Br J Anesth* 2002 May;88(5):621-24.
5. Haleem S, Siddiqui AK, Mowafi HA, Ismail SA, Ali QA. Brief reports: nerve stimulator evoked motor response predicting a successful supraclavicular brachial plexus block. *Anesth Analg*. 2010;110(6):1745-46.
6. Tran DQ, Dugani S, Correa JA, Dyachenko A, Alsenosy N, Finlayson RJ. Minimum effective volume of lidocaine for ultrasound-guided supraclavicular block. *Reg Anesth Pain Med*. 2011;36(5):466-69.
7. Quechua Luo, Weifeng Yao. Double-injection technique assisted by a nerve stimulator for ultrasound-guided supraclavicular brachial plexus block results in better distal sensory-motor block: A randomized controlled trial. *Eur J Anesthesiol* 2017 Mar;34(3):127-34.
8. Soares LG, Brull R, Lai J. Eight balls, corner pocket: The optimal needle position for the ultrasound-guided supraclavicular block. *Reg Anesth Pain Med* 2007 Jan-Feb;32(1):94-95.
9. Arab SA, Alharbi MK, Nada EM, Alrefai DA, Mowafi HA. Ultrasound-guided supraclavicular brachial plexus block: single versus triple injection technique for upper limb arteriovenous access surgery. *Anesth Analg*. 2014;118(5):1120-25.
10. Beach ML, Sites BD, Gallagher JD. Use of a nerve stimulator does not improve the efficacy of ultrasound-guided supraclavicular nerve blocks. *J Clin Anesth* 2006 Dec;18(8):580-84.
11. Song JG, Jeon DG, Kang BJ. Minimum effective volume of mepivacaine for the ultrasound-guided supraclavicular block. *Korean J Anesthesiol* 2013 Jul;65(1):37-41.
12. Franco CD. Connective tissues associated with peripheral nerves. *Reg Anesth Pain Med* 2012 Jul-Aug;37(4):363-65.
13. Bigeleisen PE, Moayeri N, Groen GJ. Extraneural versus intraneural stimulation thresholds during ultrasound-guided supraclavicular block. *Anesthesiology*. 2009;110(6):1235-43.
14. Fredrickson MJ, Patel A, Young S, Chinchawala S. Speed of onset of 'corner pocket supraclavicular' and infraclavicular ultrasound guided brachial plexus block: a randomised observer-blinded comparison. *Anaesthesia*. 2009;64(7):738-44.
15. Barrington MJ, Kluger R. Ultrasound guidance reduces the risk of local anesthetic systemic toxicity following peripheral nerve blockade. *Reg Anesth Pain Med* 2013;38:289-99.
16. Sainz Lopez J, Prat Vallribera A, Segui Pericas M. Ultrasound-guided supraclavicular brachial plexus block with small volumes of local anesthetic: Technical description and analysis of results. *Rev Esp Anesthesiol Reanim* 2006 Aug-Sep;53(7):400-40.