

Dermatological Manifestations of Dengue Fever in South Karnataka

Srinivas K¹, Nanda K²

How to cite this article:

Srinivas K, Nanda K. Dermatological Manifestations of Dengue Fever in South Karnataka. RFP Journal of Dermatology 2020; 5(1):13-16.

Author Affiliation:

¹Associate Professor,
Department of Dermatology,
Akash Institute of Medical,
Devan halli, Near Kempegouda,
International Airport,
Bangalore 562110, India.
²Assistant Professor,
Department of Biochemistry, ESI
Post Graduate Institute of Medical
Science and Research, Rajajinagar,
Bengaluru, Karnataka 560010, India.

Corresponding Author:

Nanda K, Assistant Professor,
Department of Biochemistry, ESI
Post Graduate Institute of Medical
Science and Research, Rajajinagar,
Bengaluru, Karnataka 560010, India.
E-mail: dr.ukm1991@gmail.com

Abstract

Background: Dengue fever (DF) is a viral replication which occurs in dendritic (Langerhans) cells of the skin as early target of infection. Hence 50% DF involves Dermatological Manifestation.

Methods: The Diagnosed DF has petechial or Maculopapular skin lesion was noted. Detailed clinical features, laboratory investigations were also recorded.

Results: Dermatological involvement of DF was 26(52%), had only cutaneous involvement, 11(22%) had muco-cutaneous involvement, 13(26%) had no Dermatological involvement. The distribution of rash was 21(42%) had generalised rash 17(34%) had Truncal 12(24%) had extremities. Rash with or without puritis was 30(60%) were with purities, 20(40%) without puritis.

Conclusion: As DF continues to be one of the commonest causes of acute febrile illness with involvement of skin and mucosa have significant morbidity and mortality. Hence involvement skin could be the early diagnostic value for DF to treat efficiently with all preventive measures.

Keyword: DF; DHF; Petachae; Elisa Igm; NSI antigen; Muco-cutaneous.

Introduction

It is rightly said that, skin is the window to within the body. Hence skin can provide important clues to systemic diseases; enabling the practitioner to make a tremendous contribution to the patient's care if cutaneous manifestations are in disorder can be identified. As dengue is an viral fever focuses on various Muco-cutaneous manifestation which becomes challenge to dermatologist apart from physician.

Dengue Fever (DF) is a severe Flu-like illness that affects infant's, children, adolescent and adults. The incubation period of DF after Mosquito bite is between 2 to 8 days. The clinical features vary according to the age of patient. Infants and young children usually have only a non-specific febrile illness with rash that is hard to distinguish from other viral illness.¹ The temperature rapidly >39°C

and lasts approximately 5 to 6 days and sometimes biphasic. During the febrile period the patient may experience severe headache, retro-orbital pain, myalgia, arthralgia, nausea and/or vomiting. More than 50% of infected patients report rash during this period that initially macular or macula-popular and becomes diffusely erythematous.² Minor hemorrhagic manifestations such as petechiae, epistaxis and gingival bleeding occur in some patients.

As there are four serotypes of DF (DEN 1-4). Dengue virus is a single stranded RNA virus transmitted mainly through mosquito *Aedes-aegypti*, It is reported that, viral replication, which occurs primarily in macrophages, although dendritic cells (Langerhans cells) in skin may be the early targeted of infection.³ Dengue virus may directly infect the skin.⁴ It was also concluded that, absence of direct viral involvement or immune complexes in the skin lesions could be due to viral

host interaction inducing release of un-identified chemical mediators in the skin and the rash has nothing to do with the direct viral invasion or with the presence of immune complexes⁵ presence of Dengue virus can cause DHF (Dengue Haemorrhagic Fever), Infections of DSS.⁶ Hence various manifestation were evaluated.

Material and Method

50 patients admitted at emergency ward at Dr B. R. Ambedkar Medical college hospital Kondgondan halli, Bangalore 560045, (Karnataka) were studied.

Inclusive Criteria: The patients have positive dengue fever test, above 16 year to 60 years, having skin rash were included in the study.

Exclusive Criteria: The patient had negative dengue fever, urticaria with drugs reactions, food allergy or Immune compromised patients. The patients below 16 year above 70 years were excluded from the study.

Methods: The clinical presentations of acute febrile illness, progressive thrombocytopenia, elevated hepatic transaminase and presence of

detectable dengue Igm and detectable Virus-expressed soluble man-structural protien1 (NS1) by means of enzyme linked immune sorbent assay (Elisa) (panbio, Dengue duo cassette) with other sereologics being negative and blood cultures sterile or sero conversion of cavelesent sera, were diagnosed to have DF.

The dengue fever patients having petechial and/or morbilliform skin lesions. Detailed clinical features, laboratory investigations, major organ involvement treatment and outcome were also recorded. The duration of study was April 2008–October 2010.

Statistical Analysis: Various dermatological involvements and distribution of rash with or without pruritis were classified with percentage. The ratio of male and female was 2:1.

Observation and Results

Study of dermatological involvement in dengue fever patients– 26(52%) patient only cutaneous involvement, 11(22%) had muco-cutaneous involvement 13(26%) patients had no dermatological involvement.

Table 1: Dermatological Involvement in Dengue Fever Patients.
No of Patients: 50

Sl No.	Particular	No of Patients	Percentage
1	only cutaneous involvement	26	52
2	Muco- cutaneous involvement	11	22
3	No dermatological involvement	13	26

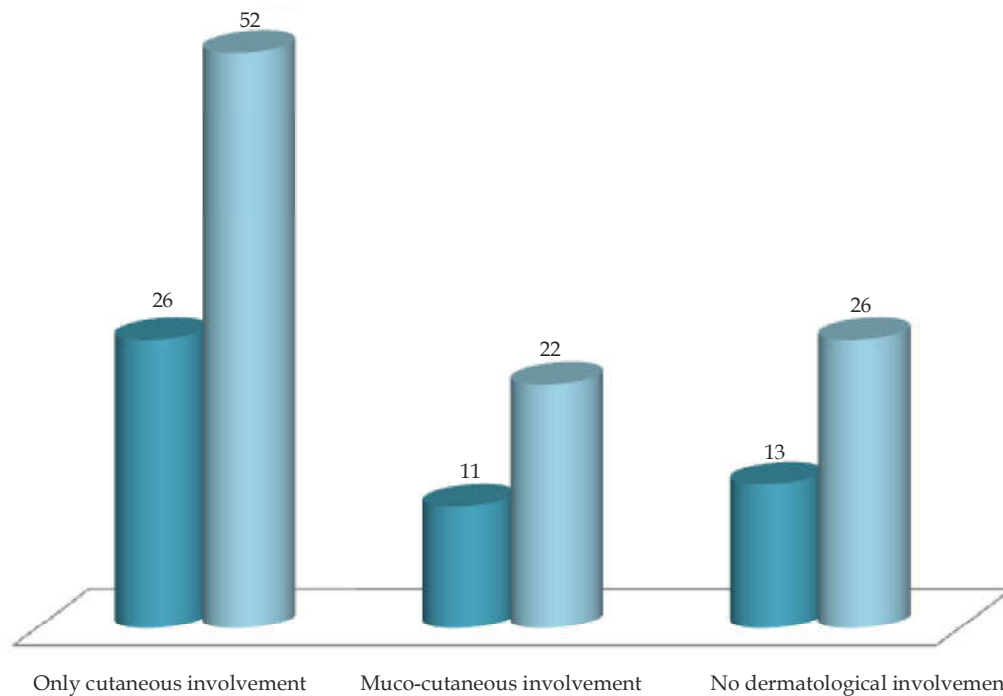
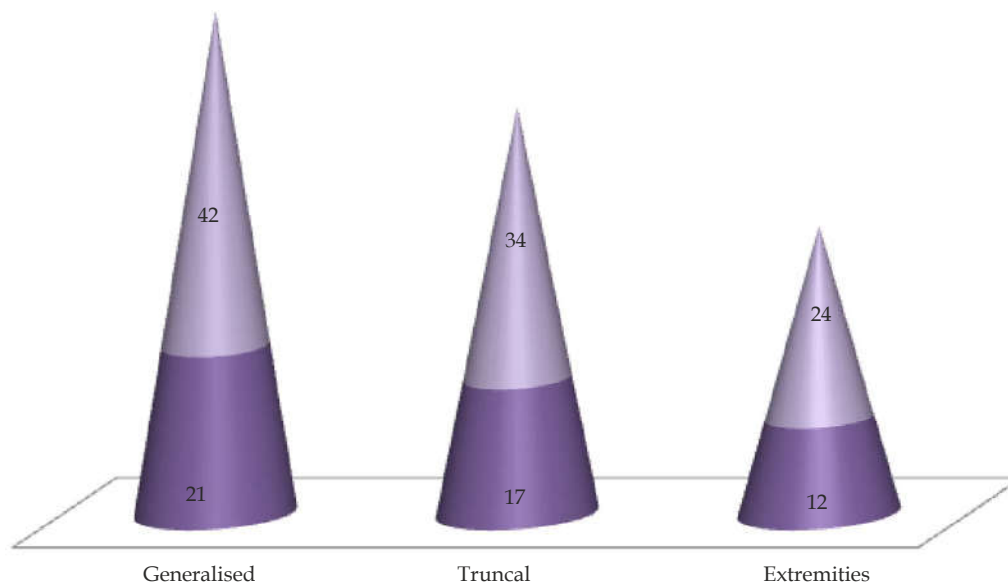


Table 2: Distribution of Rash in Patients with Dengue Fever.

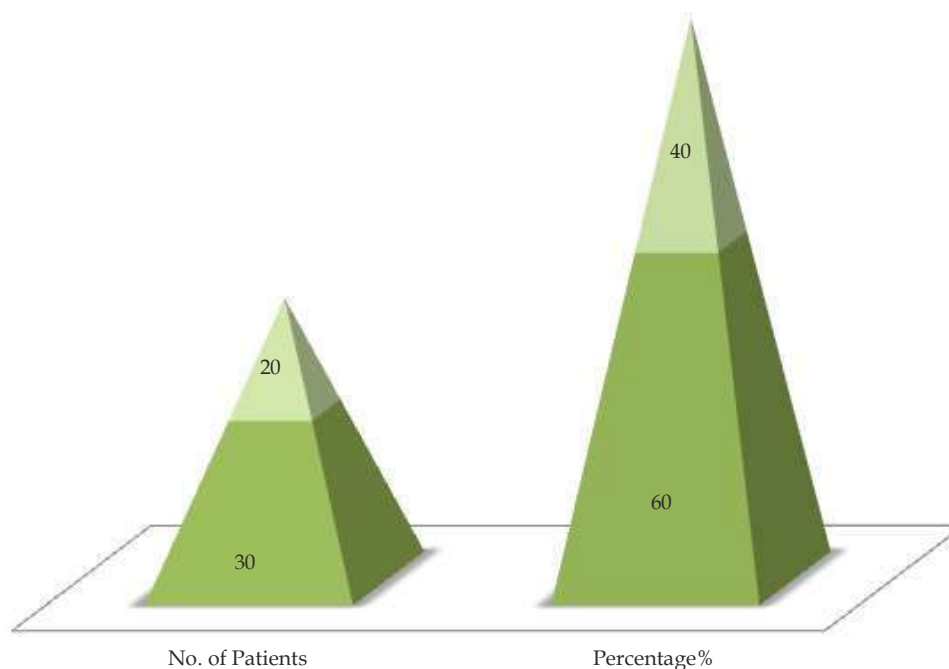
No of Patients: 50

Sl No.	Particular	No of Patients	Percentage %
1	Generalised	21	42
2	Truncal	17	34
3	Extremities	12	24

**Table 3:** Rash with or without Pruritis in Patients with Dengue Fever.

No of Patients: 50

Sl No.	Particular	No of Patients	Percentage %
1	with pruritis	30	60
2	without pruritis	20	40



Study of distribution of Rash in patients with dengue fever 21 (42%) had generalised rash 17(34%) had truncal 12 (24%) had prurities on extremities.

Study of rash with/without pruritis in dengue fever patients 30 (60%) had rash with pruritis 20 (40%) had rash without pruritis.

Discussion

In the present study of Dermatological manifestation in DF 26(52%) patient had cutaneous involvement 11(22%) had muco-cutaneous involvement 13(26%) had no dermatological involvement (Table 1). The distribution of rash in DF was 21(42%) had generated rash 17(34%) had truncal 12(24%) had pruritis on extremities (Table 2). Study of ash with or without pruritis was 30(60%) had rash with prurities and 20(40%) had rash without pruritis (Table 3). These findings were more or less in agreement with previous studies⁷⁻⁹.

Moreover Tourniquet test is performed by inflating a blood pressure cuff on the upper aspect of arm to a point midway between systolic and diastolic Blood pressure for five minutes. The test is considered positive when >20 petechae.2.5 cm² are observed. This test certainly indicates involvement has dermatological manifestation has significant role in DF¹⁰. As DF itself is a viral infection commonly affects conjunctival and sclera mucosa small vesicles on soft palate erythema and crusting of lips and tongue, such involvement on mucosal membrane may be up to 50% was also observed¹¹. It was interesting to note that, in the local skin epithelium was not involved rather small blood vessels and endothelium were involved with oedema. In addition to the skin test for dengue virus test by immuno fluorescence was negative. The skin was prominently involved due to intra dermal haemorrhage or petechae. Otherwise involvement skin and skin appendages have no etiological signs rather than diagnostic value, due to involvement of sub-mucosal or sub-dermal capillaries.

Summary and Conclusion

The present study of involvement of dermatological manifestation in DF and related complication will be certainly helpful to Dermatologist and physician to diagnose DF and treat efficiently but these study further demands histo-pathological, virological, nutritional, genetic, bio-chemical studies because exact pathogenesis of DF and its involvement in dermatomes is still unclear.

The Research paper was approved by ethical committee of Ambedkar Medical College, Kondgondan halli Bangalore 45 (Karnataka).

Conflict of Interest: No

Funding: No.

References

1. Ligan BL-Dengue fever and Dengue haemorrhagic fever. A review of history transmission, treatment and prevention. *Semin Paediatr Infect Dis.* 2004;16: 60-5.
2. World Health Organisation, Dengue fever in Indonesia. Available from <http://www.int/csr/don20040226a/en/index.html>. Accessed on 22-03-2020.
3. Wu. SJ, Grouard-vogel a-Human skin langerhans cells are targets of dengue infection. *Nat. Med.* 2000;6:816-20.
4. Bhamarapravati N-pathology and pathogenesis of DHF. New Delhi-WHO meeting 1980 (Google scholar).
5. De Andino RM, Botet MV,-The absence of Dengue virus in the skin lesions of Dengue fever *Int. J. Dermatol.* 1985;24:48-5.
6. WHO Dengue haemorrhagic fever diagnosis, treatment, prevention and control 2nd edition Geneva WHO. 1997 (Google scholar).
7. Mitra S Gautam J-clinical score to differentiate scrub typhus and dengue. A tool to differentiate scrub typhus and dengue. *J. Glob Infect Dis.* 2017;9(1):12-7.
8. Simman SP CP Farrar JJ-Muco-cutaneous manifestations of dengue fever. *Ind. J of dermatol* 2010;55(1):79-81.
9. Hung HW, Tseng HC-clinical significance of skin rash in dengue fever. A focus on discomfort, complications and disease outcome Asian Pacific C. *J Trop. Med.* 2016;9(7):713-8.
10. Pincus IB, Grossman MD- The exanthema of dengue fever. Clinical feature of two US tourists travelling abroad. *J Am Acad. Dermatol* 2008;58:308-16.
11. Sanford JP, Harrison's principle of Internal Medicine. 12th edition vol. II Geneva New York MC Graw Hill. 1986; 735-38.