

Role of Serial 2D Echocardiogram with Contrast and Confirmative Diagnosis by Cardiac MRI, Rare Case of Myocardial Hematoma in Covid 19 Patient

Naresh Sen¹, Sonal Tanwar²

How to cite this article:

Naresh Sen, Sonal Tanwar/Role of Serial 2D Echocardiogram with Contrast and Confirmative Diagnosis by Cardiac MRI, Rare Case of Myocardial Hematoma in Covid 19 Patient/J Cardiovasc Med Surg.2021;7(4): 87-90-.

Abstract

World known pandemic severe acute respiratory syndrome SARS Cov2 viral infection or called as corona virus disease (COVID 19), initially we faced as respiratory insufficiency but later on multisystemic inflammatory disorders were reported. Cardiac emergencies or cardiovascular morbidities with mortality were accessed across the globe during COVID 19 pandemic era. Data revealed that SARS Cov2 affected on heart by both direct or indirect pathway which leads to acute myocarditis, myocardial injury/infarct, heart failure, thrombosis and arrhythmias. Here we are presenting a rare case as hematoma in myocardium called as intramyocardial dissecting hematoma. Non invasive technology like 2 dimensional echocardiography and magnetic resonance imaging (MRI) are diagnostic tools to prevent mortality in cardiology field and avoid further complication.

Keywords: SARS Cov2; Intramyocardial hematoma; Echocardiogram; Cardiac MRI.

Introduction

SARS Cov2 infection affect the heart by the both direct and indirect way and resulting as endothelial dysfunction, platelets aggregation, thrombosis, acute myocardial injury and infarct followed by arrhythmias as per reported cases in last 2 years.¹⁻² As per COVID 19 induced severe myocarditis and

injury can cause myocardial rupture and make responsible for thrombus or hematoma in mural myocardium called as intramyocardial hematoma (IMH). Intramyocardial dissecting hematoma (IDH) is an unfavorable rare form of myocardial rupture which can lead to acute myocardial injury or infarction.⁴

Case Report

A 45 year old north Indian male with grade 1 central obesity, smoker, euglycemic, normotensive was admitted to the emergency department with complaints of chest pain, general malaise last 2 days. He reported himself as 5 days fever history with RT PCR positive for SARS Cov2 infection. At initial presentation, his vital signs were 109 bpm pulse

Author's Affiliation: ¹Consultant Cardiology, Metro Mas Heart Hospital, Jaipur 302020, Rajasthan, India. ²Associate Preventive Cardiology, BYN Hospital Bhiwani 127021, Haryana, India.

Corresponding Author: Naresh Sen, Consultant Cardiology, Metro Mas Heart Hospital, Jaipur 302020, Rajasthan, India.

E-mail: drnaresh.sen@gmail.com

Received on: 30.12.2021

Accepted on: 01.02.2022

rate, 129/83 mm Hg blood pressure, 90% oxygen saturation, and 99°F of axillary temperature with random blood sugar 112 mg/dl. On examination jugular venous pressure was in normal range, no cyanosis and lymphadenopathy, cardiovascular examination revealed normal first and second heart sounds, without added heart sounds and murmurs. Fine basal rales were heard in both lungs.

As per emergency protocol electrocardiogram was taken which revealed sinus tachycardia and ST elevation in V3, V4, V5 and V6 with T wave inversion (Fig. 1). 2D echocardiogram was performed immediately which showed dyskinetic apex and akinetic apical septum and apical anterior wall with moderate left ventricular systolic dysfunction on the basis of left ventricular ejection fraction around 35-40%. (Fig. 2) According to 4 chamber view of echo we accessed the thrombotic mass with pulsatile cavity at the apex of LV, subsequently color doppler showed no flow within that structure with systolic expansion. There was no evidence of trauma, no evidence of papillary muscle rupture and pericardial effusion. As per the lab data suggest slightly high value of troponin I as a cardiac bio marker, raised D-dimer value, raised CRP level (78 mg/L) and IL-6 (212 pg / ml). HRCT chest revealed as high score 19 with bilateral SARS Cov2 infiltrations.

He was shifted to intensive coronary care unit with prompt conservative medical treatment of delayed acute coronary syndrome on antiplatelets with subcutaneous anticoagulant injection enoxaparin 0.6ml, statin, ACE inhibitor, antianginal, anti-

viral injection Remdesibir, monoclonal antibody injection Tocilizumab and injection paracetamol and pantoprazole with levosulpiride.³ After shifting the ICCU we noticed that one episode of ventricular tachycardia which was reverted pharmacologically by injection lignocaine 2ml intravenously with the help of injection iv magnesium 2ml followed by low dose of amiodarone 8 hourly. ABG report was in normal limit but there was hypokalemia and low level of serum magnesium which were corrected timely in ICU.

Contrast echocardiogram was performed to diagnose and rule out of malignancy which revealed pulsatile thrombus with thin endocardium boundary with separate entity (Fig. 2B, C) and Cardiac MRI showed as confirmative diagnosis and slight extension of intramyocardial hematoma (fig. 3). Coronary invasive angiogram was performed which revealed normal coronaries with mild left ventricular dysfunction (fig. 4).

Serial echocardiogram was performed three times in duration of 15 days in hospital and another three serial echocardiograms were performed with one-time Cardiac MRI for thrombus size reduction and improving left ventricular function during follow up of 6 months on oral new anticoagulant therapy with maintained INR. After 6 months of follow up patients became free from dyspnea and chest heaviness and final 2D Echocardiogram showed thick scarred in apical myocardium without any significant hematoma but jerky movement was accessed, however left ventricular systolic function became subnormal around LVEF -55%.

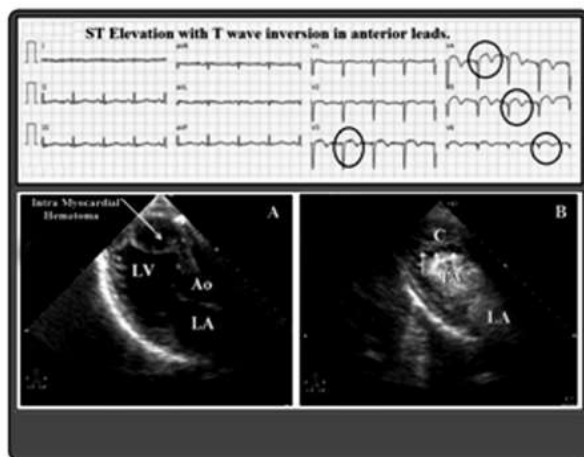


Fig. 1: ECG-ST elevation V3-V6. **Fig. 2:** Echo LV Apical intramyocardial hematoma A-2D Echo, B-2D Contrast Echo.

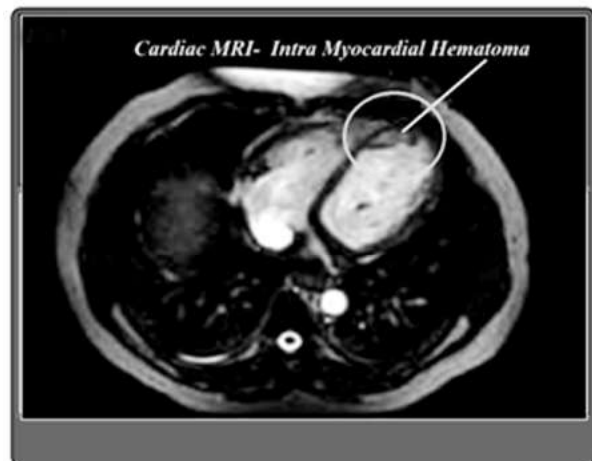

Fig. 3: Cardiac MRI- IMH.

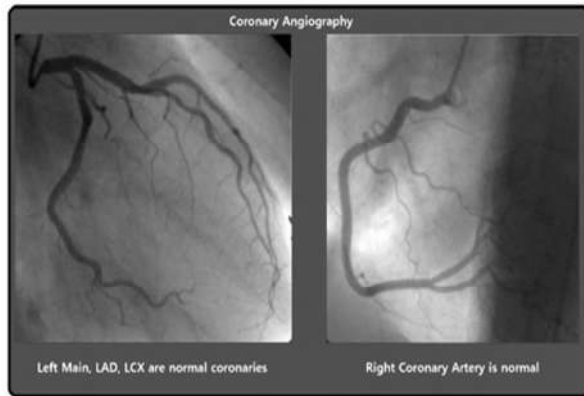


Fig. 4: Coronary Angiogram- normal coronary arteries.

Discussion

SARS Cov2 infection is a pandemic declared by WHO in early month of 2020 as corona virus disease (COVID 19) which was diagnosed first in Wuhan, China in December 2019. During first wave of COVID 19 we faced with severe acute respiratory insufficiency and respiratory failure with common symptoms of high grade fever, shortness of breath and loss of sensations but later on we accessed the different symptoms to related with multi systems of human body. SARS Cov2 viral infection became responsible for multi systemic inflammation followed by multi organ failure.¹⁻³ As per our specialty we are facing different kinds of cardiac emergencies in COVID 19 era since last 2 years like acute coronary syndrome, myocarditis, myocardial infarction, heart failure and arrhythmias.¹⁻² Here we are presenting our rare case in form of unfavorable condition as intramyocardial hematoma in this young Indian fellow.

As simple as that SARS Cov2 enter to the body through lungs and attach with angiotensin converting enzyme ACE 2 receptor followed by cell entry and lysed of protein coating leading to start replications. More viral load affects the immune system and inflammatory process which may changes in the endothelium resulting as proinflammation, pro proliferation and pro-fibrosis. Its effects on heart through microvascular and macrovascular changing way which resulting inflammation, endothelial changes cause acute myocarditis, injury and infarction without obstruction of coronary arteries.¹⁻³ Here, in this patient first myocarditis was developed and after that increased permeability and spasm of myocardial vessels which lead to rupture and finally thrombus formation occurred. SARS Cov2 viral load is responsible for high thrombotic burden

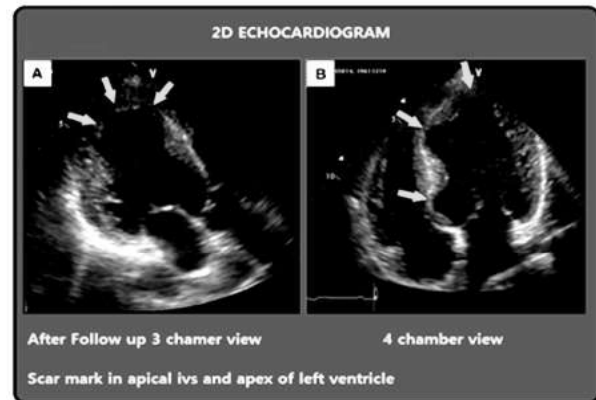


Fig. 5: 2D Echo follow up after 6 months Scar present apex and apical septum of left ventricle.

along with injury extension of spiral myocardial fibers creating a neo cavitation limited by the myocardium cause regional ST segment elevation in ECG⁴⁻⁵ and akinesia of apex and apical segment of septum and poor LV systolic function or reduced ejection fraction.⁵⁻⁶ On the basis of reality with strong mechanism of intramyocardial hemorrhage have no sufficient space to extend easily, that's why it may dissect the myocardium or may expand by rupturing adjacent myocardial fibers of closer structures which might be cause of life-threatening complication like ventricular arrhythmia and sudden cardiac death.⁴⁻⁸ Data revealed that diagnosis of intramyocardial dissecting hematoma has commonly been cleared during surgery or post-mortem and some time by echocardiography or cardiac MRI at advanced cardiac center.⁷⁻⁸

Fortunately, in this case we could make diagnosed early and became happy to save the life of this patient with the helping of previous literatures or studies has been published regarding intramyocardial hematoma. Routinely in cardiac practice of acute coronary syndrome presenting as chest pain with ST segment elevation, shifting to Cath lab, coronary angiogram followed by stenting or medication and cardiac bypass surgery depend on indications. But in normal coronaries during angiogram and missed the diagnosis by the routine 2D echocardiography as LV apical thrombus, apical hypertrophy, ventricular trabeculations and small apical aneurysm.^{4,8} After that mostly physician's advice is being notice about medical management. But in reality, early diagnosis is mandatory by advance 2D myocardial contrast echocardiogram followed by Cardiac MRI if possible, to pick the intramyocardial hematoma. Finally, we can avoid the major adverse consequences of IMH like large

dissection, life threatening arrhythmias and death with the help of advance contrast echocardiogram and 2D serial echo imaging and cardiac MRI.^{7,8} We can save the life of this type of patients in cardiac emergencies by prompt diagnosis with standard medical management or timebound cardiac surgery if large extended with pseudoaneurysm or extensive dissecting intramyocardial hematoma on compromised hemodynamic level.

Conclusion

Intramyocardial thrombus or hematoma is rare but unfavorable cardiac emergency which might be horrible without prompt diagnosis and management. 2D Contrast echocardiogram with serial imaging and Cardiac MRI are useful non-invasive tools for early diagnosis to avoid further extension or dissection with expansion and to prevent further complication and mortality.

Acknowledgement

We would like to give thanks to our team members and diagnostic team of MRI and Cath lab staff for contribution to save the patient's life.

References

1. Farshidfar F, Koleini N, Ardehali H. Cardiovascular complications of COVID-19. *JCI Insight*. 2021 Jul 8;6(13):e148980. doi: 10.1172/jci.insight.148980. PMID: 34061779; PMCID: PMC8410051.
2. Luo J, Zhu X, Jian J, Chen X, Yin K. Cardiovascular disease in patients with COVID-19: evidence from cardiovascular pathology to treatment. *Acta Biochim Biophys Sin (Shanghai)*. 2021 Mar 2;53(3):273-282. doi: 10.1093/abbs/gmaa176. PMID: 33428706; PMCID: PMC7929476.
3. Hendren NS, Drazner MH, Bozkurt B, Cooper LT Jr. Description and Proposed Management of the Acute COVID-19 Cardiovascular Syndrome. *Circulation*. 2020 Jun 9;141(23):1903-1914. doi: 10.1161/CIRCULATIONAHA.120.047349. Epub 2020 Apr 16. PMID: 32297796; PMCID: PMC7314493.
4. Allende NG, Santos R, Sokn FJ, Merino SA, Accastello GM, Medina JC, Isquierdo IN, Rapallo CA. Unusual presentations of cardiac rupture during COVID-19 pandemic. *Echocardiography*. 2021 Mar;38(3):469-472. doi: 10.1111/echo.15006. Epub 2021 Feb 18. PMID: 33599346; PMCID: PMC8014092.
5. Lechner I, Reindl M, Tiller C, Holzknacht M, Troger F, Fink P, Mayr A, Klug G, Bauer A, Metzler B, Reinstadler SJ. Impact of COVID-19 pandemic restrictions on ST-elevation myocardial infarction: a cardiac magnetic resonance imaging study. *Eur Heart J*. 2021 Oct 11;ehab621. doi: 10.1093/eurheartj/ehab621. Epub ahead of print. PMID: 34632491; PMCID: PMC8524546.
6. De Stefano D, Parillo M, Garipoli A, Beomonte Zobel B. Imaging findings in a case of myo-pericarditis associated with SARS CoV-2 disease. *J Cardiol Cases*. 2021 Nov;24(5):210-214. doi: 10.1016/j.jccase.2021.07.006. Epub 2021 Aug 3. PMID: 34367382; PMCID: PMC8328569.
7. Rezaei-Kalantari K, Saedi S, Alizadeasl A, Naghshbandi M. Left ventricular intramyocardial dissection after myocardial infarction. *Echocardiography*. 2020 Dec;37(12):2160-2162. doi: 10.1111/echo.14843. Epub 2020 Nov 5. PMID: 33155293.
8. Vargas-Barrón J, Roldán FJ, Romero-Cárdenas A, Molina-Carrión M, Vázquez-Antona CA, Zabalgoitia M, Martínez Rios MA, Pérez JE. Dissecting intramyocardial hematoma: clinical presentation, pathophysiology, outcomes and delineation by echocardiography. *Echocardiography*. 2009 Mar;26(3):254-61. doi: 10.1111/j.1540-8175.2008.00804.x. Epub 2008 Nov 1. PMID: 19017318.

