

Head and Neck Follicular Dendritic Cell Sarcoma: Report of Five Cases

Archana Lakshmanan¹, Annapurneswari Subramanyan²

How to cite this article:

Archana Lakshmanan, Annapurneswari Subramanyan. Head and Neck Follicular Dendritic Cell Sarcoma: Report of Five Cases. *Ind J Pathol: Res Pract.* 2023;12(4) 137-141.

Abstract

Follicular dendritic cells (FDC) are accessory cells which play a major role in antigen presentation. The neoplasms arising from FDC are very rare and have been reported in both nodal and extra nodal locations. We report 5 cases of follicular dendritic cell sarcomas arising in the head and neck region. Three were nodal and two cases were extra nodal in location. The patients age ranged from 34-46 years. There were 3 males and 2 females. Two cases had multiple recurrences. Surgery was the main stay of treatment with some of them received adjuvant chemotherapy and radiotherapy. They showed varied morphology with spindle, epithelioid and pleomorphic appearances. Although these neoplasms are extremely rare, it is important to consider them in the differentials, thereby preventing misdiagnosis.

Keywords: Dendritic cells; Sarcoma; Follicular; Antigen presentation.

INTRODUCTION

Follicular dendritic cells (FDC) are a component of the dendritic reticulum/histiocytic cells family. They present antigens to the B cells in the follicular centres of lymph nodes, thereby playing an important role in humoral immune response. They form a tight meshwork within primary and secondary follicles and are proposed to be of mesenchymal origin.¹ The tumors that arise from these cells are Follicular dendritic cell sarcomas

(FDCS). They have been reported in both nodal and extra nodal locations. FDCS is often misdiagnosed especially in extra nodal locations due to lack of awareness about this entity and is often missed in the differentials of spindle cell neoplasms.

We are reporting five cases of FDCS involving the head and neck region and reviewed its literature including clinical features, histopathological and immunophenotypic characteristics, differential diagnosis, treatment and clinical behaviour of these neoplasms.

CLINICAL FINDINGS

CASE 1:

Patient is a 37-year-old gentleman who presented with tonsillar enlargement for which he was operated elsewhere and reported as poorly differentiated squamous cell carcinoma. He came to our institution for further treatment. The outside

Author Affiliation: ¹Consultant, ²Senior Consultant, Department of Histopathology, Apollo Cancer Institute, Chennai 600035, Tamil Nadu, India.

Corresponding Author: Archana Lakshmanan, Consultant, Department of Histopathology, Apollo Cancer Institute, Chennai 600035, Tamil Nadu, India.

E-mail: mrithulaarchana@gmail.com

Received on: 23.10.2023

Accepted on: 30.11.2023

slides were reviewed here and reported as follicular dendritic cell sarcoma. Post-operative PETCT did not reveal any residual disease. He received adjuvant radiotherapy. He is disease free as on 3 years follow-up.

CASE 2

Patient is a 44-year-old gentleman with complaints of right neck swelling of 15 days duration. There were no B symptoms. Excision biopsy was done elsewhere and reported as non-Hodgkin lymphoma. He was referred to our institution for further treatment. The outside slides and blocks upon review revealed follicular dendritic cell sarcoma. He received chemotherapy (Adriamycin, Vincristine, Cyclophosphamide and prednisone) He did not develop recurrence on 4 years follow-up, after which he was lost to follow up.

CASE 3

Patient is a 46-year-old gentle man who presented with headache and difficulty in breathing in 2005. Imaging revealed a nasopharyngeal mass. Biopsy of the same showed follicular dendritic cell sarcoma. He received adjuvant Chemotherapy and radiotherapy. He developed recurrence in 2007 and he was treated with re-radiation. He developed second recurrence in 2008 for which he underwent endoscopic nasopharyngectomy and bilateral medial maxillectomy. The patient was disease free for a year and was lost to follow-up there after.

CASE 4

Patient is a 36-year-old woman with complaints of neck swelling and no other symptoms. USG neck was suggestive of Tuberculosis. Biopsy of the same has been reported outside as leiomyosarcoma. The blocks upon review in our institute, a diagnosis of Follicular dendritic cell sarcoma was rendered. PETCT showed mass confined to the cervical nodal region. Hence, she was taken up for surgery and the entire lesion was excised into to. She developed first recurrence a year later and she was treated with chemotherapy. She had second recurrence within 8 months, for which she received radiotherapy. She developed third and fourth recurrences 15 months and 4 years later, for which re-excision had been done. Follow up PETCT on fourth recurrence revealed only local recurrence with no distal metastases. She is disease free as of 14 months post fourth recurrence.

CASE 5

Patient is a 34-year-old woman who presented with right side neck swelling of eight months duration. Biopsy was done and reported elsewhere as metastatic poorly differentiated carcinoma. Patient was referred to our institute for further management. The outside blocks were reviewed and reported as FDCCS. PET CT revealed a right level II/III nodal mass with no other activity elsewhere in the body. Excision of the mass was done with negative margins. She did not receive any adjuvant treatment. She is disease free as on one year follow up.

MATERIAL & METHODS

Histopathological analysis was done formalin fixed paraffin embedded tissue. Hematoxylin and eosin stain was done on 4-micron thin sections. Immunophenotyping was done Ventana automated immunostainer Benchmark XT. The panel of antibodies differed with each case. The list of antibodies that were added were CK, Vimentin, SMA, Desmin, S 100, CD34, CD21, CD23, CD1a, LCA, CD3, CD20, CD30, Ki67 etc. Ethics committee approval has been obtained from institutional review board. Formal written consent was not required and waiver has been obtained from the ethics committee.

RESULTS - HISTOMORPHOLOGIC AND IMMUNOPHENOTYPIC FINDINGS

Three cases showed classical sarcomatoid appearance with bundles and fascicles of spindle cells with mild nuclear pleomorphism. Sprinkling of lymphocytes were noted in all the cases. Tumor giant cells were noted in two cases. Focal epithelioid appearance was noted in one case. Fourth case had predominant epithelioid morphology. The fifth case from supraclavicular lymph node was classical spindled morphology with initial presentation. The cells became more epithelioid and pleomorphic with each recurrence. Marked pleomorphism was noted in the fourth recurrence with elevated mitotic activity resembling pleomorphic sarcoma (Fig. 1). The proliferation index increased from 15% at initial presentation to around 70% at the fourth recurrence. The MIB 1 index in rest of the cases ranged from 2% to 15%. All the cases were positive CD21 and CD23 with the absence of S 100 and CD1a. CD68 and LCA were variably expressed in all the cases (Fig. 2).

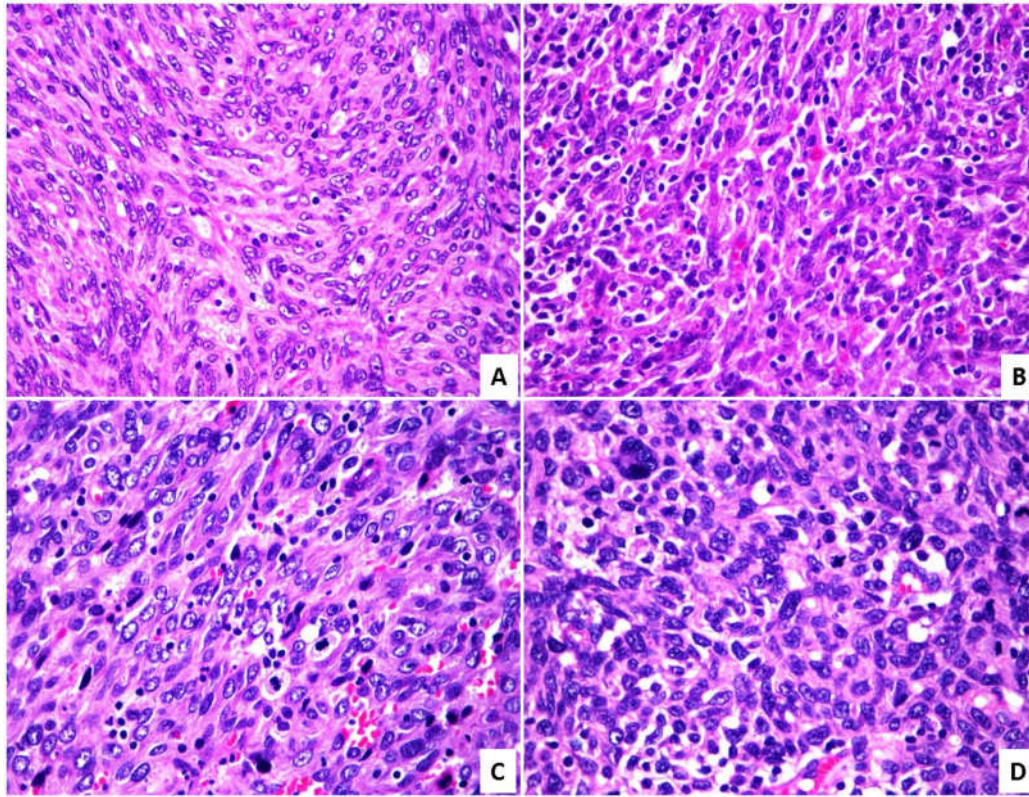


Fig. 1: A - (H&E-400X) Initial presentation, B - (H&E-400X) First recurrence, C - (H&E-400X) second recurrence, D - (H&E-400X) third recurrence.

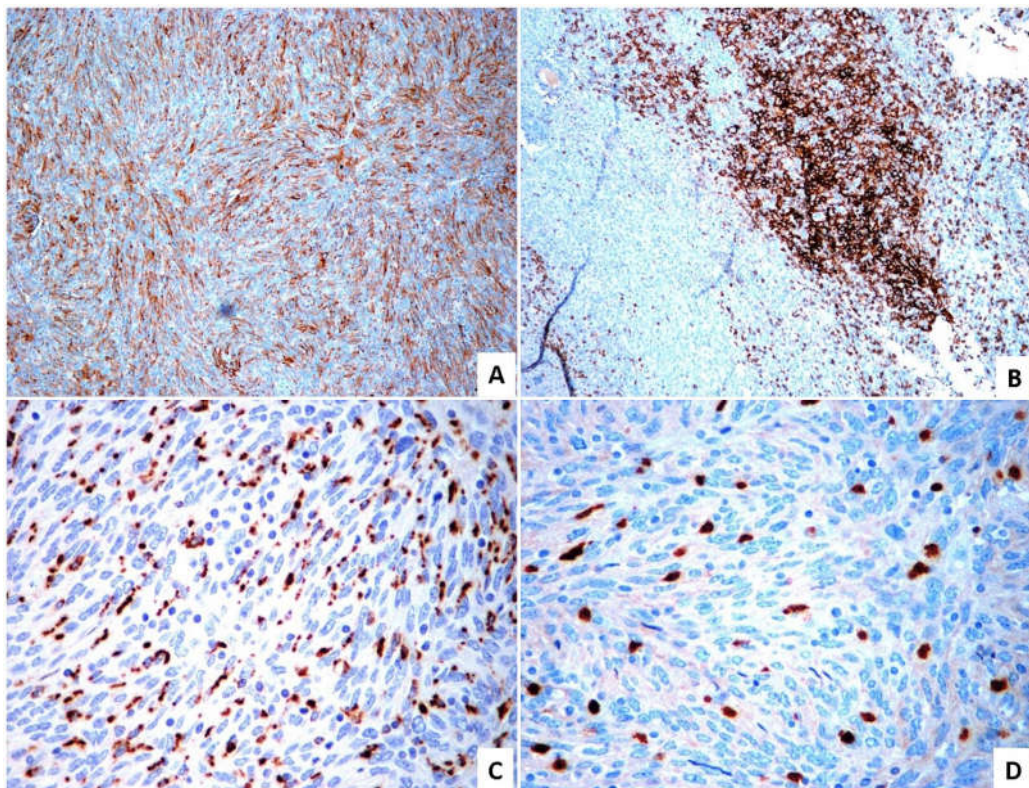


Fig. 2: The neoplastic cells are positive for CD23 (A-100X), CD21 (B-100X), CD68 (C-400X) and negative for S100 (D-400X)

DISCUSSION

Monda *et al* reported the sentinel case of FDCC in 1985.² There are many case reports and case series that have been published in the literature thereafter. Their frequency must be understated, as they are often misdiagnosed as other sarcomas especially in extra nodal location. Sayginetal reported the largest pooled analysis of 343 cases of FDCC.³ They have been reported in both nodal and extra nodal locations. Cervical lymph nodes are the most common nodal location. The extra nodal sites reported are tonsils, nasopharynx, oral cavity, pancreas, liver, spleen, gastrointestinal tract, omentum, lung, breasts, skin, mediastinum, testis and peritoneum. It has been reported in wide age range with mean age of 50 years. There is no gender predilection except IMT like variant which is reported more in women.⁴

The etiopathogenesis is unclear. They are most often sporadic and are rarely reported to be associated with Castleman disease, especially hyaline vascular variant. It has been proposed that aberrations in Follicular dendritic meshwork by EGFR expression with dysplastic changes in follicular dendritic cells may lead to the development of FDCC. Association with Epstein Barr Virus (EBV) is reported around 90% of cases of IMT like variant. As FDCCs express CD21 which is an EBV receptor, it is hypothesised that EBV infection can cause FDC hyperplasia leading to neoplasia.^{4,5} FDCC in association with autoimmune diseases such as Myasthenia gravis and paraneoplastic pemphigus have also been reported.^{6,7}

The most common histologic appearance is sarcomatoid resembling spindle cell sarcomas. The cells with epithelioid appearance have been reported. Rarely they can have pleomorphic appearances, which has been reported in recurrences similar to one of our cases.⁸ Sprinkling of lymphocytes is a notable finding in predominant cases. Rare multinucleate giant cells have been reported. IMT like variant needs special mention. It is more common in women and is reported in liver and spleen. A close association with EBV has been reported in nearly 90% of the cases.⁹ Immunohistochemistry plays an important role in diagnosing FDCC. The neoplastic cells are most often positive for at least one of the follicular dendritic markers such as CD21, CD23, CD35, D2-40 and clusterin. The cells are typically positive for Vimentin and CD68. S100, CD4, CD20, LCA and

SMA can be variably expressed. MIB 1 proliferation index is highly variable ranging from 1-25%.

Differential diagnosis is wide as FDCC is known to present with varied histomorphological patterns and also varies with the different locations. This is clearly evident from the fact that four of our cases, have been initially misdiagnosed as various entities. The most common differentials are broad and includes other tumors of dendritic/histiocytic cell lineage such as Interdigitating dendritic cell sarcoma, Langerhan cell sarcoma and histiocytic sarcoma, other spindle cell sarcomas, carcinomas, melanoma, lymphoma, thymoma and so on and so forth. Immunohistochemistry plays a major role in delineating these entities.

FDCC often shows complex karyotype. BRAF mutations are reported in a proportion of cases (18.5%), especially more so in IMT like variant (40%).¹⁰ EGFR over expression has also been reported. Griffin *et al* reported loss of function mutations in various genes involved in Nuclear factor kb regulation, cell cycle progression and immune invasion.¹¹ Further studies in understanding the molecular profile may help us in finding out potential targeted therapies in future.

FDCC is an intermediate grade tumor with typically indolent clinical course. Few histologic parameters have been reported to be associated with poor prognosis such as coagulative necrosis, increased mitotic index of > 5 per 10 high powered fields, absence of background lymphoplasmacytic infiltrate and marked nuclear pleomorphism. The other poor prognostic factors are young age at diagnosis, intra-abdominal location and tumor size >6cm. Local recurrences are more common as reported in three of our cases.¹² Sayginetal in their analysis of reported cases found that the local recurrence was 28% and distal metastases was 27%. The most common distal metastatic sites were lung, lymph nodes, liver and bone. The median survival of localised disease is excellent and is reported to be 168 months. The 2 years survival rate of patients with distant metastases is 42.8% as compared to 82.4% in localised disease.¹³

Complete excision is the recommended treatment of choice. Adjuvant treatment such as chemotherapy and radiotherapy has been recommended in incompletely excised cases, recurrent cases and clinically aggressive tumors. Programmed death cell 1 ligand 1(PDL1) expression has been reported in around 50% of FDCC in various studies. There are few case reports of FDCC who had benefitted from immunotherapy.^{13,14}

CONCLUSIONS

FDCS are rare neoplasms with intermediate prognosis. They have varied histomorphological patterns and are often misdiagnosed, as four cases in our series were initially misdiagnosed as different neoplasms. Hence, awareness about these rare neoplasms and including them as a differential under neoplasms with spindle, epithelioid and pleomorphic morphology would prevent misdiagnosing these entities.

REFERENCES

1. Wright-Browne V, McClain K, Talpaz M, Ordonez N, Estrov Z. Physiology and pathophysiology of dendritic cells. *Hum Pathol.* 1997;28(5):563-579. doi:10.1016/s0046-8177(97)90079-4.
2. Monda L, Warnke R, Rosai J. A primary lymph node malignancy with features suggestive of dendritic reticulum cell differentiation. A report of 4 cases. *Am J Pathol.* 1986 Mar;122(3):562-72. PMID: 2420185; PMCID: PMC1888214.
3. Saygin C, Uzunaslani D, Ozguroglu M, Senocak M, Tuzuner N. Dendritic cell sarcoma: a pooled analysis including 462 cases with presentation of our case series. *Crit Rev Oncol Hematol.* 2013;88(2):253-271.
4. Tregnago, A.C., Morbeck, D.L., D'Almeida Costa, F. *et al.* Inflammatory pseudotumor-like follicular dendritic cell tumor: an underdiagnosed neoplasia. *Appl Cancer Res* 37, 45 (2017).
5. Lindhout E, Lakeman A, Mevissen ML, de Groot C. Functionally active Epstein-Barr virus-transformed follicular dendritic cell-like cell lines. *J Exp Med.* 1994 Apr 1;179(4):1173-84. doi: 10.1084/jem.179.4.1173. PMID: 8145036; PMCID: PMC2191436.
6. Su Z, Liu G, Liu J, *et al.* Paraneoplastic pemphigus associated with follicular dendritic cell sarcoma: report of a case and review of literature. *Int J Clin Exp Pathol.* 2015;8(10):11983-11994. Published 2015 Oct 1.
7. Hsu C, Vega F, Grimes LM, Hunt KK. Follicular dendritic cell sarcoma and associated myasthenia gravis: true, true, related? *J Clin Oncol.* 2011 May 1;29(13):e369-71. doi: 10.1200/JCO.2010.32.7932. Epub 2011 Feb 14. PMID: 21321294.
8. Li L, Shi YH, Guo ZJ, *et al.* Clinicopathological features and prognosis assessment of extranodal follicular dendritic cell sarcoma. *World J Gastroenterol.* 2010;16(20):2504-2519. doi:10.3748/wjg.v16.i20.2504.
9. Tregnago, A.C., Morbeck, D.L., D'Almeida Costa, F. *et al.* Inflammatory pseudotumor-like follicular dendritic cell tumor: an underdiagnosed neoplasia. *Appl Cancer Res* 37, 45 (2017). <https://doi.org/10.1186/s41241-017-0051-7>.
10. Go H, Jeon YK, Huh J, Choi SJ, Choi YD, Cha HJ, Kim HJ, Park G, Min S, Kim JE. Frequent detection of BRAF(V600E) mutations in histiocytic and dendritic cell neoplasms. *Histopathology.* 2014 Aug;65(2):261-72. doi: 10.1111/his.12416. Epub 2014 May 12. PMID: 24720374.
11. Griffin GK, Sholl LM, Lindeman NI, Fletcher CD, Hornick JL. Targeted genomic sequencing of follicular dendritic cell sarcoma reveals recurrent alterations in NF- κ B regulatory genes. *Mod Pathol.* 2016 Jan;29(1):67-74. doi: 10.1038/modpathol.2015.130. Epub 2015 Nov 13. PMID: 26564005.
12. Chan JK, Fletcher CD, Nayler SJ, Cooper K. Follicular dendritic cell sarcoma: clinicopathologic analysis of 17 cases suggesting a malignant potential higher than currently recognized. *Cancer.* 1997;79(2):294-313.
13. Agaimy A, Michal M, Hadravsky L, Michal M. Follicular dendritic cell sarcoma: clinicopathologic study of 15 cases with emphasis on novel expression of MDM2, somatostatin receptor 2A, and PD-L1. *Ann Diagn Pathol.* 2016 Aug;23:21-8. doi: 10.1016/j.anndiagnpath.2016.05.003. Epub 2016 May 18. PMID: 27402219.
14. Lee MY, Bernabe-Ramirez C, Ramirez DC, Maki RG. Follicular dendritic cell sarcoma and its response to immune checkpoint inhibitors nivolumab and ipilimumab. *BMJ Case Rep.* 2020 Apr 22;13(4):e234363. doi: 10.1136/bcr-2020-234363. PMID: 32327462; PMCID: PMC7202776.

