

# Comprehensive Analysis of Salivary Gland Lesions: Evaluating Spectrum in Tertiary Care through Fine Needle Aspiration Cytology

Mohibul Islam Ahmed<sup>1</sup>, Mohammed Abdul Sameer<sup>2</sup>, Deepak Sadhu<sup>3</sup>,  
Reshma Wattamwar<sup>4</sup>

## How to cite this article:

Mohibul Islam Ahmed, Mohammed Abdul Sameer, Deepak Sadhu, *et al.* Comprehensive Analysis of Salivary Gland Lesions: Evaluating Spectrum in Tertiary Care through Fine Needle Aspiration Cytology. *Ind J Pathol: Res Pract.* 2023;12(4) 131-135.

## Abstract

**Background:** Salivary glands, pivotal for oral health, present diagnostic complexities with diverse pathologies, including neoplasms constituting 6% of head and neck tumors. FNAC proves to be a reliable and cost-effective diagnostic tool, proficient in discerning various salivary gland lesions.

**Aims:** This study aims to comprehensively explore the spectrum of salivary gland lesions within a tertiary care center, emphasizing FNAC precision.

**Materials and Methods:** This retrospective observational study, conducted at Dr. Shankarrao Chavan Government Medical College and Hospital, Nanded, from January 2021 to September 2023, aimed to comprehensively analyze 60 cases of suspected salivary gland lesions using FNAC.

**Results:** This study examined 60 salivary gland tumor cases, finding a balanced gender distribution (51.67% males, and 48.33% females). Prevalence peaked in ages 31-40 (25%). Parotid (50.00%) and submandibular (43.33%) glands were primary tumor sites. Chronic sialadenitis (30%) dominated non-neoplastic lesions. Pleomorphic Adenoma dominated benign cases (21.67%), while Mucoepidermoid Carcinoma was the most common malignancy (3.33%). The sensitivity, specificity, and diagnostic accuracy for the neoplastic lesion were 75%, 100%, and 92.86% respectively.

**Conclusion:** This study enhances understanding of the demographic and pathological landscape of salivary gland lesions highlighting the prevalence of non-neoplastic conditions

**Author Affiliation:** <sup>1</sup>Resident, <sup>2</sup>Professor and Head, <sup>3,4</sup>Assistant Professor, Department of Pathology, Dr. Shankarrao Chavan Government Medical College & Hospital, Nanded 431606, Maharashtra, India.

**Corresponding Author: Mohibul Islam Ahmed,** Resident, Department of Pathology, Dr. Shankarrao Chavan Government Medical College & Hospital, Nanded 431606, Maharashtra, India.

**E-mail:** mohibulislam03@gmail.com

**Received on:** 10.02.2024 **Accepted on:** 21.03.2024

like chronic sialadenitis and specific neoplasms, such as pleomorphic adenoma and mucoepidermoid carcinoma. FNAC remains pivotal for accurate diagnosis, emphasizing its ongoing role in clinical decision-making.

**Keywords:** Salivary gland lesions; Fine-needle aspiration cytology (FNAC); Tertiary care; Chronic sialadenitis; Pleomorphic adenoma; Mucoepidermoid carcinoma.

## INTRODUCTION

Salivary glands are essential for oral health, serving roles in digestion, mouth lubrication, and microbial defense. However, susceptibility to pathology poses diagnostic challenges for clinicians. Salivary gland neoplasms account for 6% of all head and neck tumors.<sup>1</sup> Stewart *et al*'s fine needle aspiration cytology (FNAC) gained popularity as a reliable, cost-effective diagnostic tool.<sup>2,4</sup> Cytology effectively distinguishes between salivary and non-salivary lesions, benign and malignant conditions, as well as specific and nonspecific inflammation.<sup>5</sup> This Study aims to explore the spectrum of salivary gland lesions in the Nanded region, offering insights through comprehensive analysis at a tertiary care center, focusing on FNAC cytomorphology.

## MATERIALS AND METHODS

This Retrospective Observational Study, conducted at the Department of Pathology, Dr. Shankarrao Chavan Government Medical College and Hospital, Nanded, spanned from January 1, 2021, to September 2023. It encompassed 60 patients with suspected salivary gland lesions who underwent FNAC in our Department. Patient information, including age, sex, anatomical site, detailed clinical history, and physical examination, was meticulously recorded. FNAC procedures involved a 10 ml disposable syringe and 23/24 gauge needle,<sup>12-15</sup> performed without local anesthesia following informed verbal consent. Air dried smears were Giemsa stained, while wet smears fixed in 95% ethyl alcohol were stained with hematoxylin and eosin. Cytopathologists independently examined stained FNA smears for cytomorphological findings, and diagnoses and provided differential diagnoses as needed. Cytological and histopathological correlation was done in 14 Patients with a FNAC diagnosis of neoplastic lesion. Keeping histopathological diagnosis as the gold standard, sensitivity, specificity, and diagnostic accuracy were calculated.

## RESULTS

In the present study encompassing 60 salivary gland tumor cases, gender distribution yielded a near equitable representation, with 31 cases (51.67%) in males and 29 cases (48.33%) in females.

Tumors were observed across various age groups, with the highest prevalence in the age groups 31-40, accounting for 25% of cases. Anatomical site analysis reveals, tumors were predominantly located in the parotid (50.00%) and submandibular (43.33%) glands. Non-neoplastic lesions featured prominently, with chronic sialadenitis (30%) exhibiting prevalence. In neoplastic classifications, Pleomorphic Adenoma dominated the benign spectrum, accounting for 21.67% of cases. Conversely, Mucoepidermoid Carcinoma emerged as the commonest malignant entity, representing 3.33% of cases. In the present study, both cytology and histology were carried out in 14 cases of neoplastic lesion and a correlation was done for sensitivity, specificity, and diagnostic accuracy. The sensitivity, specificity, and diagnostic accuracy for the neoplastic lesion were 75%, 100%, and 92.86% respectively.

**Table 1:** Gender Wise Distribution of Tumor

Gender	No of Cases	Percentage
Male	31	51.67%
Female	29	48.33%
Total	60	100%

**Table 2:** Age Wise Distribution of Tumor

Age Group (years)	Male	Female	Percentage
0-10	1	0	1 (1.67%)
11-20	3	3	6 (10.00%)
21-30	6	5	11 (18.33%)
31-40	6	9	15 (25%)
41-50	6	3	9 (15.00%)
51-60	4	2	6 (10.00%)
61-70	3	3	6 (10.00%)
71-80	1	2	3 (5.00%)
81-90	0	1	1 (1.67%)
91-100	1	1	2 (3.33%)
Total	31 (51.67%)	29 (48.33%)	60

**Table 3:** Anatomical Site wise Distribution of Tumor


Location	Number of cases	Percentage
Parotid	30	50.00%
Submandibular	26	43.33%
Sublingual	3	5.00%
Minor salivary glands	1	1.67%
Total	60	100

**Table 4:** Distribution and type of lesion diagnosed by FNAC

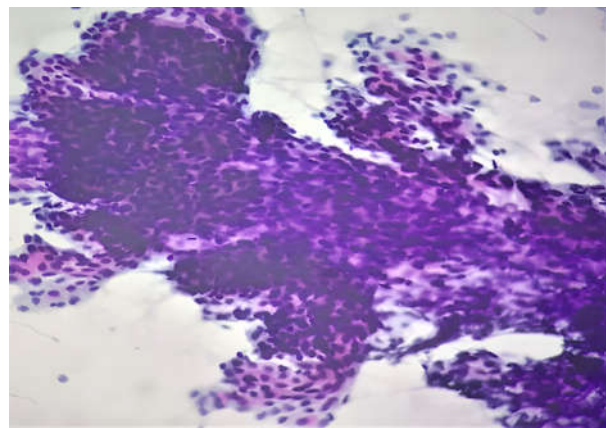
Type of lesion	-	Parotid	Submandibular	Sublingual	Minor Salivary	Total	Percentage
Non-neoplastic (71.67%)	Chronic Sialoadenitis	10	8	0	0	18	30%
	Acute Sialoadenitis	7	6	1	0	14	23.33%
	Acute On chronic Sialoadenitis	3	3	1	0	7	11.67%
	Mucinous Cysts	0	1	0	0	1	1.67%
	Granulomatous Sialoadenitis	0	2	1	0	3	5%
Neoplastic (28.33%)	Pleomorphic Adenoma	8	5	0	0	13	21.67%
Benign	Warthins Tumour	1	0	0	0	1	1.67%
Malignant	Mucoepidermoid Carcinoma	0	1	0	1	2	3.33%
	Adenoid Cystic Carcinoma	1	0	0	0	1	1.67%

**Table 5:** Histopathological Correlation of Neoplastic Salivary Gland Lesions

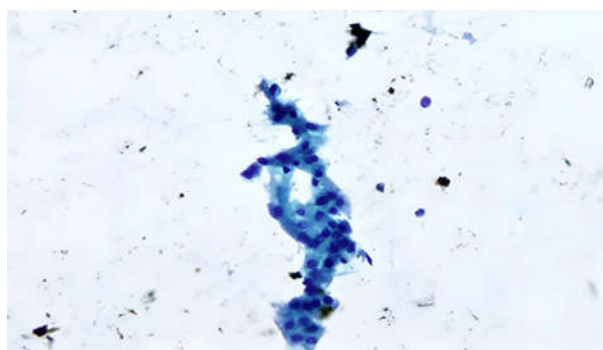
Fnac	Histopathology			
	Pleomorphic Adeoma	Warthin Tumor	Mucoepidermoid Carcinoma	Adenoid Cystic Carcinoma
Pleomorphic Adenoma (10)	9	-	1	-
Warthin Tumor (1)	-	1	-	-
Mucoepidermoid Carcinoma (2)	-	-	2	-
Adenoid Cystic Carcinoma (1)	-	-	-	1
Total Cases (14)	-	-	-	-



**Fig. 1:** Pleomorphic Adenoma (H & E 10X)



**Fig. 2:** Warthin's Tumor (H&E 40x)



**Fig. 3:** Mucoepidermoid Carcinoma (Pap 40x)

## DISCUSSION

This study delves into the comprehensive assessment of salivary gland lesions using fine needle aspiration cytology (FNAC) in 60 cases, unveiling a spectrum of non-neoplastic and neoplastic conditions across diverse patient demographics. The mean age in this study was 47.8 years, spanning 8 to 94 years, with a male predominance a departure from studies

conducted by S. Nguansangiam *et al.*,<sup>6</sup> indicating female predominance. The parotid gland was predominantly affected, aligning with the findings of Choudhury *et al.*<sup>9</sup> FNAC analysis revealed 71.67% non-neoplastic lesions, consistent with a finding consistent with the work by S. Nguansangiam *et al.*<sup>6</sup> Chronic sialadenitis emerged as the most common non-neoplastic lesion, aligning with other studies by Singh Nanda KD *et al* and Gupta R *et al.*<sup>10-11</sup> Pleomorphic adenoma, the predominant benign neoplasm (21.67%), corroborating previous findings by Mili Jain *et al.*,<sup>8</sup> further supporting the prevalence of these lesions in the examined population. In the current study mucoepidermoid carcinoma emerged as the commonest malignancy, constituting 66.67% of all malignant neoplasms. This finding is consistent with the results obtained by Sonal Verma *et al.*<sup>7</sup> In our study, sensitivity, specificity, and diagnostic accuracy of preoperative cytology of salivary gland tumors were 75%, 100%, and 92.86% respectively finds consonance with those previously reported in various studies.<sup>6,7,8,11</sup> Recognition of these patterns aids accurate diagnosis and informs tailored management strategies. This study contributes valuable insights into the prevalence and characteristics of salivary gland lesions, shedding light on their demographic nuances and reinforcing the importance of nuanced diagnostic approaches in clinical practice.

## CONCLUSION

In conclusion, our study significantly contributes to the understanding of the demographic and pathological landscape of salivary gland lesions. The high prevalence of non-neoplastic lesions, especially chronic sialadenitis, underscores the importance of recognizing and managing inflammatory conditions in clinical practice. Moreover, the consistent occurrence of specific benign and malignant neoplasms, such as pleomorphic adenoma and mucoepidermoid carcinoma, provides valuable information for clinicians, aiding in accurate diagnosis and formulation of targeted therapeutic strategies. The utilization of FNAC as a diagnostic tool in salivary gland lesions is reaffirmed, emphasizing its role in enhancing clinical decision making. Further, collaborative efforts and ongoing research endeavors are imperative to refine our understanding of these lesions, paving the way for advancements in diagnostic and therapeutic methodologies.

## ACKNOWLEDGEMENT

The authors gratefully acknowledge the support and resources provided by Dr. Shankarrao Chavan Government Medical College and Hospital, Nanded. Special thanks to the participants for their involvement in this study. We extend our appreciation to the medical and research staff for their valuable contributions. This work was made possible by the collaborative efforts and facilities offered by the institutions, enhancing the quality and scope of our research on salivary gland lesions.

## REFERENCES

1. L. Barnes, J. W. Eveson, P. Reichart, and D. Sidransky. Pathology and genetics of head and neck tumors. In World Health Organization Classification of Tumors, P. Kleihues and L. H. Sobin, Eds., p. 210, IARC Press, Lyon, France, 2005.
2. Mavec P, Eneroth CM, Franzen S, Moberger G, Zajicek J. Aspiration biopsy of salivary gland tumors. Correlation of cytologic reports from 652 aspiration biopsies with clinical and histologic findings. *Acta oto-laryngologica*. 1964;58(1-6):471-84.
3. Franzen S, Zajicek J. Cytologic diagnosis on aspirates from 1000 salivary gland tumors. *Acta Otolaryngol*. 1970;224:168-72.
4. Shaha AR, Webber C, dimaio T, Jaffe BM. Needle aspiration biopsy in salivary gland lesions. *Am J Surg*. 1990;160:373-6.
5. Khandekar MM, Kavatkar AN, Patankar SA, Bagwan IB, Puranik SC, Deshmukh SD. FNAC of salivary gland lesions with histopathological correlation. *Indian J Otolaryngol Head Neck Surg*. 2006;58:246-8.
6. S. Nguansangiam, S. Jesdapatarakul, N. Dhanarak, and K. Sosrisakorn, "Accuracy of fine needle aspiration cytology of salivary gland lesions: routine diagnostic experience in Bangkok, Thailand." *Asian Pacific Journal of Cancer Prevention*. 2012; 13(4):1583-1588.
7. Sonal Verma S. Fine needle aspiration cytology of salivary gland lesions: study in a tertiary care hospital of North Bihar. *Int J Res Med Sci* 2016;4:3869-72.
8. Mili Jain, Upasana Punatar, Sanyam Modi, Kuntal Patel. Role of FNAC in the diagnosis of salivary gland lesions - A tertiary care hospital experience. *IAIM*, 2022; 9(10): 27-31.
9. A.A Choudhury, T. Sultana, B.H. Siddique, and A. S. A. Amin, "Diagnosis of parotid gland mass by the fine needle aspiration cytology (FNAC) and its histopathological correlation 2 years study

- in BSMMU, Dhaka," *Bangabandhu Sheikh Mujib Medical University Journal*, vol. 4, no. 2, pp. 65-69, 2011.
10. Singh Nanda KD, Mehta A, Nanda J. Fine needle aspiration cytology: A reliable tool in the diagnosis of salivary gland lesions. *J Oral Pathol Med.* 2012 Jan;41(1):106-12.
  11. Gupta R, Dewan D, Kumar D, Suri J. Fine needle aspiration cytology of salivary gland lesions with histopathological correlation in a district hospital of Jammu region. *Indian J Pathol Oncol.* 2016 Jan-Mar;3(1):32-7.
  12. Gunvanti Rathod, Pragnesh Parmar. Fine needle aspiration cytology of swellings of head and neck region. *Indian Journal of Medical Sciences*, 2012; 66: 49-54.
  13. Rathod GB, Ghadiya V, Shinde P, Tandan RK. Pleomorphic sarcoma in 60 years old male - A case report. *International Journal of Current Microbiology and Applied Sciences*, 2014; 3(8): 510-517.
  14. Annie Jain, Gunvanti Rathod. Oncocytoma of the parotid gland: A rare case report. *IAIM*, 2015; 2(4): 166-169.
  15. Nupur Singla, Gunvanti Rathod, Disha Singla. Adenoid cystic carcinoma of the parotid gland - A case report and review of literature. *IAIM*, 2015; 2(4): 182-186.

