

# A Clinical Study of Surgical Management and Outcome of Ileal Perforation

Shanta B Patil<sup>1</sup>, Vijaylaxmi Dulange<sup>2</sup>

**Author's Affiliation:** <sup>1</sup>Associate Professor, <sup>2</sup>Postgraduate, Department of General Surgery, Mahadevappa Rampure Medical College, Kalaburagi, Karnataka 585102, India.

## How to cite this article:

Shanta B Patil, Vijaylaxmi Dulange. A Clinical Study of Surgical Management and Outcome of Ileal Perforation. New Indian J Surg. 2020;11(3):281-284.

## Abstract

**Background:** Ileal perforation is one of the most common acute abdominal emergencies in surgical field. There are multiple factors that influence the prognosis and outcome of the patient.

**Methods:** Present study was a prospective interventional study aimed at evaluating the clinical profile, etiology and surgical management and its outcome of patients with nontraumatic ileal perforation.

**Results:** There were 50 patients of nontraumatic ileal perforation; causes for perforation were typhoid 56%; non specific 26%; obstruction 12%; tuberculosis 3%.

Simple closure of perforation and resection and anastomosis were the mainstay of the surgical management.

**Conclusion:** Terminal ileal perforation should be suspected in all cases of peritonitis especially in developing countries and surgical treatment should be optimized taking various accounts like etiology, delay in surgery and operative findings into consideration to reduce the incidence of deadly complications like septicemia, pyoperitoneum, fecal fistula.

## Background

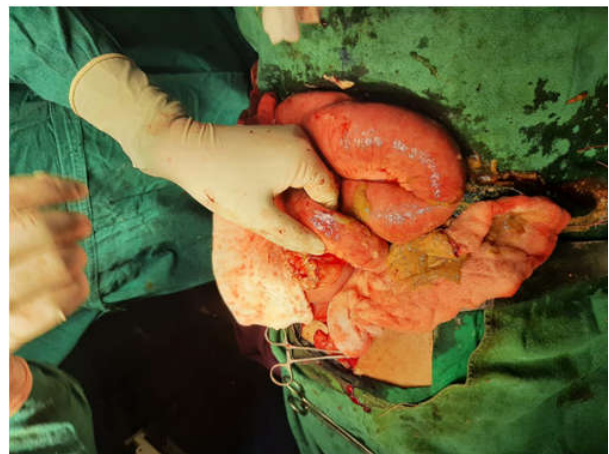Ileal perforation is one of the most common acute abdominal emergencies in surgical field. A careful medical history, methodical clinical examination

and radiological study plays a major role in the diagnosis of this acute abdominal emergency. There are multiple factors that influence the prognosis and outcome of the patient.

There is still confusion and controversy over the diagnosis and optimal surgical treatment of non traumatic terminal ileal perforation-a cause of obscure peritonitis.<sup>1</sup> Preoperative resuscitation, intravenous administration of broad spectrum antibiotics, surgical technique advocated and good post operative care are the mainstay in the management of ileal perforation. The operative management depends on underlying pathology, number of perforations and condition of bowel wall intra-operatively.<sup>2</sup>

## Methods

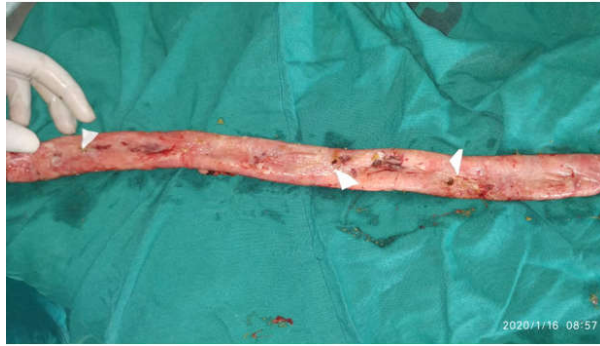Present study was a prospective interventional study, conducted at Basaveshwar teaching and



**Fig. 1:** Intraop picture showing multiple ileal perforations with fecal matter spillage.

**Corresponding Author:** Vijaylaxmi Dulange, Postgraduate, Department of General Surgery, Mahadevappa Rampure Medical College, Kalaburagi, Karnataka 585102, India.

**E-mail:** [dulangevijaylaxmi@gmail.com](mailto:dulangevijaylaxmi@gmail.com)



**Fig. 2:** Picture showing resected segment of ileum with multiple perforations.

general hospital Gulbarga, from October 2018 to January 2020. A thorough history was taken and detailed examination done as per proforma. Investigations included cbc, Serum. Electrolytes, Random blood sugar, Renal function test, Chest x ray, X ray Erect abdomen, USG abdomen, Widal test.

#### *Inclusion criteria:*

1. Patients of age groups >18yrs of both male and female.

2. Cases of non traumatic ileal perforation.

#### *Exclusion criteria*

1. Cases of traumatic ileal perforation.

2. Cases of delayed presentation with shock and septicemia whose general condition did not warrant any operative management even after resuscitative measures.

*Sampling Procedure:* Study subjects will be selected after applying inclusion-exclusion criteria. Information is collected through prepared proforma from each patient.

*Statistical Data Analysis:* The data collected will be analysed statistically by using IBM SPSS software 20.0 using descriptive statistics namely mean standard deviation for quantitative variables and presented as counts and percentage. Data will be analysed using percentages, proportions.

*Informed Consent:* Written and informed consent was taken taken in patient's own vernacular language.

## Observations

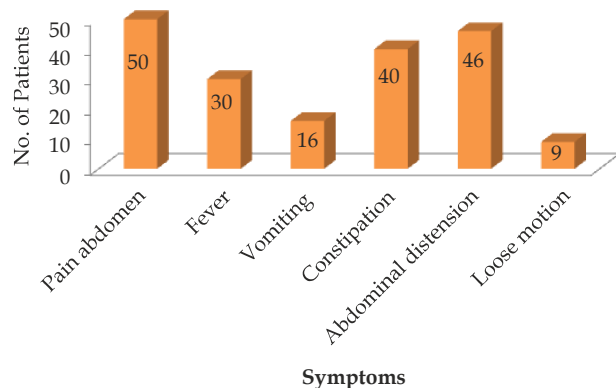
The present prospective study was conducted on 50 patients to evaluating the clinical profile, etiology and optimal surgical management of patients with non traumatic ileal perforation. The mean and SD

of age of patients was  $35.12 \pm 14.65$  and the male female ratio was 3.2:1.

**Table 1:** Symptoms wise distribution of patients.

Symptoms	Number of patients	Percentage
Pain abdomen	50	100.0
Fever	30	60.0
Vomiting	16	32.0
Constipation	40	80.0
Abdominal distension	46	92.0
diarrhoea	9	18.0

Study observe that, out of 50 non traumatic terminal ileal perforation cases the most commonest symptom was pain abdomen 100.0% followed by abdominal distension was 92.0%, constipation 80.0% and fever 60.0%. (Table 1)



**Fig 3:** Bar diagram represents symptoms wise distribution of cases.

**Table 2:** Etiology wise distribution of patients.

Etiology	Number of patients	Percentage
Typhoid	28	56.0
Non specific	13	26.0
Obstruction	6	12.0
Tuberculosis	3	6.0

In the present study there were 28 (56.0%) patients had typhoid , non specific were 13(26.0%), obstruction cases were 6(12.0%) and tuberculosis cases were 3(6.0%). (Table 2)

**Table3:** Lab findings wise distribution of patients.

Lab findings	Number of patients	Percentage
Raised total count	28	56.0
Positive widal	13	26.0
Air under diaphragm in X ray erect abdomen	50	100.0
Tuberculosis	3	6.0

Study observe that 28 (56.0%) patients had raised total count, 13 (26.0%) cases had widal positive, 50 (100.0%) cases had air under diaphragm in X ray erect abdomen and 3 (6.0%) had tuberculosis.

**Table 4:** Type of operation wise distribution of patients. (Table 3)

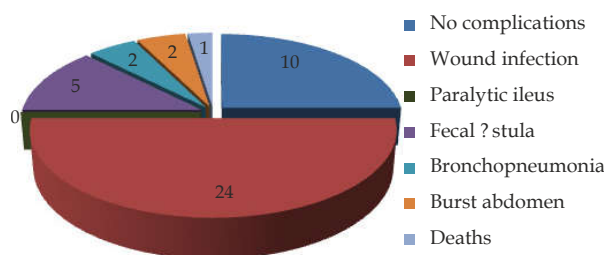
Type of operation	Number of patients	Percentage
Simple closure: double layer	38	76.0
Resection and anastomosi (end to end)	6	12.0
Side to side ileotransverse anastomosis	4	8.0
Ileostomy	2	4.0

In the present study out of 50 patients 38 (76.0%) of patients were operated by simple closure: double layer and 6 (12.0%) patients were operated by resection and anastomosi (end to end). (Table 4)

**Table 5:** Post operative complications.

Post OP Complications	Number of patients	Percentage
No complications	12	24.0
Wound infection	20	40.0
Paralytic ileus	0	0.0
Fecal fistula	5	10.0
Bronchopneumonia	2	4.0
Burst abdomen	0	0.0
Death	1	2.0

Study observe that, 12 (24.0%) patients had no complications 20 (40.0%) patients had complication of wound infection. (Table 5)



**Fig 4:** Pie diagram represents post operative complications of patients

**Table 6:** Perforations wise distribution of patients.

Perforations	Number of patients	Percentage
Single	38	76.0
Multiple	12	24.0
Total	50	100.0

In the study there were 38(76.0%) of patients were had the single perforation and 12(24.0%) had multiple perforations. (Table 6)

**Discussion**

Ileal perforation is one of the most common acute abdominal emergencies in surgical field. Non traumatic terminal ileal perforation is still common as a cause for obscure peritonitis in developing and underdeveloped world although in west it is quite rare. The terminal ileal perforation presents

a diagnostic dilemma to the surgeon. Laparotomy is usually carried out late often suspecting a perforated appendicitis or a duodenal ulcer.

Intestinal perforation through an ulcerated Peyer patch occurs in approximately 2% of cases. Typically, it is a single perforation in the terminal ileum, and simple closure of the perforation is the treatment of choice. (Fig. 1) With multiple perforations, (Fig. 2) which occur in about 25% of patients, resection with primary anastomosis or exteriorization of the intestinal loops may be required. The most frequent site of intestinal involvement of M.tuberculosis is the distal ileum and cecum, with 85% to 90% of patients demonstrating disease at this site. The gross appearance can be ulcerative, hypertrophic, or ulcerohypertrophic. The bowel wall appears thickened and an inflammatory mass often surrounds the ileocecal region. Surgery may be necessary for ulcerative complications when free perforation, perforation with abscess, or massive hemorrhage occurs. The treatment is usually resection with anastomosis.

In a study conducted by rauf a wani,fazl q parry et. al. shows; There were 79 cases of nontraumatic terminal ileal perforation the causes for perforation were enteric fever (62%), nonspecific inflammation (26%), obstruction (6%), tuberculosis (4%) and radiation enteritis (1%). Simple closure of the perforation (49%) and end to side ileotransverse anastomosis (42%) were the mainstay of the surgical management.

The complications of intestinal tuberculosis are bowel obstruction (31.7%), intestinal perforation (4.9%), entero-cutaneous fistula (2.4%) and small bowel volvulus due to mesenteric lymphadenitis (2.4%) Free perforation in intestinal tuberculosis usually occurs in the terminal ileum like our patient and it can occur even in patients during anti tuberculosis therapy. In 90% of the cases, perforation is solitary, but multiple perforations occur in 10-40% of patients and are associated with a poor prognosis, therefore immediate operative intervention is indicated. The general condition of the patient, the number of perforations, the condition of the intestine, and surgeon’s experience define the operative procedure, prognosis and outcome. Single perforation can be treated by excision and simple closure . However, resection of the affected small bowel segment and end to end anastomosis proved to be the best method of treatment. Simple repair of the perforation is not recommended because of the high incidence of leak and fistula formation . After surgery these patient should be treated with anti-tubercular therapy.<sup>3</sup>

The most lethal complications of typhoid fever are intestinal bleeding and ileal perforations, both arising from necrosis of Payer's patches in the terminal ileum. Perforation of a typhoid ulcer usually occurs during the third week and is occasionally the first sign of the disease. Non-traumatic terminal ileal perforation is still common as a cause for obscure peritonitis in developing and underdeveloped world.<sup>4</sup>

### Conclusion

Terminal ileal perforation should be suspected in all cases of peritonitis especially in developing countries and surgical treatment should be optimized taking various accounts like etiology, delay in surgery and operative findings into consideration to reduce the incidence of deadly complications like septicemia, pyoperitoneum, fecal fistula.

### References

1. Wani RA, Parray FQ, Bhat NA, Wani MA, Bhat TH, Farzana F. Nontraumatic terminal ileal perforation. *World Journal of Emergency Surgery*. 2006;1:7. doi:10.1186/1749-7922-1-7.
2. Mishra, Mayank; Singh, Puspendra; Tripathi, Alok. Typhoid ileal perforation: comparative study of ileostomy versus primary ileal repair and associated morbidity and mortality. *International Surgery*
3. Dan D, Islam S and Naraynsingh V (2015) Free Perforation of Ileal Tubercular Ulcer- A Case Report and Literature Review. *ClinMicrobiol* 4: 182. doi:10.4172/2327-5073.1000182
4. Singh, Gurjit et. al. "Non-traumatic ileal perforation: a retrospective study." *Journal of family medicine and primary care* vol. 3,2 (2014): 132-5. doi:10.4103/2249-4863.137633.