

**Author's Affiliation:**

<sup>1,4</sup>Post Doctoral Trainee, <sup>2</sup>Assistant Professor,  
<sup>3</sup>Professor and Head of the Department,  
Department of Urology, Nil Ratan Sircar Medical  
College & Hospital, Kolkata, West Bengal 700014  
India.

**Corresponding Author:**

**Saurav Karmakar**, Post Doctoral Trainee,  
Department of Urology, Nil Ratan Sircar Medical  
College & Hospital, Kolkata, West Bengal 700014  
India.

**Email:** [srv716@gmail.com](mailto:srv716@gmail.com)

## Left-out Suprapubic Cystostomy Cannula Tip at Urethra: A Rare Case Report

**Saurav Karmakar<sup>1</sup>, Parthapratim Das<sup>2</sup>, Tapan Kumar  
Manadal<sup>3</sup>, Asim Kumar Das<sup>4</sup>**

**Abstract**

Foreign bodies of the urethra and bladder has a low incidence. Most foreign bodies in the lower genitourinary tract are self-inserted via the urethra as the result of exotic impulses, psychometric problems, sexual curiosity, or sexual practice while intoxicated. This case warrants discussion given the great management challenge faced by the oddity and infrequency with which a left out suprapubic cystostomy cannula tip is encountered in the penile urethra. On cystoscopy in a 54 yr patient with acute urinary retention (AUR) and suprapubic catheter (SPC) in situ, the sharp pointed detached cannula tip was found in the urethra. The object was removed endoscopically under local anaesthesia using some special techniques.

**Introduction:** Foreign bodies of the urethra and bladder are seldom seen in clinical urologic practice with iatrogenic injury, self-insertion, and rarely migration from adjacent sites.<sup>1</sup> Foreign bodies are most commonly inserted into the urinary tract by psychiatric, intoxicated, confused, or sexually curious patients. Treatment is focused on foreign body extraction, diagnosing complications, and avoiding compromise of erectile function. With advances in endourology, the majority of cases can now be managed endoscopically.<sup>2</sup> Here is a description of a very rare case of SPC cannula tip at urethra which was incidentally found during cystoscopic examination and subsequently removed endoscopically.

**Keywords:** Suprapubic; Systostomy; Catheter.

**How to cite this article:**

Saurav Karmakar, Parthapratim Das, Tapan Kumar Manadal et al./ Urology, Nephrology and Andrology International./ 2021;6(1):15-17.

### Case Report

A 54 yr male patient has been referred at our Urology department with chief complaint of AUR with SPC in situ. He was diabetic on medications but non-hypertensive and having no history of any previous operative intervention except that SPC which was done just 1 month back. Now he was also complaining of mild pain at lower abdomen and in the penile root region.

His general examination was normal. On genitourinary examination, external genitalia were normal. Both the kidneys were not bimanually

palpable, and no renal angle tenderness is there. On DRE, grade 1 prostatomegaly found which is non-nodular, mucosa is mobile and surface is smooth.

On evaluation, his blood reports were normal, USG KUBP was done and found to have 30 cc prostate. Other parameters were normal. Patient was advised to undergo a cystoscopic evaluation. During cystoscopic evaluation, a sharp pointed metallic foreign body was found in proximal penile urethra. On Xray it was found to be bullet like metallic foreign body. It was very difficult to remove by routine endoscopic forceps. A guidewire is passed initially beyond the object and the 10

fr foley catheter was passed over the guidewire. The balloon was inflated partially and the with controlled pull, the object was brought down till the urethral meatus. A dorsal meatotomy was required to finally remove the metallic object. A repeat cystoscopic evaluation was done to rule out any iatrogenic urethral injury. On careful examination of the foreign body, it was found to be a 20\*8 mm metallic pointed tip of the SPC cannula which was probably left out during the initial SPC.

The patient was put on 16 Fr Foley catheter and discharged home. Foley catheter was removed after 2 weeks and satisfactory urinary flow was there on subsequent follow up.

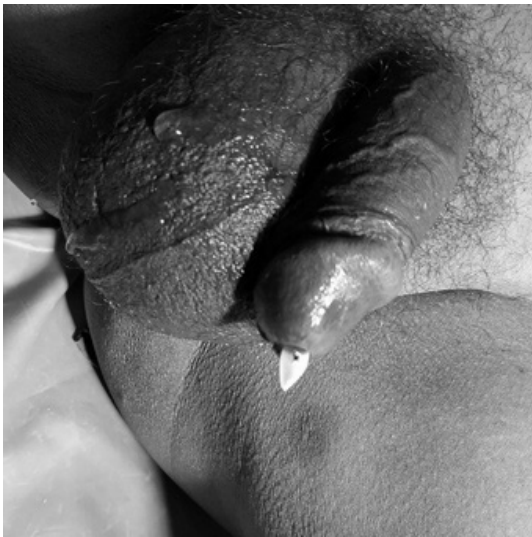

Fig. 1: At meatus.



Fig. 2: Campbell-suprapubic-trocar-and-cannula\_15.

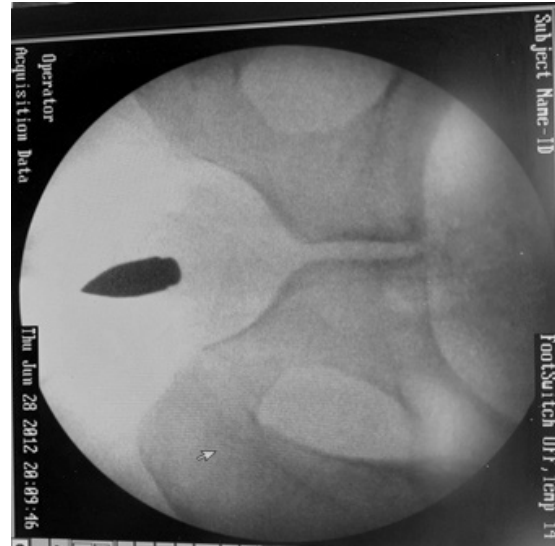


Fig. 3: Carm pic.




Fig. 4: Cpe pic.




Fig. 5: Size.

## Discussion

Percutaneous suprapubic catheterisation (SPC) is a frequently performed and well established procedure for urinary drainage. Despite this, there is a paucity of data regarding the procedure. This was highlighted in the guidelines published by the British Association of Urological Surgeons (BAUS).<sup>3</sup> Generally, it is believed that SPC is associated with minimal complications and morbidity. However, complications do occur and include bleeding, clot retention and catheter dislodgement as early complications,<sup>4,5</sup> prompting BAUS to recommend that it should be performed only by surgeons with appropriate skills.<sup>3</sup> Nevertheless, these complications are avoidable if the procedure is performed carefully. Techniques for percutaneous SPC include direct puncture using a SPC trocar (disposable kits or reusable instruments),<sup>6,7</sup> a modified trocar system using the Seldinger technique,<sup>8</sup> cystoscopy guided SPC<sup>3</sup> and SPC using fluoroscopy<sup>9</sup> or ultrasonography guidance.<sup>10</sup> The trocar SPC placement is a common method in clinical practice.

In our case, we found a left out SPC cannula tip at the proximal penile urethra which has been left out during the initial SPC. The pointed tip of the cannula migrated from bladder and through the bladder neck it reached to the urethra. Eventually it was removed endoscopically inflating Foley catheter balloon proximal to the metallic FB. In this case, the patient was lucky that the sharp pointed cannula tip caused no harm but it might lead to devastating complications.

SPC is a very common procedure not only in urology but also in general surgical emergency and doing it using the SPC trocar and cannula is the most common method. The tip of the cannula should be checked before insertion, better if it is not-detachable and if it is, it should be tightened enough. Also after removing the cannula, the tip should be checked again. Our case is a very rare

case which teaches us even if the procedure is simple, we cannot afford to miss a single step.

**Conflict of Interest:** No

## References

1. Moon Seung Jin, Kim Dai Hee, Chung Jae Hoon, et al. Unusual foreign bodies in the urinary bladder and urethra due to autoerotism. *Int Neurourol J*. 2010 Oct;14(3):186-189.
2. Naidu Krishanth, Chung Amanda, Maurice Mulcahy. An unusual urethral foreignbody. *Int J Surg Case Rep*. 2013;4(11):1052-1054
3. Harrison SC, Lawrence WT, Morley Ret al British Association of Urological Surgeons' suprapubic catheter practice guidelines. *BJU Int* 2011; 107: 77-85 [PubMed] [Google Scholar]
4. Hilton P, Stanton SL. Suprapubic catheterisation. *BMJ* 1980; 281: 1,261-1,263 [Google Scholar]
5. Ahluwalia RS, Johal N, Kouriefs Cet al The surgical risk of suprapubic catheter insertion and long-term sequelae. *Ann R Coll Surg Engl* 2006; 88: 210-213 [PMC free article] [PubMed] [Google Scholar]
6. Lawrence WT, McQuilkin PH, Mann D. Suprapubic catheterisation. *Br J Urol* 1989; 63: 443. [PubMed] [Google Scholar]
7. Conn IG, Stephenson TP. Suprapubic insertion of a Foley catheter: the forgotten technique. *Br J Urol* 1993; 71: 361. [PubMed] [Google Scholar]
8. Suprapubic Foley Catheter Kit Executive Summary. NHS Technology Adoption Centre <http://www.ntac.nhs.uk/HowToWhyToGuides/SuprapubicFoleyCatheterKit/Catheter-Executive-Summary.aspx> (cited May2012). [Google Scholar]
9. Papanicolaou N, Pfister RC, Nocks BN. Percutaneous, large bore, suprapubic cystostomy: technique and results. *Am J Roentgenol* 1989; 152: 303-306 [PubMed] [Google Scholar]
10. Aguilera PA, Choi T, Durham BA. Ultrasound-guided suprapubic cystostomy catheter placement in the emergency department. *J Emerg Med* 2004; 26: 319-321 [PubMed] [Google Scholar]