

## Mono-Bloc Radial Head Prosthesis Replacement for Management of Comminuted Radial Head Fractures: A Retrospective Study

Satya Ranjan Patra<sup>1</sup>, Naresh Kumar Panigrahi<sup>2</sup>, Madini Manoj<sup>3</sup>, Saswat Samant<sup>4</sup>, Hemanta Kumar Bamidi<sup>5</sup>, Siddhartha Shankar Mohanty<sup>6</sup>, Kishore Chandra Das<sup>7</sup>

**Author Affiliation:** <sup>1</sup>Associate Professor, <sup>2,3</sup>Assistant Professor, <sup>5,6,7</sup>Resident, Department of Orthopedics, Hi-Tech Medical College, Bhubaneswar Odisha 751025, India. <sup>4</sup>Assistant Professor, Department of Orthopedics, Kalinga Institute of Medical Sciences, Bhubaneswar, Odisha 751024, India.

**Corresponding Author:** Naresh Kumar Panigrahi, Assistant Professor, Department of Orthopedics, Hi-Tech Medical College, Bhubaneswar, Odisha 751025, India.

**E-mail:** drsatyarp@gmail.com

### How to cite this article:

Satya Ranjan Patra, Naresh Kumar Panigrahi, Madini Manoj, et al. Mono-bloc Radial Head Prosthesis replacement for Management of Comminuted radial Head Fractures: A Retrospective Study. J orth. Edu. 2020;6(1):19–23.

### Abstract

*Introduction:* Radial head is an important stabilizer of the elbow. Although preservation of the fractured radial head has biomechanical advantages, comminuted fractures belonging to Mason type III usually do not have satisfactory outcome after osteosynthesis. Excision of the fractured head also often renders the elbow unstable. Therefore, radial head replacement by a prosthesis has been under study as an alternative option. *Material and Methods:* Seventeen patients with Mason type III radial head fractures treated by cemented mono-block radial head prosthesis were retrospectively studied. Their clinical and functional outcomes were analysed. *Results:* Functional results were studied in the 15 available patients using the Mayo Elbow Performance Score. Seven patients had good or excellent results; six had fair and two had poor outcomes. None had infection, instability, or implant loosening by the end of three years of follow-up. *Conclusion:* Considering the unpredictable outcomes of osteosynthesis in comminuted radial head fractures, cemented prosthetic replacement using the metallic mono-bloc prosthesis is a viable surgical option in these patients with satisfactory results.

**Keywords:** Radial head; Comminuted fracture; Prosthesis; Radial head replacement.

### Introduction

Radial head is considered an important stabilizer of the lateral column of the elbow. It is the second most crucial stabilizer of the elbow after the medial or ulnar collateral ligament against the valgus strain.<sup>1,2</sup> It also performs as the postero-lateral stabilizer of elbow along with the coronoid process and contributes to the axial and varus stability as well.<sup>2</sup> Radial head fractures are common fractures constituting almost 20% of elbow fractures.<sup>3</sup> These fractures occur mostly due to 'fall on outstretched hand' (FOOSH) mechanism while

the elbow is in extension and the forearm is in pronation.<sup>3</sup> By standard practice all around the world, the un-displaced fractures are managed non-operatively and the displaced fractures are reduced anatomically by surgical method and stabilized with internal fixation.<sup>3</sup> Main goals of radial head fixation are achieving a stable and mobile elbow as well as maintaining the length of the forearm.<sup>2,4</sup> But reconstructing the comminuted radial head fractures (Mason type III) is always challenging with unpredictable outcomes and varied complications despite best efforts at osteosynthesis.<sup>1</sup> Therefore, many researchers believe in radial head excision as a solution. But, as such an injury may often

be associated with medial ligament injuries and coronoid fracture etc, excision of the radial head which is the natural stabilizer of the lateral column may render the elbow highly unstable.<sup>1,2,5</sup> Therefore, primary radial head prosthetic replacement has been advocated in Mason type III fractures with three or more fragments, particularly in presence of valgus instability, medial ligament deficiency and other associated injuries.

Radial head replacement has been popularized by various surgeons over the decades by use of many different designs of prosthesis.<sup>1-3,5</sup> Prosthesis may range from Monobloc, Modular Bipolar, stainless steel, titanium, silastic, cemented, cementless etc. Although the bipolar prosthesis is a newer design, few studies have reported higher instability rates of the radio-capitellar joint with bipolar implants in comparison to monobloc designs and uninjured radial heads.<sup>2,6</sup>

We describe our experience of Mason type III injuries of radial heads treated by Monopolar metallic prosthetic replacement with medium range follow-up.

## Material and Methods

This is a retrospective study conducted in a tertiary care hospital on patients treated between March 2015 to June 2019. A total number of 17 patients having Mason type III fractures of the radial heads were included in the study. Two-part fractures, open fractures, infected fractures, age group more than 65 years or younger than 18 years were excluded from the study. All the patients were males; 13 were right sided and four were left sided injuries. All the cases satisfying the inclusion criteria were surgically treated with radial head replacement.

Only X-ray evaluation of the elbow was done in all the cases with antero-posterior (AP) and lateral views. Computed tomography (CT) scan was conducted in only one case with associated distal humerus fracture. None of the patients had any neuro-vascular involvement or open injuries. Regional blocks or general anaesthesia was given in all the cases and pneumatic tourniquet was also used. The radio-capitellar joint was approached through a lateral approach. The comminuted radial head was excised along with a part of neck, attempt was made to preserve the annular ligament. Metallic monobloc radial head prosthesis was used in all the patients after proper sizing of the

resected segment (Fig. 1). Antibiotic impregnated bone cement was used for implantation of the prostheses. After setting of the cement, mobilization of the elbow was done through the full range of motion. Closer was done in the position of ease after thorough lavage of the surgical site. Elbows were kept in removable splints for support. Post-operative elbow mobilization was done by as early as 48 hours under supervision.

Three patients had coronoid process fracture which did not require fixation. Four patients had concomitant tibial shaft fracture, two had fibula fracture, one each had femur shaft fracture and metatarsals fractures. The other fractures were treated as per merit.

Follow-up was carried out at one week, two weeks, six weeks and every six weeks after that until six months (Fig. 2: A, B,C,D). Beyond six months the patients were seen twice every year. Functional evaluation of the patients was done using the Mayo Elbow Performance Score (MEPS).

## Results

Among 17 patients, 15 were available for follow-up and clinical evaluation by the month of June 2019. The mean age of patients was 32.4 years (range, 18-61 years).

The average delay of surgery from the time of injury was 3.5 days (range, 1-42 days). Most of the delays in various patients was due to the time of presentation of patients following injury. Same approach was used in all the cases. Average duration of surgery was 103 minutes (range, 77-134 minutes). In all the cases 20gms pack of Gentamicin impregnated PMMA bone cement was used. Elbow mobilization was started within 48 hours of surgery as tolerated under the physiotherapist's supervision. There was no incidence of wound complications like dehiscence, delayed healing, or discharge. None of the cases had superficial or deep infections.

Among the 15 patients under follow-up, the mean MEPS score was 64.3 at the end of one year follow up, which improved to 73.6 by the end of four years follow-up. With MEPS scoring system seven patients in the series had 'Good or Excellent' results, six had 'Fair' results and two patients ended up with poor functional outcome by the end of four years.



Fig. 1: Different sizes of metallic mono-bloc prosthesis for radial head.

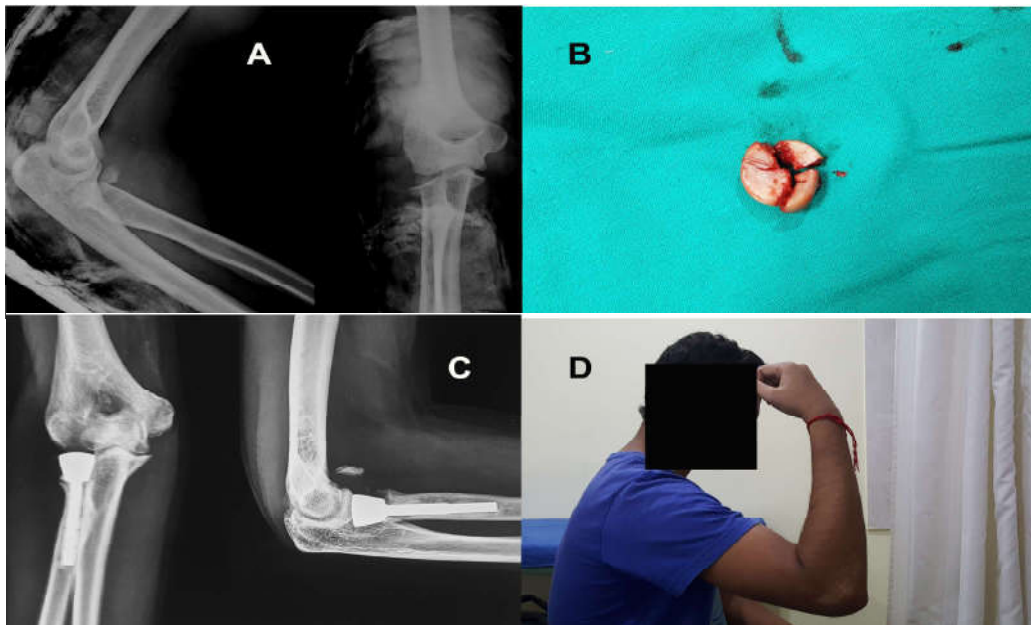


Fig. 1: A, Mason type III fracture of the right radial head; B, Excised fragments of the radial head; C, Follow-up radiograph of the elbow showing the prosthesis in place; D, Flexion achieved in the operated elbow after two years follow-up.

### Discussion

The most widely used classification for radial head fractures is the Mason classification, dividing these into three classes. Broberg and Morrey added a fourth type to this original classification by including the radial head fractures associated with dislocation. Later, Hotchkiss modified the Mason classification by elaborating on the details of the injuries, to make it more useful in surgical decision making.<sup>7</sup> Current practice is to surgically treat the comminuted radial head fractures (Mason type III) by either internal fixation, excision or prosthetic

replacement.<sup>2</sup> But opinions vary among researchers regarding the choice of the surgical plan.

Fixation of comminuted radial head fractures can be incredibly challenging with unpredictable results.<sup>1,3,5</sup> Sometimes even very meticulously done osteosynthesis may end up in symptomatic malunion, instability and elbow stiffness.<sup>1</sup> Radial head resection has gained popularity as a simple method for treatment of isolated fractures with comminution; but it is known to alter elbow biomechanics even without the presence of collateral injuries.<sup>5,8</sup> But it can have disastrous outcomes

in cases having medial ligament insufficiency and in axial instability.<sup>2,3,8-10</sup> Reliable diagnosis of associated instability may not be possible always in a traumatic elbow. But approximately 75% of patients with Mason type III radial head fractures may have associated fractures or ligament injuries.<sup>5</sup> Terrible triad injuries are examples of such complex scenario where, excision of the radial head may lead to significant disability.

Many studies in English literature have described their experiences with radial head replacement surgery using a prosthesis.<sup>1-5,8-11</sup> There are few studies comparing the radial head replacement with internal fixation or with radial head resection. Various types of prostheses have been studied; silastic prostheses earned disrepute by giving rise to silicone synovitis and inability to sustain the load transferred through the radio-capitellar joint due to its elastic nature.<sup>4</sup> Metallic prostheses come primarily of cemented or cement-less press-fit types. They can be also made with mono-polar or bipolar designs. The bipolar designs are theoretically believed to articulate better with the capitellum and therefore may prevent arthritic changes. But, on the other hand they are considered inferior in stability and have higher dislocation rates.<sup>5</sup> Cases of component dislodgement and synovitis due to component erosion has also been described by many authors using the bipolar prosthesis. Monobloc designs give better stability to the lateral pillar of elbow, although they may be responsible for articular erosion involving the capitellum leading to arthropathies. But there are also research publications claiming higher arthritic rates in patients with Bipolar prostheses compared to Mono-polar cases.<sup>2</sup> Loosening of the prosthesis can be a troublesome issue following radial head replacement. Therefore, cemented and cement-less press-fit implants have been preferred by surgeons. Both designs of implants have been used with varied outcomes.

Our study describes our experience with cemented mono-bloc radial head prostheses over a medium duration follow-up. Although mono-bloc prostheses are considered to be difficult for insertion, we did not find any significant record of such problems arising per-operatively.

Outcomes have been observed to be better in patients who underwent early replacement of the radial heads, compared to those who had it late or in neglected cases. But it is also opined that these difference in outcomes have more to do with the condition of the elbow at the time of intervention, rather than the actual time of surgical

intervention.<sup>2</sup> It is only natural to believe that a neglected or inadequately managed elbow injury is more likely to have deformities, stiffness, and myositis ossificans, which may have a bearing on the final outcome. In our series the elbow function as evaluated by the MEPS score was also found to be inferior in patients who were operated beyond three weeks following injury.

Lately we have been following the protocol for replacing all the Mason Type III radial head fractures in our cases, as it may be difficult to establish the degree of instability of the anterior or medial aspect of elbows during assessment at the time of initial presentation. Although a magnetic resonance imaging (MRI) scan could be handy in diagnosing the osseo-ligamentous injuries, it is not possible in most cases due to financial constraints. In our series, most of the patients had good and fair functional results after around one-year follow-up following radial head replacement. Although the elbow motion was not ideal, but patients were reasonably happy considering the severity of the injuries.

The various weaknesses in our study are, limited number of cases, short duration of follow-up and unavailability of a control group.

## Conclusion

With our mid-term results we are inclined to conclude that, radial head replacement using cemented mono-bloc prosthesis is a good treatment option for the management of comminuted Mason Type III radial head fractures. It is a relatively easy and reproducible technique. Early intervention with carefully selected patients can result in predictable clinical and functional results.

## References

1. Carita E, Donadelli A, Cugola L, et al. Radial head prosthesis: Results overview. *MusculoskeletSurg* (2017) 101 (Suppl 2): S197-S204.
2. Katthagen JC, Jensen G, Lill H, et al. Monobloc radial head prostheses in complex elbow injuries: results after primary and secondary implantation. *Int Orthop*. 2013 April; 37(4): 631-9.
3. Bonneville N. Radial head replacement in adults in recent fractures. *OrthopTraumatolSurg Res*. 2016 Feb; 102 (1 Suppl):S69-79.
4. Maghen Y, Leo AJ, Hsu JW, Housman MR. Is a silastic radial head still a reasonable option? *Clin OrthopRelat Res* (2011) 469:1061-1070.

5. Allavena C, Delclaux S, Bonneville N, et al. Outcome of bipolar radial head prosthesis to treat complex radial head fractures in 22 patients with a mean follow-up of 50 months. *OrthopTraumatolSurg Res.* 2014 Nov; 107:703–9.
  6. Moon JG, Hong JH, Bither N, et al. Can ulnar variance be used to detect overstuffing after radial head arthroplasty? *Clin OrthopRelat Res.* (2014) 472: 727–731.
  7. Iannuzzi NP, Leopold SS. The Mason classification of radial head fractures. *Clin OrthopRelat Res* (2012) 470:1799–1802.
  8. Unlu MC, Guven MF, Aslan L, et al. Comparison of the functional results of radial head resection and prosthesis for irreparable Mason type III fracture. *Ulus TravmaAcilCerrahiDerg* 2018 Jul;24(4):359-363.
  9. Liu R, Liu P, Shu H, et al. Comparison of primary radial head replacement and ORIF (Open reduction and internal fixation) in Mason type III fractures: A retrospective evaluation in 72 elderly patients. *Med Sci Monit.* 2015; 21: 90–93.
  10. Tarallo L, Mugnai R, Rocchi M, et al. Mason type III radial head fractures treated by anatomic radial head arthroplasty: Is this a safe treatment option? *OrthopTraumatolSurg Res.* 103 (2017):183–189.
  11. Nestorson J, Josefsson PO, Adolfson L. A radial head prosthesis appears to be unnecessary in Mason type IV fracture dislocation. *Acta Orthopaedica* 2017; 88(3): 315–319.
-