

# Bilateral Presence of the Gastrocnemius Tertius: A Case Report

Sandeep Madhukar Lahange<sup>1</sup>, Vikash Bhatnagar<sup>2</sup>, Archana Bhangare<sup>3</sup>

## How to cite this article:

Sandeep Madhukar Lahange, Vikash Bhatnagar, Archana Bhangare/Bilateral Presence of the Gastrocnemius Tertius: A Case Report/Indian J Anat. 2023;12(2):77-81.

## Abstract

The Gastrocnemius muscle is a fusiform, two headed, two joint muscle. The two heads of origin are lateral and medial head taking origin from medial and lateral condyles of femur respectively. In between the two heads tibial nerve passes. Inferiorly it forms a common tendon with the Soleus and Plantaris muscles; this tendon is known as the Tendocalcaneus or Achilles tendon which get inserted to posterior surface of Calcaneum. The case was reported during routine dissection for undergraduate B.A.M.S. students at National Institute of Ayurveda Deemed University, Jaipur. The subject was 36-year-old male cadaver of North Indian origin. The accessory head was observed during the cadaveric dissection of the popliteal fossa.

The Gastrocnemius muscle was bulky. The inferolateral and inferomedial boundary of the Popliteal fossa were made by medial and lateral head of Gastrocnemius. In addition to the normal medial and lateral head an accessory head of Gastrocnemius was seen bilaterally. The accessory head (Gastrocnemius tertius) having two bellies, superficial and deep were observed in the both lower extremity. The superficial belly of the Gastrocnemius tertius muscle had its origin from an area just above the tendon of the plantaris muscle, the deep belly from the tendon of the plantaris muscle and inserted to the lateral head of the Gastrocnemius muscle. All the heads were innervated by branches from tibial nerve. It is possible that this variant muscle could have a compressive effect on the tibial nerve and popliteal vessels, and the awareness of this may prevent its misinterpretation as a pathological structure by radiologists and surgeons.

**Keywords:** Gastrocnemius; Plantaris; Gastrocnemius Tertius; Calcaneus; Tendocalcaneus.

---

**Author's Affiliation:** <sup>1,2</sup>Associate Professor, Department of Sharir Rachana, National Institute of Ayurveda (Deemed University), Jaipur 302002, Rajasthan, India, <sup>3</sup>Associate Professor, Department of Balaroga, Mahatma Jyotiba Fule Ayurved College, Chomu, Jaipur 303702, Rajasthan, India.

**Corresponding Author: Vikash Bhatnagar,** Associate Professor, Department of Balaroga, Mahatma Jyotiba Fule Ayurved College, Chomu, Jaipur 303702, Rajasthan, India.

**E-mail:** shailjavikas@gmail.com

**Received on:** 08.02.2023

**Accepted on:** 12.03.2023

## INTRODUCTION

The Gastrocnemius, Plantaris and Soleus muscles are important for leg functions and they form a muscular mass in the calf. Both of them show numerous variations in the origin and/or insertion. The variation of the Gastrocnemius tertius (GCT) has been reported by many authors, however, there is very less report on their bilateral existence. In this study we discussed bilateral existence of the

Gastrocnemius tertius muscles from phylogenetical, anatomical and clinical points of view.

The Gastrocnemius muscle is a fusiform, twoheaded, two joint muscle. It is most superficial muscle of the flexor compartment of leg and forms belly of the calf. Along with the Soleus this muscles forms triceps surae of the calf. The Gastrocnemius arises by two lateral and medial heads attached to condyles of the femur by strong, flat tendons. The medial larger head is attached to depression at upper and posterior part of medial condyle behind adductor tubercle and area on popliteal surface of femur. The lateral head is attached to area on lateral surface of lateral condyle and lower part of supracondylar line.<sup>1</sup> The two heads come together at the inferior margin of the popliteal fossa, where they form the inferolateral and inferomedial boundaries of the popliteal fossa. The tendinous attachments expand to cover posterior surface of each head with an aponeurosis, from anterior surface of which muscle fibers arise.

As muscle descends, muscle fibers begin to insert into broad aponeurosis, which contracts and receives tendon of soleus on its deep surface to form Calcaneal or Achilles tendon.<sup>2</sup> Gastrocnemius is supplied by tibial nerve. It is supplied by its own Sural artery. These arteries are branches of popliteal artery. This muscle helps in plantar flexion. It is common to have additional muscles or muscle slips in the extremities. Some of them may compress the nerves and vessels or restrict the movements, while others may enhance the muscular activity. However, a small number of them may go unnoticed. Knowledge of such variant muscles becomes important for plastic surgeons while performing various reconstructive surgeries and for clinicians while managing the pain.<sup>3</sup>

## MATERIALS AND METHODS

During routine dissection of approximately 36-year-old male cadaver of North Indian origin, an accessory head of Gastrocnemius along lateral side with bipennate arrangement of the muscle fibers in the both lower limb were observed during routine dissection for undergraduate B.A.M.S. students at Department of Rachana Sharir, National Institute of Ayurveda Deemed University, Jaipur.

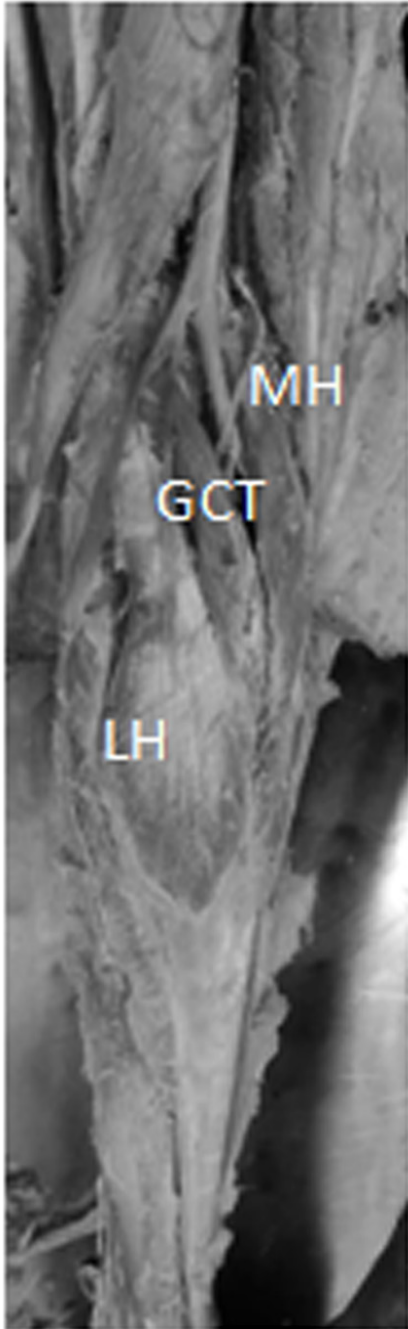
## CASE DESCRIPTION

While doing cadaveric dissection it was observed that the Gastrocnemius muscle was very bulky. Along with lateral and medial heads of origin of Gastrocnemius, making inferolateral and inferomedial boundary of the Popliteal Fossa an accessory head was seen on lateral side in both lower extremity. The accessory head was originating from the lateral condyle of femur and adjoining part of the lateral supracondylar line as shown in the Fig. 1 and Fig. 2. The lateral head was originating from the lateral condyle of femur. The medial head had a single head originating from medial condyle of femur and medial supracondylar line. The tibial nerve was placed between the accessory head and medial head. All the heads of the muscle remained separate near their origin and fused to form tendocalcaneus tendon in the lower half of leg.

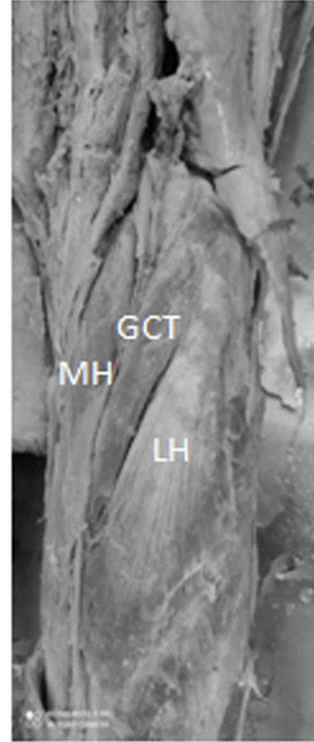Another interesting observation found in this accessory head was the bipennate arrangement of fleshy fibers. All the heads were innervated by the branches of tibial nerve and supplied by popliteal vessels. The plantaris was seen taking origin from lateral condyle of femur and was placed between the Gastrocnemius and Soleus, separating the two muscles. The tendon of plantaris was also seen to joining tendocalcaneus tendon. Both sides of the calves were normal in every aspect except for these variant muscles.<sup>4</sup>

## LEFT SIDE OBSERVATIONS

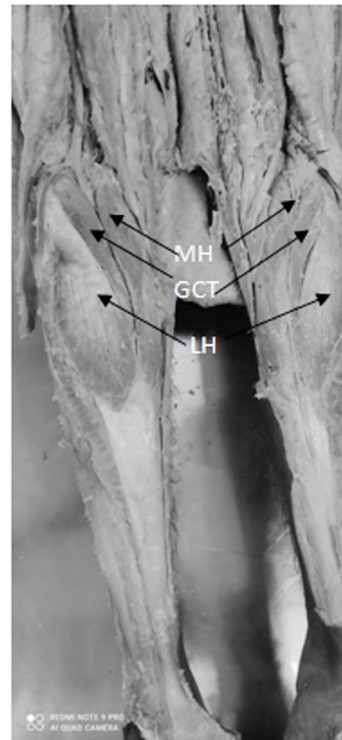
In this side, a two bellied Gastrocnemius tertius muscle was observed. The superficial belly of the Gastrocnemius tertius muscle had its origin from an area just above the tendon of the plantaris muscle, and the deep belly had its origin from the tendon of the plantaris muscle itself (Fig. 1). The superficial belly of the Gastrocnemius tertius muscle inserted onto the outer surface of the lateral head of the Gastrocnemius muscle after crossing the surface, the deep one inserted onto the inner surface of the medial head of the Gastrocnemius muscle. The lateral and medial heads of the Gastrocnemius muscle were normal in every aspect.



**Fig. 1:** Shows the appearance of the Gastrocnemius Tertius muscle in the left side of the case. LH - lateral head of the Gastrocnemius muscle; MH- Medial head of the Gastrocnemius muscle; GCT - Gastrocnemius Tertius.



**Fig. 2:** Shows the Gastrocnemius Tertius muscle in the right side of the case. LH - lateral head of the Gastrocnemius muscle; MH - Medial head of the Gastrocnemius muscle; GCT - Gastrocnemius Tertius.



**Fig. 3:** Shows the Appearance of the Gastrocnemius Tertius muscle in both right and left side of the case. LH - lateral head of Gastrocnemius muscle, MH - Medial head of the Gastrocnemius muscle, GCT - Gastrocnemius Tertius.

### RIGHT SIDE OBSERVATIONS

In this side, a Gastrocnemius tertius muscle was observed between the lateral and medial heads of the Gastrocnemius muscle (Fig. 2). It had its origin from the lateral condyle of the femur, and inserted to the medial head of the Gastrocnemius muscle.

## DISCUSSION

Gastrocnemius is a superficial muscle of the calf which normally arises by two heads, from the Condyles of the femur. The medial larger head is attached to the medial Condyle and the lateral head is attached to lateral surface of the lateral Condyle and corresponding supracondylar line. Some fibers of both the heads also arise from subjacent part of the Genicular capsule. Normally, the tendinous attachments expand to cover the posterior surface of each head with an aponeurosis. From the anterior surface of this aponeurosis, the fleshy muscle fibers arise. The fleshy muscle fibers of the medial head extend lower than those of the lateral head. Below, the muscle fibers insert into a broad aponeurosis; till such point the muscular masses of two heads remain separate. The aponeurosis gradually narrows and is joined by the tendon of soleus and Plantaris on its deep surface to form the tendocalcaneus. Gastrocnemius is supplied by the branches of tibial nerve and popliteal artery. Presence of additional heads and other variations of the muscle is very rare. It has been mentioned that occasionally lateral head or whole muscle can be absent. Kelch is the first to describe the third head. Its overall frequency ranges from 1.7% to 5.5%. Phylogenetically, the Gastrocnemius muscle has been considered a muscle of the fibular side of the leg. It comes from the Calcaneum blastomere and follows an ascending migration towards the inferior femoral epiphysis. The third head may arise from the long head of biceps femoris muscle, linea aspera, lateral femoral epicondyle, knee joint capsule, or the fascia of leg. It may split and arise from more than one region or divide near its termination to join both heads of Gastrocnemius. A rare variation where an unusual muscle that leaves the belly of semitendinosus and ends in the tendon that joins the fascia of leg is described as Tensor fasciasuralis /Ischioaponeuroticus.<sup>5</sup> Padmalatha et al. also reported Tensor Fascia Suralis that formed a thin tendon distally merging with the intratendinous fibers of medial and lateral heads of Gastrocnemius muscle.<sup>6</sup> Singh et al. have reported a case where both lateral and medial heads of Gastrocnemius were found to be fleshy in their entire length and were getting inserted to the calcaneum directly without forming the tendocalcaneus.<sup>7</sup> The third head (Caput tertium) is variation of the Gastrocnemius muscle, also described as Gastrocnemius tertius seen in CT scans by Bergman.<sup>8</sup> Ramandeep Kaur et al found that addition to the normal medial and lateral head an accessory head of gastrocnemius having bipennate arrangement of the muscle

fibers was observed in the left lower limb.<sup>9</sup> Gupta and Bhagwat found that variations in muscles are quite common and frequently seen during routine dissection of cadavers. Many or most variations are totally benign; some are errors of embryologic developmental timing or persistence of an embryologic condition. Some of these variations may seriously compromise parts of the muscular, vascular, nervous, and skeletal or organ systems.<sup>10</sup> Koplak et al. carried out a prospective study of 1039 consecutive knee magnetic resonance (MR) examinations, of which 20 (1.9%) demonstrated an anomalous third head of gastrocnemius muscle which was seen arising near the midline of the posterior distal femur, between the mid and medial aspect, and joining the medial aspect of the lateral head of the Gastrocnemius. In all of these patients, the third head coursed lateral to the popliteal vessels and none coursed between the vessels.<sup>11</sup> Somayaji et al. have cited in their literature a case of an anomalous muscle which originated from the semimembranosus and biceps femoris muscles and then inserted into the superficial surface of the tendocalcaneus.<sup>12</sup> The plantaris muscle itself can be considered a third head, and may join/merge with medial or lateral heads of Gastrocnemius muscle.<sup>13</sup> Thus, it is advocated that the plantaris muscle is a derivative of the deeper portion of the lateral head of the Gastrocnemius muscle. Yildirim et al. have described in their report the co-existence of the bilateral Gastrocnemius tertius and accessory Soleus muscles in the same cadaver. They have extensively elaborated the potential problem for structures in the popliteal fossa due to these variants. The third head joining the medial head of the Gastrocnemius muscle is most commonly cited as causing clinical problems like entrapment syndromes. The characteristic signs and symptoms include leg pain, tenderness in the popliteal fossa and decreased pulsations of the distal arteries.<sup>14</sup>

## CONCLUSION

Having considered the literature available and on comparing the present case, we come to the conclusion that this case is one of the third/ accessory head of Gastrocnemius muscle, originating from the Popliteal surface of femur and attached distally to the junction of the medial and lateral heads of the Gastrocnemius. It is possible that this variant muscle could have a compressive effect on the tibial nerve and popliteal vessels, and that the awareness of this may prevent its misinterpretation as a pathological structure by radiologists and surgeon during diagnosis and

management of related clinical conditions. It is also important for academicians for purpose to demonstrate the scholars as variation of Gastrocnemius muscle.

**Conflict of interest:** No

**Acknowledgement:** Professor Sanjeev Sharma, head of the department and vice-chancellor, National Institute of Ayurveda Deemed University, Jaipur.

## REFERENCES

1. Williams A. Pelvic Girdle and Lower limb . In: Standring S, editor. Gray's Anatomy: The Anatomical basis of clinical practice: 39th edition. Philadelphia: Churchill Livingstone Elsevier; 1999. pp 1499.
2. Moore K L; Agur A M, Dalley A F. Essential Clinical Anatomy: 4th edition. Baltimore: Lippincott Williams & Wilkins; 2011. pp. 363, 365.
3. Standring S, Borley NR, Collins P, Crossman AR, Gatzoulis MA, Healy JC. Gray's Anatomy: The anatomical basis of clinical practice: 40th edition., London: Elsevier, Churchill Livingstone; 2008; pp1420-21.
4. Yildirim FB, Sarikcioglu L, Nakajima K. The co-existence of the gastrocnemius tertius and accessory soleus muscles. J Korean Med Sci. 2011 Oct; 26(10):1378-81. doi: 10.3346/jkms.2011.26.10.1378. Epub 2011 Oct 1. PMID: 22022193; PMCID: PMC3192352.
5. Bergman R A; Thompson S A, Afifi A K, Saadeh F. A. Compendium of human anatomical variation: Baltimore: Urban and Schwarzenberg, 1988; pp. 7,23-4.
6. Padmalatha K, Prakash B S, Mamatha Y, Ramesh B. Ischioaponeuroticus/tensor fascia suralis. Int. J. Anat. Var.2011; 4:104-5.
7. Singh G, Agrawal VP, Basavarajappa M, Manohar M. Gastrocnemius - Achilles tendon: a human anatomical variation. Int J Biomed Adv Res. 2012; 3(08):653- 55.
8. Bergman R A, Walker CW. el-Khour G Y. The third head of gastrocnemius in CT images. Ann. Anat. 1995; 177(3):291-4.
9. Ramandeep Kaur, Anshu Sharma, Mahesh Kumar Sharma. A Case Report of A Variant Head of Gastrocnemius. Int J Anat Res 2018;6(3.1):5420-5423. DOI: 10.16965/ijar.2018.221.
10. Gupta R K. Bhagwat S S. An anomalous muscle in the region of the popliteal fossa: A case report. J. Anat. Soc. India .2006; 55(2):65-8.
11. Koplak M C. Grooff P. Piraino D. Recht M. Third head of the gastrocnemius: an MR imaging study based on 1039 consecutive knee examinations. Skeletal Radiol. 2009; 38(4):349-54.
12. Somayaji S N, Vincent R, Bairy K L. An anomalous muscle in the region of the popliteal fossa: case report. J. Anat. 1998; 192 ( 2):307-8.
13. Upasna & Kumar, A. Bicipital origin of plantaris muscle—a case Report. Int. J. Anat. Var. 2011; 4:177-9.
14. Yildirim F B. Sarikcioglu, L. Nakajima K. The coexistence of the gastrocnemius tertius and accessory soleus muscles. J. Korean Med. Sci. 2011; 26(10):1378-81.

