

A Case Report of an Accidental Diagnosis of the Coarctation of Aorta in 44 Year Old Male

Deep Hasamukhbhai Jolapara¹, Sandeep B gore²

How to cite this article:

Deep Hasamukhbhai Jolapara, Sandeep B gore/A Case Report of an Accidental Diagnosis of the Coarctation of Aorta in 44 Year Old Male/Indian J Emerg Med 2022;8(4):139-142.

Author's Affiliation: ¹Senior Resident, ²Director and Head, Department of Emergency Medicine, Fortis Hospital, Mulund Mumbai 400080, Maharashtra, India.

Corresponding Author: Sandeep B Gore, Director and Head, Emergency Medicine Department, Fortis Hospital, Mulund Mumbai 400080, Maharashtra, India.

E-mail: dr.sandeepbgore@gmail.com

Received on: 18.07.2022

Accepted on: 19.08.2022

Abstract

Introduction

Coarctation the aorta is typically thought to be a childhood disease and very rarely present in adults. However, emergency medicine physicians must keep a broad differential diagnosis when faced with a young or elder patient with signs and symptoms of acute congestive heart failure.

Case Report

We report a case of a previously healthy male patient who presented to the emergency department with sudden onset of palpitation and ascending pain through lower extremities associated with giddiness and headache. The patient was examined and diagnosed with coarctation of the aorta. Management with interventional procedure was done and patient improved with symptomatic relief.

Discussion

Coarctation of the aorta in adults are asymptomatic until an insidious injury occurs and will typically present with rare complains.

Conclusion

This case demonstrates the importance of considering advanced imaging as a useful diagnostic tool and importance of early interventional procedure to improve outcome of the patient.

Keywords: Gourd shaped appearance; Post stenotic dilation; Percutaneous catheter balloon dilation with stent placement; Blood pressure difference between the upper and lower extremities and pulse delay; Case report.

INTRODUCTION

Coarctation of the aorta is narrowing or constriction of the lumen of the aorta may occur anywhere along its length but its most common distal to origin of the left subclavian artery near the insertion of the ligamentum arteriosum. Coarctation occurs in 7% of patients with coronary heart disease, is more common in males than females, and is particularly frequent in patients with gonadal dysgenesis (e.g. Turner's syndrome).¹ Aortic coarctation presenting during adult life most frequently represents cases of recoarctation following previous transcatheter or surgical therapy, or missed cases of native coarctation.² Clinical manifestations depend on the site and extent of obstruction and the presence of associated cardiac anomalies, most commonly a bicuspid aortic valve.

CASE REPORT

A 44 year old male present to emergency department with complain of sudden onset of palpitation and ascending pain through lower

extremities associated with one episode of giddiness and headache for the last two hours. Patient has no co-morbidities and no significant past medical or surgical history.

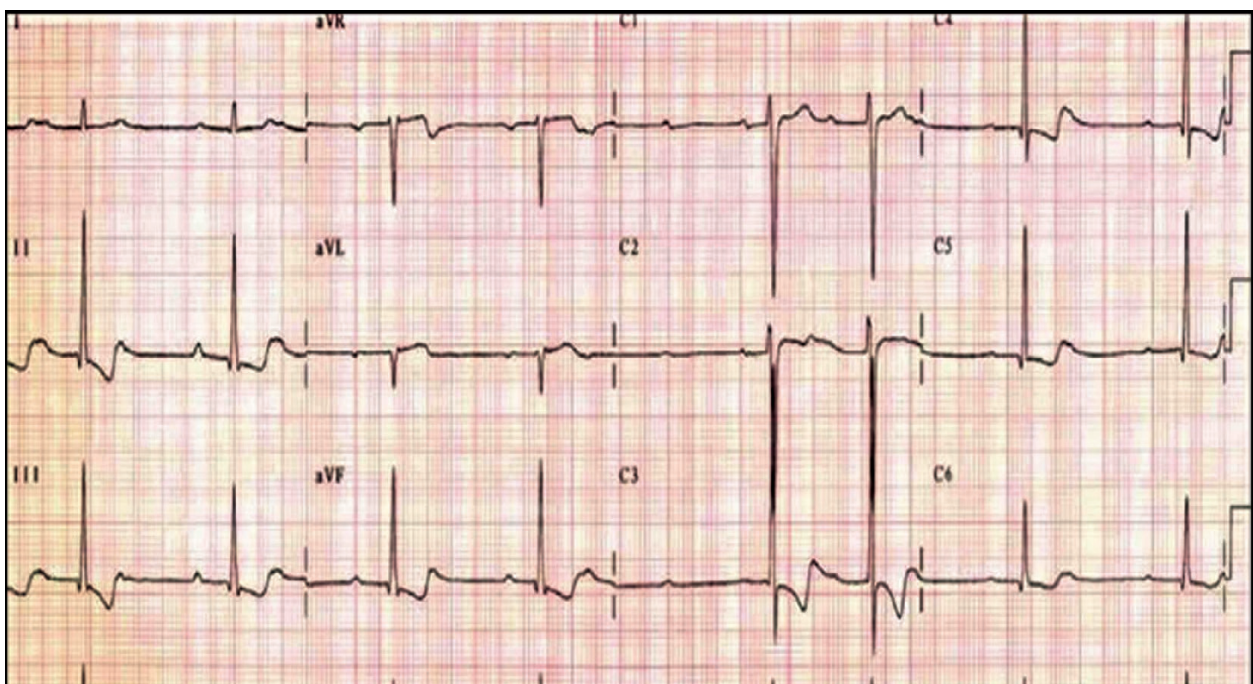
On Examination

- Temperature: 98.6 degree Fahrenheit
- Heart Rate: 68/minute
- Left radial pulse is slightly weaker than right radial pulse
- Delayed pulsation of femoral arteries
- Blood Pressure:
 - On left hand: 140/80 mmHg
 - On right hand: 170/100 mmHg
- Oxygen saturation: 98% without oxygen support
- Random Blood Sugar: 116 mg/dl
- Cardiovascular system: Normal S1 and S2 is heard
- Respiratory system: Chest clear with bilateral normal vesicular breath sound
- Per abdomen: Soft and non-tender
- Central nervous system: No focal neurological deficits

Investigations

- **Electrocardiogram (ECG):**

T wave inversion in lead I, II, aVL, v2-v6.

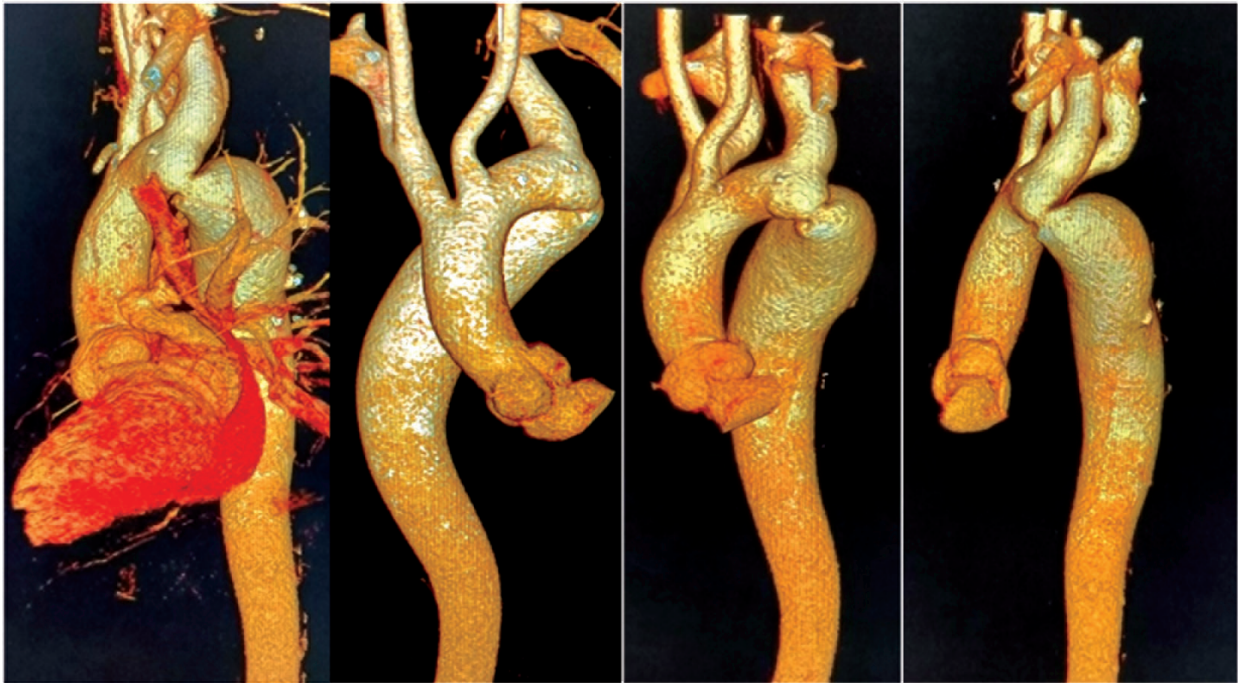

12 Lead ECG - T wave inversion in Lead I,II,aVL,V2-V6

- Higher Sensitive Troponin I:
Positive 79.3 ng/L (Normal: 28.9 – 39.2)
- Portable Bed Side 2D ECHO Screening:
In suprasternal window: Descending aortic constriction located distal to the left subclavian

artery presents a gourd shaped appearance.

- CT Aortogram:
Coarcted segment is seen after the origin of left subclavian artery with post stenotic dilation. Collaterals are seen draining into the descending aorta.



Coarcted segment and Post stenotic dilation

MANAGEMENT

Patient was given a single dose of diuretics (Furosemide 40 milligram intravenous) in the emergency department and shifted to ICU and then taken for percutaneous catheter balloon dilation with stent placement. Patient tolerated surgery very well. Patient improved symptomatically and was discharged with oral medications.

DISCUSSION

Coarctation of the aorta in adults accounts for 0.2% of all hypertension cases in adults.³ Mostly, adults with coarctation are asymptomatic until an insidious injury occurs and will typically present with acute heart failure, spinal complications, hypertensive crisis or aortic complications.⁴

Aortic coarctation manifests as childhood hypertension, lower extremity fatigue or weakness, diminished lower extremity pulses and/or congestive heart failure. Diagnosis is usually based

on clinical suspicion and physical findings.⁵ The latter include blood pressure difference between the upper and lower extremities and pulse delay.

Most children and young adults with isolated, discrete coarctation are asymptomatic. Headache, epistaxis, chest pressure and claudication with exercise may occur and attention is usually directed to the cardiovascular system when a heart murmur or hypertension in the upper extremities and absence, marked diminution or delayed pulsations in the femoral arteries are detected on physical examination. Enlarged and pulsatile collateral vessels may be palpated in the intercostal spaces anteriorly, in the axillae or posteriorly in the interscapular area. The upper extremities and thorax may be more developed than the lower extremities.¹

A midsystolic murmur over the left interscapular space may become continuous if the lumen is narrowed sufficiently to result in a high velocity jet across the lesion throughout the cardiac cycle. Additional systolic and continuous murmurs

over the lateral thoracic wall may reflect increased flow through dilated and tortuous collateral vessels.¹

The ECG usually reveals Left Ventricular hypertrophy. Chest x-ray may show a dilated left subclavian artery high on the left mediastinal border and a dilated ascending aorta. Indentation of the aorta at the site of coarctation and pre and post stenotic dilatation (the "3" sign) along the left paramediastinal shadow is essentially pathognomonic.¹

Management of previously undiagnosed coarctation of aorta in adults varies based primarily on the stability of the patient and severity of the lesion. Cardiac catheterization was once frequently used for the diagnosis of coarctation of aorta but is now reserved for therapeutic interventions.⁶ The American college of Cardiology and American Heart Association recommended intervention in adults with coarctation of aorta in the following settings: when a peak to peak coarctation gradient greater or equal 20 mmHg or peak to peak coarctation gradient less than 20 mmHg with imaging evidence of significant coarctation and radiographic evidence of collateral flow.⁷

Late post-operative systemic hypertension in the absence of residual coarctation is related partly to the duration of preoperative hypertension. Follow up of rest and exercise blood pressure is important; may have systolic hypertension only during exercise, in part due to a diffuse vasculopathy and to noncompliance of the stented or surgically reconstructed region. All operated or stented coarctation patients deserve a high quality MRI or CT procedure in follow up.¹

Death in these patients is usually due to heart failure, coronary artery disease, aortic rupture/dissection, concomitant aortic valve disease, infective endarteritis/endocarditis, or cerebral haemorrhage.⁸

CONCLUSION

Coarctation of the aorta, considered among the most care providers as a paediatric issues, can present at any age. In adult patients there can be a little evidence of the pathology until the need for emergent care. Thought this disease process is seen infrequently at best, it is important for the practising doctors to use the physical examination skills learned early in their education, as specially to check blood pressure and pulse in all four limbs independently and also importance of considering advanced imaging as a useful diagnostic tool.

Key Words

gourd shaped appearance, post stenotic dilation, percutaneous catheter balloon dilation with stent placement, blood pressure difference between the upper and lower extremities and pulse delay, case report.

Abbreviation

1. e.g. = *exempli gratia*
2. mmHg = millimeters of mercury
3. mg/dl = Milligrams per decilitre
4. ng/L = Nanograms per liter
5. ICU = Intensive Care Unit
6. CT = computed tomography
7. MRI = Magnetic resonance imaging

REFERENCES

1. Harrison's Principle of Internal Medicine 19th edition, pp.1525.
2. R.Jurcut, A.M. Daraban, A. Lorber et al, "Coarctation of the aorta in adults: what is the best treatment? Case report and literature review." *Journal of Medicine and Life*, vol.4, no.2, pp.19-195,2011.
3. L.M. Prisant, K. Mawulawde, D. Kapoor, C. Joe et al, "Coarctation of the aorta: secondary cause of hypertension", *Journal of clinical hypertension (Greenwich, Conn.)*, Vol.6, no.6, pp.347-352,2004.
4. R. hazukova, E. Cermakova, M. Pleskot, and R. Hazukova, "Frequencies of emergencies in adults due to unrecognized coarctation of the aorta", *Anatolian Journal of Cardiology/ Anadolu Kardiyoloji Dergisi*, Vol.16, No.1, pp.10-14, 2016.
5. Warnes CA and Deanfield JE. Congenital Heart disease in adults. In: Alexander RW, Hurst's The Heart Vol.2, 11th edition. New York: McGraw Hill Professional; 2004:1866.
6. R.D. Torok, "Coarctation of the aorta: Management from infancy to adulthood", *World Journal of Cardiology*, Vol.7, No.11, p.765, 2015.
7. C.A. Warnes, R.G. William, T.M. Bashore et al, "ACC/AHA 2008 guidelines for the management of adults with congenital heart disease: a report of the American Heart Association / American College of Cardiology Task force on practice Guidelines", *Circulation*, Vol.118, no.23, pp.e714-e833, 2008.
8. Campbell M. Natural history of coarctation of the aorta. *Br Heart J* 1970, 32:633-640. Jenkins NP, Ward AR. Coarctation the aorta: natural history and outcome after surgical treatment. *QJM* 1999, 92:365-371.