

## A Comparative Study of Dexmedetomidine as Adjuvant to 0.5% Bupivacaine in Erector Spinae Plane Block for Perioperative Analgesia in Patients Undergoing Percutaneous Nephrolithotomy

Sampreeta S Reddy<sup>1</sup>, Swati Bisht<sup>2</sup>

**Author's Affiliation:** <sup>1</sup>Junior Resident, <sup>2</sup>Professor, Department of Anaesthesiology, Vydehi institute of medical sciences and research centre, Whitefield, Bengaluru 560066, Karnataka.

### Abstract

**Context:** Patients undergoing percutaneous nephrolithotomy (PCNL) experience considerable post-operative pain. Perioperative pain control for PCNL using regional anaesthesia techniques like erector spinae plane block (ESPB) helps in better outcome in terms of pain, fentanyl requirement. It also indirectly helps in faster recovery and early discharge from hospital.

**Aims:** To assess and compare perioperative pain control provided by ESPB with 0.5% bupivacaine and dexmedetomidine as adjuvant to it.

**Settings and Design:** This randomized case control study was undertaken in a tertiary care centre. 60 patients planned for elective unilateral PCNL over a period of 15 months. Patients were randomized into two groups (Group B and group D) using envelope method. Patients were compared for fentanyl consumption, duration and effectiveness of analgesia obtained.

**Methods and Materials:** ESPB was administered pre operatively under ultrasound guidance at the level of 10th thoracic vertebrae. Needle tip was visualised above transverse process of 10th thoracic vertebra. Position was confirmed by hydro dissection on injecting normal saline under ultrasound and drug was injected. Patients were assessed for pain at specific time intervals. Total opioid consumption was noted. Data obtained was recorded and analysed.

**Statistical analysis used:** Statistical analysis was performed by SPSS software v.23.0. One-way analysis of variance, Bonferroni correction, Chi square test was used. P value of <0.05 was considered statistically significant.

**Results:** Dexmedetomidine as adjuvant to local anaesthetic agent improves the quality and prolongs the duration of analgesia. It also decreases total fentanyl consumption.

**Conclusion:** ESPB provides adequate analgesia for PCNL. Addition of dexmedetomidine decreases fentanyl and sevoflurane consumption meanwhile increasing duration of analgesia.

**Key words:** Erector spinae plane block; Dexmedetomidine 0.5 %; Bupivacaine; Peri operative analgesia.

**Key message:** Ultrasound guided pre-emptive single shot ESPB with dexmedetomidine as adjuvant to 0.5% bupivacaine provides good analgesia, reduces total opioid consumption and facilitates rapid recovery.

### How to cite this article:

Sampreeta S Reddy, Swati Bisht/A Comparative Study of Dexmedetomidine as Adjuvant to 0.5% Bupivacaine in Erector Spinae Plane Block for Perioperative Analgesia in Patients Undergoing Percutaneous Nephrolithotomy/ Indian J Anesth Analg. 2021;8(2):233-237.

**Corresponding Author: Sampreeta S Reddy**, Junior Resident, Department of Anaesthesiology, Vydehi institute of medical sciences and research centre, Whitefield, Bengaluru 560066, Karnataka, India.

**E-mail:** [sampreeta.royal@gmail.com](mailto:sampreeta.royal@gmail.com)

## Introduction

PCNL is a minimally invasive endoscopic urosurgical procedure of choice for renal calculi of >2cm, staghorn calculi and multiple calculi.<sup>1</sup> Although PCNL is a minimally invasive procedure, it is associated with considerable pain caused by percutaneous tract, distension of pelvicalyceal system and Gerota's fascia with irrigation fluid and placement of nephrostomy tubes. As with any other surgeries, management of surgery related pain is important in PCNL. Optimal dynamic analgesia, preferably non opioid analgesia is a crucial component in enhanced recovery, length of hospital stay and reversion to daily activities as it also avoids nausea, vomiting and constipation associated with opioids.<sup>2</sup>

Practice of regional anaesthesia techniques have significantly evolved after introduction of ultrasound. Ultrasound guided ESPB is a newly described peri paravertebral regional anaesthesia technique by Forero et al as novel and simple interfascial plane block for thoracic neuropathic pain.<sup>3</sup> Since its description, it has been compared with different regional anaesthetic techniques and is being studied pain management in different surgeries.<sup>4,5</sup> ESPB is reported to be easier, safe in administration and providing extensive and potent analgesia with minimal expectable complications.<sup>6</sup>

Dexmedetomidine, a selective alpha 2 agonist, has been found to have additive effect with local anaesthetic agents by increasing duration of action. Hence it is added as adjuvant for local anaesthetic agent to assess and compare the efficacy and duration of analgesia in this study.

Through this study, we intended to study the efficacy of dexmedetomidine as adjuvant to 0.5% bupivacaine in ultrasound guided single shot pre-emptive ESPB in terms of duration of analgesia, fentanyl and inhalational agent consumption in patients undergoing elective unilateral PCNL.

## Methodology

This study was conducted in a tertiary care centre. Institutional ethics committee approval was obtained for the single blinded randomized case control study. 60 patients of American society of Anaesthesiologists (ASA) physical status 1 and 2, aged between 18 to 60 years, undergoing elective unilateral PCNL were enrolled for the study. Patients with deranged coagulation profile, deranged renal function, allergy to local anaesthetic agent, active infection at injection site, spine deformities or the patients who refused ESPB were

excluded from the study. Informed written consent was obtained from all participants. Thorough pre anaesthetic evaluation was done for all the patients. They were educated on visual analogue scale (VAS) scoring system for assessment of pain. Patients were randomized into two groups (group B and group D) using sealed envelope method. Pre operatively, patients were kept nil per orally (NPO) for at least 6 hours. During NPO period, patients were hydrated with intravenous fluids as per body weight. Patients were premedicated with injection pantoprazole sodium 40mg on the morning of surgery.

Pre-operatively patient was connected to standard cardiac monitors and was put on right lateral position. For ESPB, skin at the site of procedure was prepared with 5% povidone iodine and 70% isopropyl alcohol. Sterile drapers were covered. A high frequency linear ultrasound transducer [Siemens ACUSON freestyle TM, Germany] was used. Spinous process of 9th thoracic vertebra was palpated and scanned at the corresponding level transverse process of 10th thoracic vertebra was located by moving the probe laterally by 3cm from the midline. The probe was then rotated by 90 degrees clockwise. Skin, subcutaneous tissue, trapezius and erector spinae muscles were identified. [ Figure 1] A 22G 80mm facet type sonotap needle [Pajunk, Geisingen, Germany] was introduced in-line cephalocaudally till the needle tip is at the transverse process below erector spinae muscles. Location of needle tip is confirmed by visible hydro dissection on injecting normal saline.

Group B patients received 2mg/kg of 0.5% Bupivacaine. Group D patients received 1mcg/kg dexmedetomidine and 2mg/kg 0.5% bupivacaine. Injection of drug was considered as time T0 and patient was monitored hemodynamically.

General anaesthesia for PCNL in both the groups followed same technique. Patients were pre medicated with glycopyrrolate 0.005mg/kg, midazolam 0.02mg/kg, ondansetron 0.1mg/kg IV. Pre oxygenation with 100% oxygen followed by induction with fentanyl citrate 2mcg/kg, propofol 2mg/kg and atracurium besylate 0.5mg/kg IV. Fentanyl citrate 0.5mcg/kg IV was repeated after every 60minutes and atracurium besylate 0.1mg/kg IV as required. Post-surgery, residual neuromuscular blockade was reversed using neostigmine methyl sulphate 0.05mg/kg and glycopyrrolate 0.01mg/kg IV.

Post operatively patients were assessed for presence and severity of pain during rest and on

cough, total fentanyl requirement and presence of side effects like nausea, vomiting, bradycardia, hypotension, shivering, pruritis etc. Patient was assessed regularly at 2nd hourly interval for first 24 hours and 6th hourly thereafter. VAS score more than 4 was considered as intolerable pain and rescue analgesics like paracetamol 1g IV and diclofenac sodium 75mg in 100ml normal saline were administered.

**Results**

All characteristics were summarized descriptively. For continuous variables, the summary statistics of mean± standard deviation (SD) were used. For categorical data, the number and percentage were used in the data summaries and diagrammatic presentation. Chi-square ( $\chi^2$ ) test was used for association between two categorical variables. The difference of the means of analysis variables between two independent groups was tested by unpaired t test. If the p-value was <0.05, then the results were considered to be statistically significant otherwise it was considered as not statistically significant. Data were analyzed using SPSS software v.23.0. and Microsoft office 2007.

**Table 1:** Comparison of study groups in terms of various demographic parameters considered in the study.

Parameters	Groups		P values
	B	D	
Age (years)	40.90 ± 10.59	38.73 ± 11.82	0.714
Gender	18:12	16:14	
[Male: Female] (%)	(60%: 40%)	(53.3%:46.7%)	1.000
ASA PS [I:II] (%)	16:14 (53.3%:46.7%)	18:12 (60%: 40%)	1.000
Duration of surgery (Mins) (mean ± SD)	83.17 ± 17.39	81.67 ± 16.63	0.977

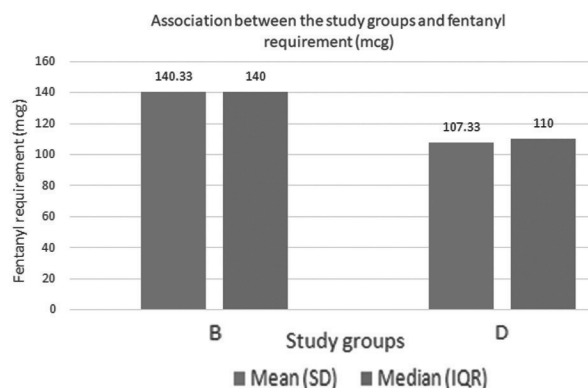
**Table 2:** Comparison of study groups in terms of fentanyl requirement and duration of analgesia.

Parameters	Groups		P values
	B	D	
Fentanyl Required (mcg) Mean ± SD	140.33 ± 37.55	107.33 ± 17.80	<0.001
Time to first complaint of pain (min) Mean ± SD	178.00 (28.33)	274.00 (150.05)	<0.001

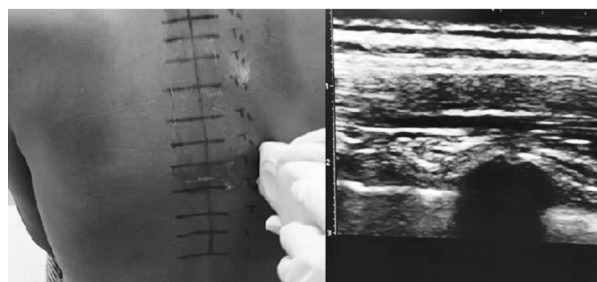
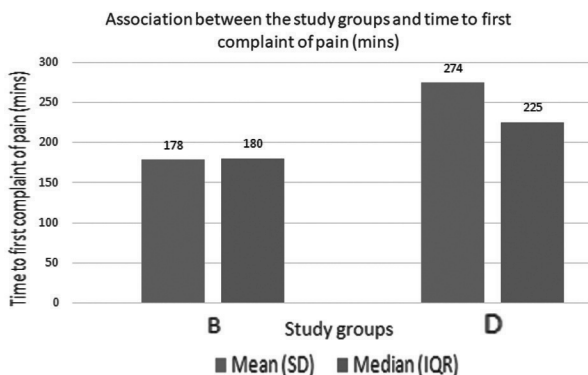
A total of 60 patients (30 patients in each group) were recruited and all completed the study. The demographic profile such as age and gender distribution were expressed as mean and standard deviation and both groups were comparable. There was no statistically significant difference among

two groups with regard to distribution of ASA physical status 1 and 2 patients, hemodynamic variations and duration of surgery. [Table 1] There was a highly significant statistical variation in regards to the duration of analgesia and opioid requirement in both the groups with p value <0.05. [Table 2, Graph 1 and graph 2]

**Graph 1:** Mean and median of fentanyl requirement (mcg) and association between study groups.



**Graph 2:** Mean and median of time to first complaint of pain (mins) and association between study groups.



**Fig. 1:** Image showing surface and ultrasound anatomy of erector spinae muscles at T10 vertebral level.

In group D, 2 patients developed hypotension intraoperatively which was corrected by administration of ephedrine hydrochloride 6mg IV. In group D, 3 patients developed nausea post operatively for which ondansetron 0.1mg/kg IV was administered. None of these complications

were observed in group B patients. Patients in group D required less dose of fentanyl citrate intra and post operatively. Duration of analgesia was prolonged and patients required lesser rescue analgesic agents and was statistically significant.

## Discussion

Three muscle bundles namely iliocostalis, longissimus and spinalis together form Erector spinae muscle. They extend bilaterally from spinous process to ribs and the skull to the sacral region and pelvis. It supports the spine in erect posture and is an anti-gravity muscle.<sup>7</sup>

Erector spinae plane block (ESPB) was first described by Forero et al in 2016 as the block administered by injecting the local anaesthetic agent below erector spinae muscle layer and above the transverse process.<sup>3</sup> The drug administered is assumed to produce combined effect of paravertebral, neuraxial, intercostal and retro laminar blocks. It acts both on dorsal and ventral primary rami by interfascial spread. Main mechanism of action is assumed to be the spread towards dorsal primary rami and into paravertebral space.

Patient should either be positioned in sitting or in lateral decubitus or in prone position. The spinous process of 7th cervical vertebra is the most prominent. Hence, the spinous processes can be counted down till the level required to provide analgesia for different surgeries. It is also seen that the drug administered spreads craniocaudally. So, the site of injection should ideally be kept the midpoint of the required level of analgesia. In this study, the block was administered in patients undergoing PCNL. Hence, spinous process of 9th thoracic vertebra was marked which corresponds to transverse process of 10th thoracic vertebra.

The ultrasoundprobe should be placed horizontally on the midline on marked spinous process. Here it was 9th thoracic spinous process. The probe should be moved 2-3 cm laterally to locate transverse process and rotated 90 degree clockwise. In lower thoracic level, only two layers of muscles that is, trapezius and erector spinae muscles can be identified above hump like transverse process of vertebra. At costovertebral junction, the appearance of hump like projection changes to rounded acoustic shadows.<sup>8</sup> The needle should be inserted inline cephalocaudally till the needle tip is visualised at the transverse process. Local anaesthetic agent should be injected on confirming the hydro dissection.

Ultrasound guided regional anaesthesia techniques are safe and accurate in avoiding complications like intravascular injections and nerve injury. Usage of ultrasound also greatly reduces the quantity of drug used in the block.<sup>8</sup>

Dexmedetomidine is a centrally acting selective alpha 2 agonist. It mediates antinociceptive signals via peripheral alpha 2 adrenoreceptors. It results in activation of rectifying potassium channels leading to hyperpolarization of membrane thus decreasing excitability.<sup>9</sup>

In this study, we studied intraoperative and post-operative effects of dexmedetomidine as adjuvant to 0.5% bupivacaine in ultrasound guided single shot pre-emptive erector spinae plane block. Local anaesthetic agents like bupivacaine provide good analgesia for about 4 to 6 hours when used solely in single shot techniques. To prolong the duration, catheter placement and addition of adjuvants are the options. Catheter placement has it's own disadvantages like misplacement, migration and infections etc. Best method to improve the quality and duration of analgesia is by adding opioid or non-opioid adjuvant and comparatively with minimal and predictable complications. Usage of IV opioids and no steroidal anti-inflammatory agents have side effects like sedation, nausea, vomiting, constipation and respiratory depression etc

Regional anaesthesia techniques if used along with other modalities of analgesia, produces excellent pain control intra and post operatively. It reduced the opioid agent requirement intra operatively. It also reduces the pain and morbidity post operatively. ESPB administration for PCNL, showed possibility of early mobilization of patients. This indirectly reduced the duration of hospital stay and expenses for the patients.

ESPB is safer and easier. Complications like motor block and pleural injury were not encountered in our study. The limitations of the study are non-inclusion of paediatric and geriatric patients, exclusion of patients with co morbid conditions and also measurement of plasma levels of drugs are not done.

To conclude, ESPB provides good analgesia in patients undergoing PCNL. Addition of dexmedetomidine as adjuvant to bupivacaine increased the quality of block. Hence it can be included as one of the multimodal analgesic techniques followed under enhanced recovery protocols.

## References

1. Kim E, Kwon W, Oh S, Bang S. The Erector Spinae Plane Block for Postoperative Analgesia after Percutaneous Nephrolithotomy. *Chin Med J* 2018;131:1877-8.
2. Sun EC, Darnall BD, Baker LC, et al. Incidence of and risk factors for chronic opioid use among opioid-naïve patients in postoperative period. *JAMA Intern Med* 2016;176:1286-93.
3. Forero M, Adhikary SD, Lopez H, Tsui C, Chin KJ. The erector spinae plane block: a novel analgesic technique in thoracic neuropathic pain. *Reg Anesth Pain Med* 2016;41:621-7.
4. Nagaraja PS, Raghavendran S, Singh NG, Asia O, Bhavya G, Manjunath N et al. Comparison of continuous thoracic epidural analgesia with bilateral erector spinae plane block for perioperative pain management in cardiac surgery. *Ann Card Anaesth* 2018;21:323-7.
5. ElHawary H, Abdelhamid K, Meng F, Janis JE. Erector Spinae Plane Block decreases Pain and Opioid Consumption in Breast Surgery: Systemic Review. *Plast Reconstr Surg Glob Open*. 2019 Nov 20;7(11):e2525.
6. Krishnan S, Cascella M. Erector Spinae Plane Bloc. 2020 Jul 4. In: StatPearls [internet]. Treasure Island (FL): StatPearls Publishing; 2020 Jan.
7. The back. *Gray's Anatomy*. 40th ed. Spain: Elsevier;2008.p.707-48.
8. Pharmacology and ultrasound. Maheshwari K, Brown DL, Mounir Soliman L. *Brown's atlas of regional anesthesia*. 5th ed. Spain: Elsevier; 2017.p.3-16.
9. Gandhi R, Shah A, Patel I. Use of dexmedetomidine along with bupivacaine for brachial plexus block. *Natl J Med Res*. 2012;2:67-69.

