

## Surface Mould Brachytherapy Boost in Carcinoma Palate: Challenges on the Road to a Better Therapeutic Ratio

Sahaj Palod<sup>1</sup>, Virendra Bhandari<sup>2</sup>, Mahendran C<sup>3</sup>, Sarolkar Anil<sup>4</sup>, Aafreen Khan<sup>5</sup>

**Author's Affiliation:** <sup>1</sup>Registrar, <sup>2</sup>Professor, <sup>3</sup>Medical Physicist, <sup>4</sup>Associate Professor, Department of Radiation Oncology, Sri Aurobindo Institute of Medical Sciences and PGI, Indore, Madhya Pradesh 453555, India.

**Corresponding Author:** Virendra Bhandari, Professor, Department of Radiation Oncology, Sri Aurobindo Institute of Medical Sciences and PGI, Indore, Madhya Pradesh 453555, India.

**E-mail:** virencancer@yahoo.co.in

### How to cite this article:

Sahaj Palod, Virendra Bhandari, Mahendran C et al. Surface Mould Brachytherapy Boost in Carcinoma Palate: Challenges on the Road to a Better Therapeutic Ratio. Indian J Canc Educ Res 2020;8(1):23-27.

### Abstract

*Purpose:* Surface mould brachytherapy in oral cancers particularly, cancer of palate is an indispensable modality in dose escalation of irradiation. It also offers the advantage of high localized dose and shorter treatment time. The rapid dose fall off beyond the source having radioactivity provides with greater tumor control probability and lesser normal tissue complication probability, resulting in higher therapeutic ratio. Image guided brachytherapy has aided in this cause of radiation oncologists. However, to achieve this target the treating oncologist has to overcome many challenges through individualistic approach in treatment of each patient. In this article, we are sharing our institutional experiences regarding the challenges faced in treatment of carcinoma palate surface mould brachytherapy and possible solutions to overcome these challenges.

*Materials and Methods:* Five patients of squamous cell carcinoma palate (T2-3, N0) who attended our institute were included in our study for radical treatment by irradiation. All patients were given a dose of 50 Gray (Gy) in 25 fractions (#) by external beam radiation therapy (EBRT). Then assessment was done by a team of radiation oncologist, medical physicist and prosthodontist for feasibility of boost by preparation of surface mould brachytherapy. The challenges faced were noted and improvisations were done as needed.

*Conclusion:* Surface mould brachytherapy has created its special place in optimal care of patients of carcinoma palate. The skills needed to treat the patient by this modality can be always acquired and challenges can be overcome by modifications done keeping in mind the basic brachytherapy principles. The radiation oncologists should offer the patient with this modality with high therapeutic ratio for optimal patient care.

**Keywords:** Surface mould brachytherapy; Carcinoma palate.

### Introduction

#### *Purpose*

Brachytherapy in oral cavity cancers have acquired a special place in terms of dose escalation without decreasing the therapeutic ratio. Its property of inverse square law results in rapid dose falls off and also shortened treatment time.<sup>1</sup> It has been used as a single modality as well as boost in radical

treatment setting. High dose Rate (HDR) units allow the treating radiation oncologist to deliver the dose in shorter treatment times.<sup>2</sup> Brachytherapy application requires multidisciplinary approach and expertise right from the patient selection up to treatment execution. In this article, we have shared our institutional experiences in form of the challenges faced and the possible solutions to counteract them.

## Materials and Methods

Five patients of biopsy proven squamous cell carcinoma palate (T3, N0) were treated at our institute from May 2017 to May 2018 by surface mould brachytherapy boost post external beam radiation therapy (EBRT). The dose given by EBRT was 50 Gray (Gy) in 25 fractions (#) at rate of 2Gy per fraction over a period of 5 weeks. Then assessment of patients was done by a team of radiation oncologist, medical physicist and prosthodontist. The patients fit and ready were taken up for boost by Surface mould brachytherapy. Rest patients were treated by boost by EBRT. The dose given by brachytherapy boost was 3Gy per # for 5 # 6 hours apart twice daily. The total dose planned was 66Gy equivalent dose (EQD2) by either of the modalities.

### Procedure workflow

- The patients were evaluated by the prosthodontist for the anatomy, lesion localization and status of the oral cavity. This assessment aids in the orientation of mould preparation.
- Dental and oral prophylaxis was done of the patients before preparation of impression.
- Impression of the mandibular and maxillary arches was taken and the cast was created as shown in Figure 1 (a) and (b).
- Then markings of the area to be treated were drawn on the cast with a marker with respect to the clinical reference of the lesion as shown in Figure 2 (a).
- Infant feeding tubes of one smaller diameter fitted inside one larger diameter tubes were used, to act as channels for carrying the wires containing the radioactive source.
- The infant feeding tubes were adhered to the cast using an adhesive and then cast fabrication was done.
- The cast was assessed and approved by radiation oncologist along with medical physicist.
- The cast was then placed inside the oral cavity of the patient and then metallic wires made up of lead or copper were inserted in the carrier tubes.

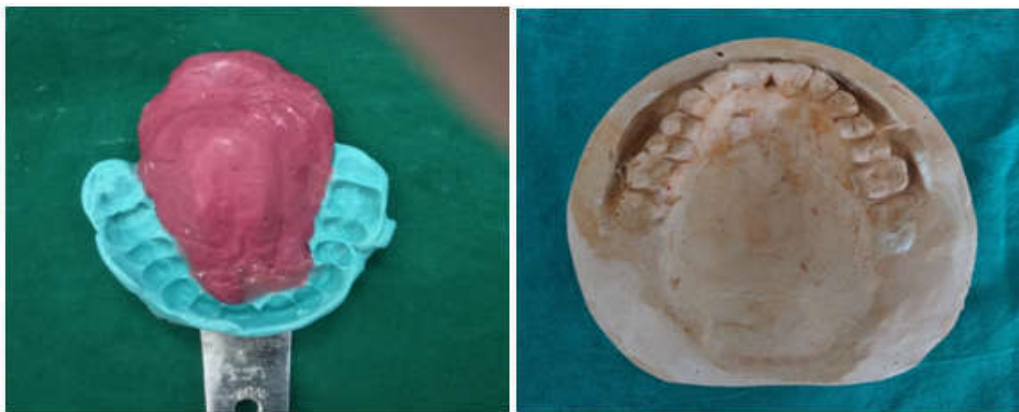


Fig. 1: (a) Impression of the maxillary arch, (b) Cast after preparation (From left to right)

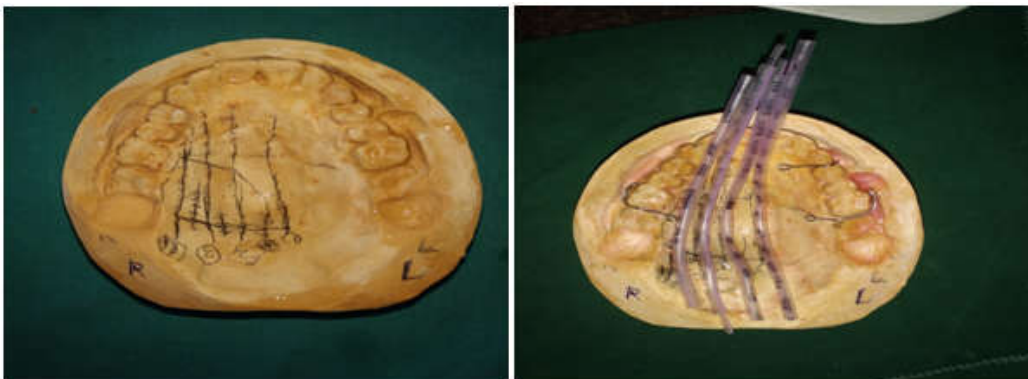
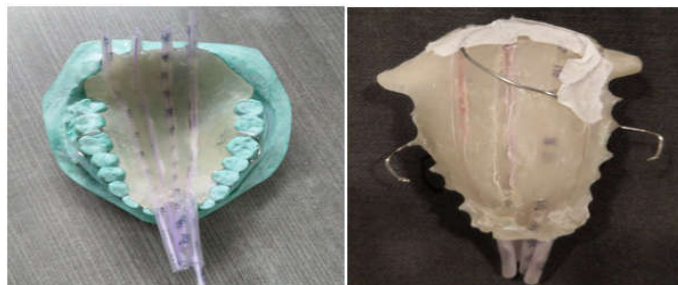
Fig. 2: (a) Markings of the carrier tubes on the cast, (b) Infant feeding tubes assessment

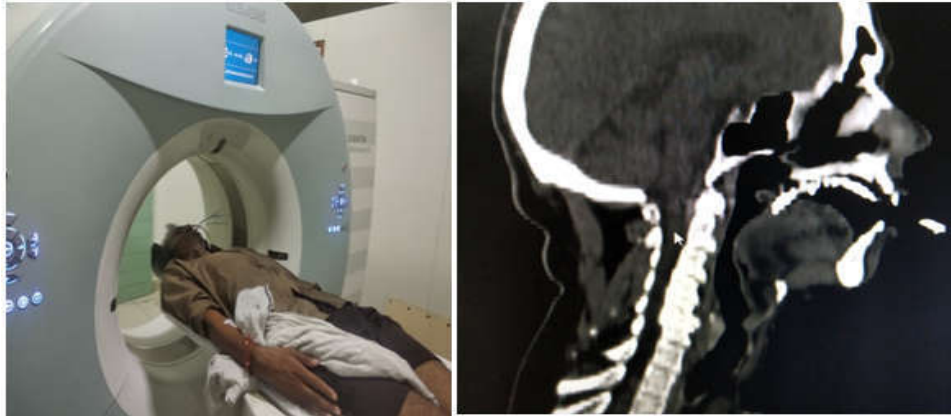- The Computed tomography (CT) scan of neck was done in supine position with the carrier mould fitted inside the oral cavity.
- CT scan slices of 1 to 1.25 mm were prepared on the Siemens definition AS scanner (Siemens Medical System, Germany).
- The images were transferred to the treatment planning system (TPS) and registration was done.
- Then contouring of planning target volume (PTV) and organ at risk (OAR) was done.
- The patients were planned for the dose of 3Gy per # for total five #, twice daily 6 hours apart after dose optimization.
- The patient was made to lie in the brachytherapy treatment room and then transfer tubes were connected with the HDR cobalt 60 source brachytherapy machine (Eckert and Ziegler BEBIG, Germany).
- The treatment execution was done in presence of radiation oncologist, technologist, medical physicist and prosthodontist.
- *Challenge:* The anatomical considerations of patient's oral cavity such as high arched palate, posterior most location of tumor and decreased mouth opening posed as a challenge to the prosthodontist.
- ❖ *Solution:* Careful assessment of the patient was done by multidisciplinary approach by a team of radiation oncologist, medical physicist and prosthodontist. Newer techniques for dental impression and cast preparation were adopted by the prosthodontist.
- *Challenge:* The delineation of the growth margins after initial EBRT was difficult due to clinical response (reduction in size).
- ❖ *Solution:* Serial drawings and photographs of patient were taken during the EBRT and then the delineation of growth was done on the cast with help of a marker.
- *Challenge:* The selection of infant feeding tubes of appropriate diameter as to easily carry the guide wire along with radioactive source.
- ❖ *Solution:* Multiple diameters infant feeding tubes were tested by inserting the guide wires through them and the tubes were selected accordingly. The tube of diameter 2.7 mm was found to be most appropriate for our use.
- *Challenge:* The maintenance of patency of the feeding carrier tubes throughout the cast preparation.
- ❖ *Solution:* The patency of the carrier tubes were maintained by use of smaller diameter tube which was kept inside the tube of larger diameter to keep it patent as shown in Figure 3 (a).
- *Challenge:* The assessment of carrier mould fitted inside the oral cavity of the patient as to eliminate air gaps or tube obstruction if present.

#### *Challenges faced and the solutions applied throughout the treatment procedure*

- *Challenge:* Patients were slightly reluctant and apprehensive for surface mould brachytherapy as they were acclimatized to treatment by EBRT for 5 weeks.
- ❖ *Solution:* Patients were counseled and explained the nature of treatment modality along with emphasis on use of this treatment modality over EBRT.
- *Challenge:* The patient's compliance with respect to instructions regarding mouth opening exercises was very poor.
- ❖ *Solution:* Patients were assessed twice weekly for treatment related side effects along with special emphasis on mouth opening exercise and a device if necessary.



**Fig. 3:** (a) smaller tubes inside larger tubes, (b) Disease being marked by lead wire on the carrier mould



**Fig. 4:** (a) Patient undergoing CT simulation with mould carrier in situ, b) Sagittal view of CT scan showing no air gaps

- ❖ *Solution:* The clinical assessment of the fitting of carrier mould was done clinically and modified if not found in concordance with patient anatomy.
- *Challenge:* Presence of air gap visualized on the planning CT scan.
- ❖ *Solution:* The simulation CT scans taken after fitting the mould inside the patient's oral cavity were repeated in case of air gaps found between the mould and the treatment site as shown in Figure 4 (a) and (b).
- *Challenge:* The correlation of the channel number on the planning CT scan with the actual number on the planning CT scan.
- ❖ *Solution:* The lead wire from one channel was curled and thus it was traced and numbered on the planning CT scan as shown in Figure 3 (b).
- *Challenge:* The delineation of the growth and the carrier tubes placement as visible on the planning CT scan with conventional slice thickness of 3 mm.
- ❖ *Solution:* The CT scan done for simulation was taken of slice thickness of 1 to 1.25 mm for better visualization of the channels to aid in treatment planning. The growth extent was also marked in the dorsal surface of the mould by a lead wire for better visualization.
- *Challenge:* The appropriate positioning of the patient in which treatment execution was to be done.
- ❖ *Solution:* The patient was positioned in left lateral position close to the brachytherapy machine so that the transfer tubes are very well placed and have no obstruction whatsoever.
- *Challenge:* The kinking of the carrier guide wires or tubes due to compression by central incisor teeth.
- ❖ *Solution:* The patient was asked to refrain from putting pressure on the guide wires and appropriate positioning was done to prevent the compression.
- *Challenge:* Treatment interruptions due to obstruction in the guide carrier tubes.
- ❖ *Solution:* Guide wires were re-checked manually before each fraction delivery.
- *Challenge:* Reproduction of the treatment daily under same conditions.
- ❖ *Solution:* In case of obstruction in the carrier tube in spite of manual checking and the necessary steps in correction of mould are done and re-planning done.

## Discussion

Surface mould brachytherapy is an indispensable modality for treatment of cancers of palate as sole and as boost modality.<sup>3</sup> It offers us the liberty of dose escalation to the local disease site with minimal doses to the organs at risk, thus improving the therapeutic ratio.<sup>1</sup> The paucity of brachytherapy equipped centers along with lack of skillful resources and expertise restricts its use routinely. Many studies have shown its cost effectiveness over the EBRT which is being delivered with aid of linear accelerators.<sup>4</sup> Head and neck brachytherapy warrants attention to detail in the treatment planning and execution. This article describes our institutional experience with this treatment modality. The challenges described in this article are some of the practical aspects which have

taken been applied under the umbrella of basic understanding of the brachytherapy principles.

### Conclusion

Surface mould brachytherapy in squamous cell carcinoma palate has long established its role as an imperative modality as it gives as the desired therapeutic ratio. The challenges faced along the road to this therapeutic road can be overcome and boost our desire to give the patient optimal care.

### References

1. Mazeron JJ, Ardiet JM, Haie-Méder C et al. GEC-ESTRO recommendations for brachytherapy for head and neck squamous cell carcinomas. *Radiother Oncol* 2009;91:150-56.
2. Pham A, Arora S, Wernicke G et al. Cesium-131 brachytherapy in high risk and recurrent head and neck cancers: first report of long-term outcomes. *J Contemp Brachytherapy* 2015;7:445-52.
3. Budrukkar A, Dasgupta A, Pandit P et al. Clinical outcomes with high-dose-rate surface mould brachytherapy for intra-oral and skin malignancies involving head and neck region. *J Contemp Brachytherapy* 2017;9:242-50.
4. Ealla KKR, Prakash SKC, Mani danappanavar P, et al. Treatment of Stage I Hard Palate Cancer with High-Dose-Rate Brachytherapy Using Molds: Cost-Based Perspective. *J Pharm Bioallied* 2019;11:S67-S71.