

Carcinoma Gall Bladder With Metastasis To Calveria: A Rare Case Report

Sahaj Palod¹, Anil Sarolkar², Tauseef Ali³, Vivek Kanthed⁴, Virendra Bhandari⁵

Author's Affiliation: ^{1,3}Registrar, ²Associate Professor, ⁵Professor, Department of Radiation Oncology, ⁴Registrar, Department of Pathology, Sri Aurobindo Medical College and PG Institute, Indore, Madhya Pradesh 453555, India.

Corresponding Author: Virendra Bhandari, Professor, Department of Radiation Oncology, Sri Aurobindo Medical College and PG Institute, Indore, Madhya Pradesh 453555, India.

E-mail: virencancer@yahoo.co.in

How to cite this article:

Sahaj Palod, Anil Sarolkar, Tauseef Ali et al. Carcinoma Gall Bladder With Metastasis To Calveria: A Rare Case Report. Indian J Canc Educ Res 2020;8(1):53-55.

Abstract

This case report describes a rare case of carcinoma gall bladder metastasizing to calverium (skull bone). This is an unusual site of metastasis in a patient of carcinoma gall bladder.

Keywords: Gall Bladder , Calveria Metastasis

Introduction

Carcinoma gallbladder is the fifth most common entity amongst the malignancies of gastrointestinal (GI) tract. It accounts for 1.2% of all cancers occurring all over the world and accounting for 165,000 deaths due to cancer which is about 1.7%.^{1,2} The most common site for metastasis is liver and amongst extra abdominal sites is lung. Bones are amongst the rare site of metastasis.³ We are reporting a case of carcinoma gall bladder with metastasis to liver initially and then spreading to involve the calverium of skull bone. There have been only few case reports of such unusual presentation.

Case report

A 62 year old female presented to our institute with complaints of pain in abdomen and loss of appetite since 4 months. Clinical examination revealed pallor and hepatomegaly, 2 cm below the costal margin. An ultrasound (USG) abdomen was done which revealed 7.3x6 cm mass involving the gall bladder and liver. The CA 19-9 and serum alpha fetoprotein levels were 905.1 U/ml and

1.98 IU/ml respectively. Rest of the biochemical parameters was normal. A Computed tomography (CT) scan revealed a mass of 8x7x4.7 cm involving gall bladder and liver with lymph nodes of size 15x15 mm at porta hepatis. A USG guided fine needle aspiration cytology (FNAC) was done from the mass which revealed adenocarcinoma as shown in Figure 1(a) and (b). She was started on 5 fluorouracil (5FU) based chemotherapy. She received 3 cycles of chemotherapy; had good clinical response, then she defaulted. She reported at our institute after 6 months with same initial complaints and complaints of a painless scalp swelling since 20 days. There was no history of nausea, vomiting, headache or any central nervous system symptoms. The physical examination revealed hepatomegaly upto 5 cm below costal margin, tenderness in right hypochondrium and 4x3 cm size solid swelling with cystic areas located on temporal region on the right side as shown in Figure 2. The biochemical work up was done, which was normal. A chest x-ray was done which was normal and USG whole abdomen was done which revealed unclear gall bladder fossa and ill defined space occupying lesion in right lobe of liver with 2 small lesions in left lobe. Multiple lymph nodes

were seen at portal region largest measuring 40x20 mm. An X-ray of scalp was done which revealed a 4x3 cm size lesion on the scalp with erosion of the outer table of the calvarium with impending erosion of the inner table as shown in Figure 3 (a) and (b). An FNAC was done from the swelling

which revealed metastatic adenocarcinoma as shown in Figure 2(b). She was started on 5FU based chemotherapy again. The size of the swelling was reduced to 2x2 cm size after 3 more cycles of chemotherapy. She is currently reporting to our institution for subsequent chemotherapy cycles.

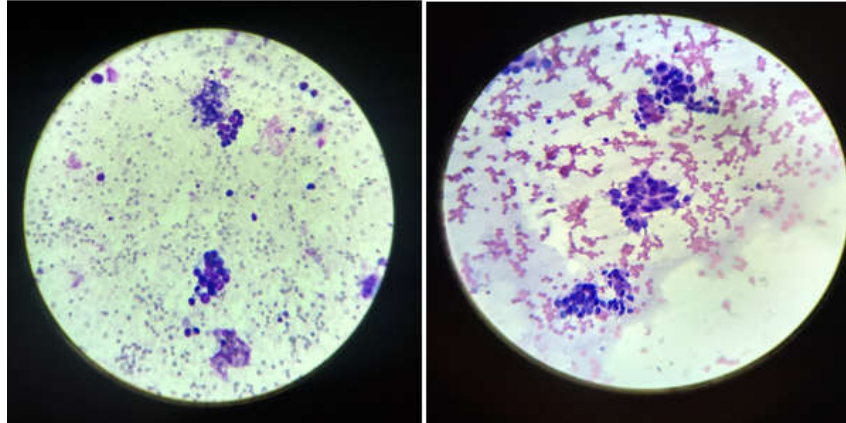


Fig. 1: Both FNAC slides showing atypical round to columnar cells with high nucleocytoplasmic ratio with hyperchromatic nuclei

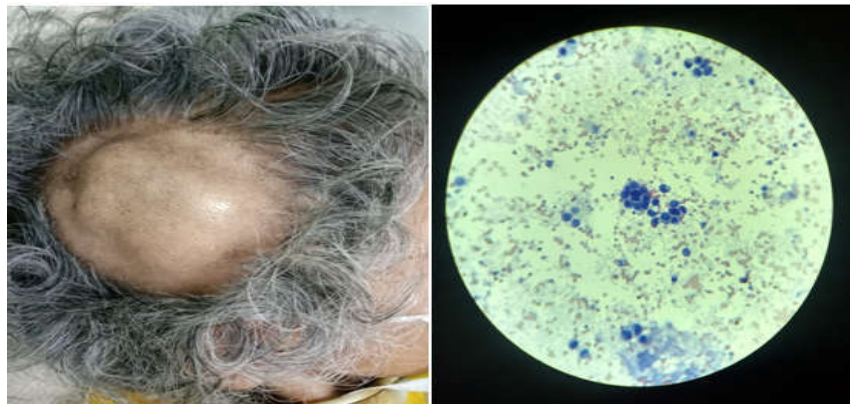


Fig. 2: A scalp swelling of size 4x3 cm (a), FNAC from scalp swelling showing picture of adenocarcinoma cells (b)

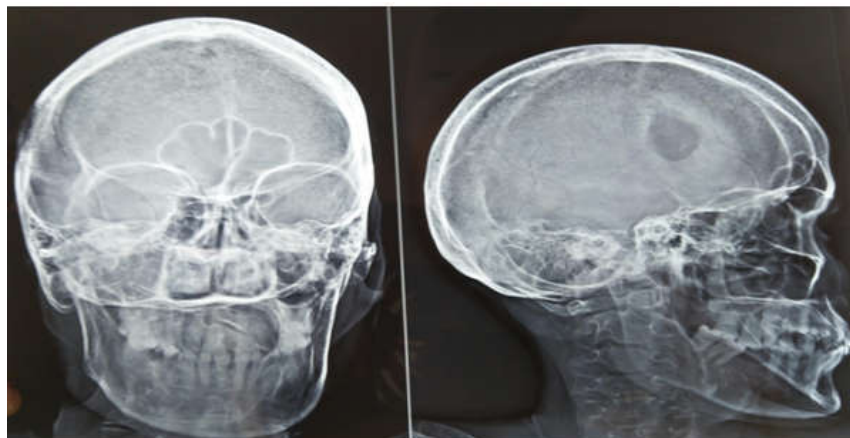

Fig. 3: A plain radiograph of skull showing skull bone erosion of outer skull table with impending erosion of inner table.

Discussion

Gall bladder cancer adenocarcinoma is a malignancy which presents commonly in advanced stages.⁴ This delay is amenable to the inability to differentiate the benign disease of gall bladder from its malignant counterpart. The most common mode of disease advancement is by direct extension to liver, adjacent organs and nodal metastasis.³ There are only five published cases of carcinoma gall bladder metastasizing to bone. The lesion found in skull bone in our case was osteolytic; however cases of osteoblastic lesions have also been reported.⁵ In the cases reported across literature, the scalp swelling was also found to be an initial complaint and underlying gall bladder malignancy was found after subsequent workup.⁶ In our patient, the scalp swelling developed when she had defaulted post chemotherapy. After investigating it was found to be a metastatic lesion at such a rare site along with involvement of liver. Thus, this case report throws light on the importance of complete physical examination along with consideration of gall bladder malignancy as differential for painless scalp swelling.

Conclusion

The incidence of bone metastasis in carcinoma gall bladder is already very low and this case reported metastasis to skull bone which is a rare phenomenon. There have been five cases previously published in the literature. These case reports raise the importance of full systemic examination with appropriate investigations to look for sites of

metastasis at unusual places. These unusual sites of metastasis may have been appearing due to survival improvement with judicious use of chemotherapeutic agents. Also, this case report is a way forward to further studies aimed at reporting incidence of bone metastasis in gallbladder malignancies to aid in optimal patient care.

Sources of support: NIL

Ethical Issues: NIL

Conflicting Interest: NIL

References

1. Bray F, Ferlay J, Soerjomataram I, et al. Global cancer statistics 2018: GLOBOCAN estimates of incidence and mortality worldwide for 36 cancers in 185 countries. *CA Cancer J Clin* 2018 Nov;68:394-424.
2. Rawla P, Sunkara T, Thandra KC et al. Epidemiology of gallbladder cancer. *Clin Exp Hepatol* 2019;5:93-102.
3. Kondo S, Nimura Y, Kamiya J et al Factors influencing postoperative hospital mortality and long term survival after radical resection for stage IV gallbladder carcinoma. *World J Surg* 2003;27:272-277.
4. Kalra N, Suri S, Gupta R, et al. MDCT in the staging of gallbladder carcinoma. *AJR Am J Roentgenol* 2006 Mar;186:758-62.
5. A Kumar, K Bhargava S, L Upreti, et al. Disseminated osteoblastic skeletal metastases from carcinoma of gallbladder a case report. *Indian J Radiol Imaging* 2003;13:37-9.
6. Gupta R, Singh M, Karmakar S, et al. Gallbladder cancer presenting with brain and bone metastasis: case report. *J Clin Diagn Res* 2015;9.