

## Case Series of Restoration of Osteochondral Defect in the Knee Using Autologous Chip Graft from Non Weight Bearing Site

S T Sanikop<sup>1</sup>, Irfan Dandharagi<sup>2</sup>

**Author Affiliation:** <sup>1,2</sup>Professor, Department of Orthopedics, Jawaharlal Nehru Medical College, Belagavi, Karnataka 590010, India.

**Corresponding Author:** S T Sanikop, Professor, Department of Orthopedics, Jawaharlal Nehru Medical College, Belagavi, Karnataka 590010, India.

**E-mail:** somortho@hotmail.com

### How to cite this article:

S T Sanikop, Irfan Dandharagi, Case Series of Restoration of Osteochondral defect in the Knee using Autologous Chip Graft from Non Weight Bearing Site. J orth. Edu. 2020;6(1):15–18.

### Abstract

*Context:* Osteochondral defect (OCD) of the articular cartilage of the knee is difficult to manage and leads to recurrent episodes of pain, stiffness and finally early onset osteoarthritis. The condition is common in young individuals and is often difficult to be identified by routine clinical examination and radiographs. Thus a high index of suspicion, advanced imaging or diagnostic arthroscopy is important. There are differing opinions regarding effective surgical management. Our study is a case series of management of osteochondral defect in the knee using autologous cartilage chip graft from non weight bearing site. *Aim:* To evaluate the clinical outcome role of surgical management of osteochondral injuries of knee with cartilage autograft from non-articular surfaces. *Settings and design:* Case series. Level of evidence IV. *Materials and methods:* A prospective clinical evaluation of 9 patients was done in Department of orthopaedics at the KLE'S Dr. Prabhakar Kore hospital & MRC, Belagavi. Patients in the age group of 18 to 50 years of either sex presenting to the out-patient department of orthopedics with features of suspected osteochondral defect of either knee were included. Nine cases that are fulfilling the inclusion/ exclusion criteria were selected. These patients were subjected to magnetic resonance imaging (MRI) with findings confirmed intraoperatively. All patients underwent surgical intervention with cartilage autograft from non weight bearing areas. Pre- and post-operative outcome were measured using Visual analogue score and Lysholm score with one year follow-up. *Results:* The mean age of patients affected in our study was 32.7 years. In our study males (77.7%) were more commonly affected than females (22.3%). Right knee (55.5%) was more commonly affected. The mean of maximum size of the osteochondral defect by MRI was 2.2 cm. Follow-up was done at 6 weeks, 12 weeks, 6 months and at 1 year. There was statistically significant difference in decrease of VAS score and Lysholm score in all the patients. *Interpretation and conclusion:* In our study, osteochondral autograft transplantation demonstrated both good short and long term outcomes as assessed by the visual analog scale score and Lysholm score. Thus the study concludes that osteochondral autograft transplantation provides good pain relief and can be considered a safe and effective treatment option.

**Keywords:** Osteochondral defect; Mosaicoplasty; Autologous cartilage graft.

### Introduction

Osteochondral defect (OCD) or osteochondritis dissecans is mainly a condition affecting young active individuals, especially adolescent and pediatric population.<sup>1</sup> Exact etiology remains unclear however multifactorial pathogenesis including repeated microtrauma, vascular insufficiency and genetic predisposition is considered responsible for the progression

sequence starting from softening of articular cartilage to patchy separation from underlying bone and eventually complete detachment with loose bodies in the joint. The final fate is degeneration of the underlying bone and early onset osteoarthritis. Prognosis is dependent on many variables like age at onset, location of lesion, size of lesion etc. Skeletal age at the time of onset remains the most important prognostic factor.<sup>2</sup> Clanton classification based on morphology of lesion which can be

correlated with arthroscopy, MRI and radiographic findings is used. Numerous procedures exist to treat OCD; however, it remains a topic of debate which procedure is most ideal. Procedures for treating OCD are classified into two categories: repair techniques and restoration techniques. Repair techniques penetrate the subchondral bone and induce the formation of fibrocartilage tissue. Although excellent short-term clinical outcomes have been demonstrated after marrow stimulation<sup>3</sup>, long-term results of repair techniques have shown an objective and functional decline<sup>4</sup>. Restoration techniques such as osteochondral autograft transplantation, mosaicplasty, and osteochondral allograft attempt to replace the cartilage defect with host or donor articular cartilage in a single stage. Clinical outcomes of osteochondral autograft transplantation have been reported to be good to excellent after seventeen years of follow-up in >90% of patients with defects measuring 1 to 5 cm<sup>3,5</sup>. Severity of arthroscopically assessed OCD lesions have been classified by the International Cartilage Repair Society into 4 types<sup>6</sup>.

#### *Subjects and Methods*

All patients with suspected osteochondral defect of knee presented to the department of orthopaedics were included in this study.

These patients were subjected to MRI with findings confirmed intraoperatively which was followed by surgical repair of the osteochondral defect.

#### *Source*

Data of patients who presented to Department of orthopaedics at the Kle's Dr. Prabhakar Kore hospital and MRC, Belagavi between 1<sup>st</sup> January 2018 to 31<sup>st</sup> December 2018 with osteochondral defect of knee on MRI was collected. Patient information is stored in the computer and patient data entry books. These hospital records are the source of data in this study.

Methods of data collection:

- a. Study design: Prospective case series. Level of evidence IV.
- b. Duration: One year, January 1<sup>st</sup> 2018 to December 31<sup>st</sup> 2018.
- c. Selection criteria:
  - (i) Inclusion criteria:

All patients presenting with signs and symptoms of osteochondral defect of knee as described below

with confirmation on MRI.

1. History of knee injuries and persistent knee pain,
  2. Unexplained knee pain and dysfunction,
  3. Loose body sensation
- (ii) Exclusion criteria:
1. Non consenting subjects.
  2. Previous history of surgery to knee
  3. History of major knee injury
  4. Inflammatory Arthritis
  5. Infective arthritis
  6. Known Osteochondritis Desiccans
  7. Patient before 18 and after 50 years of age

#### *Procedure*

The included patients gave written informed consent for imaging and surgical intervention

A detailed history was noted in the form of a systematic proforma regarding patient name, age, sex, presenting complaints, past medical/surgical history and pain score.

Considering criterias of inclusion and exclusion, the patients were taken up for surgical repair. On arthroscopy, osteochondral fragment was identified. Osteochondral fragment is placed in an appropriate position. Presence of loose bodies if present is identified and removed. The crater if present was debrided to remove fibrous tissue and microfracture was performed to promote blood supply to the base of the OCD fragment. Displaced fragment if present was reduced again and a guide pin was inserted and headless compression screws were inserted from the posterior aspect of the osteochondral lesion. Fixation was performed using screws. After fixation of the detached fragment, the size of the chondral defect decreased. Bone plugs were harvested from the intercondylar notch of the lateral condyle of the same knee using an osteochondral autograft transfer system. Finally, the osteochondral grafts were transferred to the prepared defect site. All plugs were placed at the same level as the healthy cartilage. Seven procedures were performed by arthroscopy and two by open surgery. Progressive ROM was allowed from 1-2 week after surgery. The patient was then allowed to gradually increase ROM as tolerated. The patient was required to use crutches and an unrestricted ROM brace for 5 weeks and then allowed to increase weight bearing as tolerated at 6 weeks after surgery. Eight patients were pain-free with a full ROM and able to walk

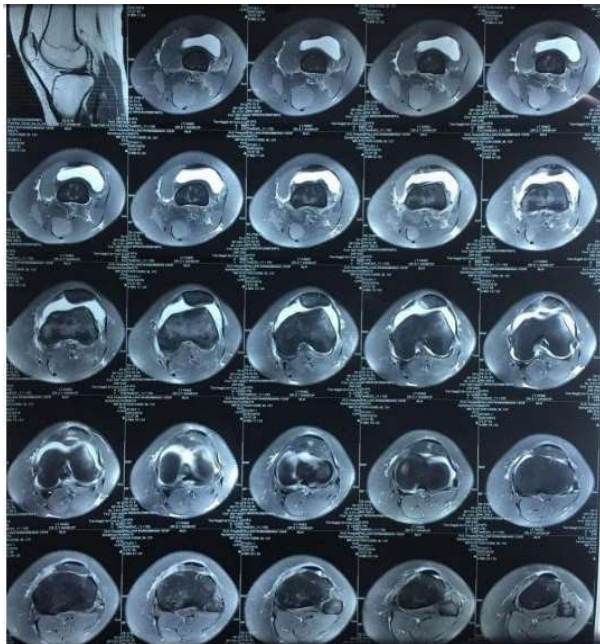
with the treated knee, bearing full weight without any complications between 8 and 12 weeks after surgery. One patient had mild pain which subsided on NSAID's by 8 weeks. At approximately 1 year after surgery, arthroscopic screws were removed and there was significant reduction in the pain scores.

## Results

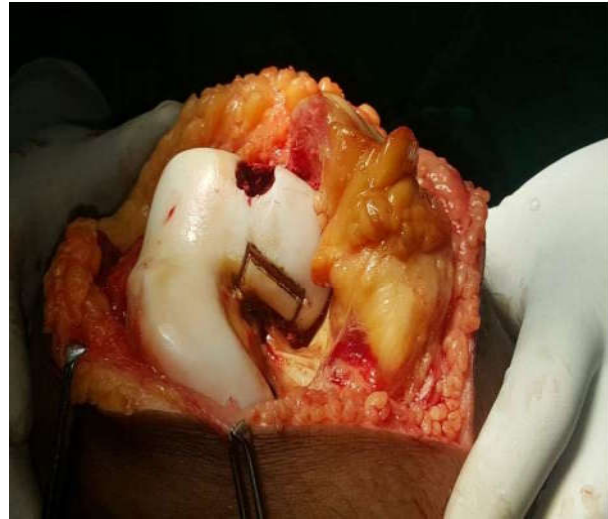
The mean age of patients affected in our study was 32.7 years. In our study males (77.7%) were more commonly affected than females (22.3%). Right knee (55.5%) was more commonly affected. The mean of maximum size of the osteochondral defect by MRI was 2.2 cm.

Follow-up was done at 6 weeks, 12 weeks, 6 months and at 1 year. There was statistically significant difference in decrease of VAS score and Lysholm score in all the patients.

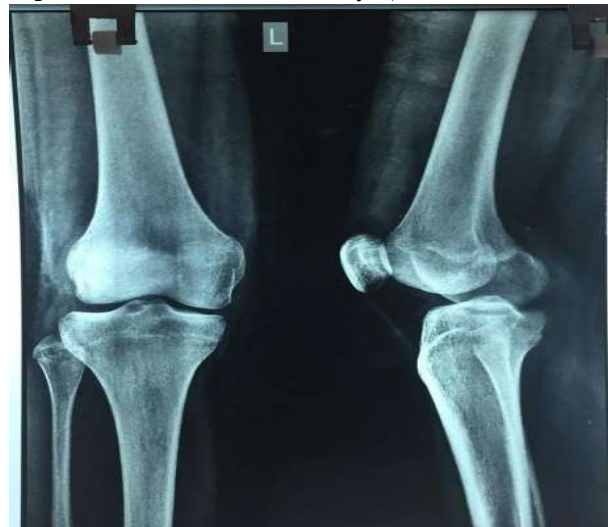The average visual analog scale score with 10 representing the worst pain ever experienced improved from 7.5 preoperatively to 1.1 postoperatively at 1 year follow-up. The Lysholm score increased to 91.4 from the preoperative score of 41.1. The clinical outcome was excellent. The patients had no swelling or locking of the right knee with full ROM at 1 year follow-up.



**Fig. 1:** MRI left knee (axial T2 FS): hyperintensities involving lateral condyle of femur, mild joint effusion and lateral patellar subluxation with partial tear of medial retinaculum.



**Fig. 2:** Intra-operative image: osteochondral defect over lateral femoral condyle and cartilage chip marked at non-weight bearing donor site (medial aspect of lateral femoral condyle).



**Fig. 3:** Plain radiograph of left knee (AP and lateral view): grossly normal.

## Discussion

Osteochondral lesions present mainly in young individuals and have the potential to progress and cause early onset osteoarthritis. Such lesions can be diagnosed with MRI/ arthroscopy and treatment is largely dependent on size and site of lesion and symptoms of the patient. Procedures for treating OCD are classified into two categories: repair techniques and restoration techniques. Although excellent short-term clinical outcomes have been demonstrated after marrow stimulation<sup>3</sup>, long-term results of repair techniques have shown an objective and functional decline<sup>4</sup>. Restoration techniques such as osteochondral autograft transplantation,

mosaicplasty, and osteochondral allograft attempt to replace the cartilage defect with host or donor articular cartilage in a single stage.

Various surgical modalities include for lesions smaller than 2 cm. i) Arthroscopic drilling for symptomatically stable lesion 7 ii). Fixation of unstable fragments with Herbert screws/ Cannulated screws /bioabsorbable pins. For larger lesions the procedures employed are: i) Marrow stimulation techniques like Microfracture, Drilling arthroplasty, Abrasion arthroplasty ii) Autologous chondrocyte implantation. iii) Osteochondral allograft reconstruction. iv) Osteochondral autograft transplantation. Patient tolerated the procedure well and resumed normal levels of activity within 14 weeks.

In our study, we performed osteochondral autograft transplantation from the non-weight bearing surface for managing the osteochondral defect of knee. Clinical outcomes of osteochondral autograft transplantation in our study have been reported to be good to excellent.

### Conclusion

Treatment can be conservative or surgical. Multiple lines of surgical treatments are available which can be chosen as per the surgeon's choice and the presentation. Larger defects are treated with restoration techniques like osteochondral autograft transplantation as in our study. Clinical outcomes of osteochondral autograft transplantation in our study have been reported to be good to excellent.

### References

1. Kramer DE, Pace JL. Acute traumatic and sports related osteochondral injury of the pediatric knee. *Orthop Clin North Am.* 2012;43(2):227-236.
2. Lee B I, Kim B M. Concomitant osteochondral autograft transplantation and fixation of osteochondral Fragment for treatment of a massive osteochondritis dissecans: A Report of 8-Year Follow-up Results. *Knee Surgery and Related Research.* 2015;27(4):263-268.
3. Mithoefer K, McAdams T, Williams RJ, Kreuz PC, Mandelbaum BR. Clinical efficacy of the microfracture technique for articular cartilage repair in the knee: an evidence: based systematic analysis. *Am J Sports Med.* 2009;37:2053-63.
4. Anderson AF, Pagnani MJ. Osteochondritis dissecans of the femoral condyles. Long-term results of excision of the fragment. *Am J Sports Med.* 1997;25:830-4.
5. Hangody L, Dobos J, Balo E, et al. Clinical experiences with autologous osteochondral mosaicplasty in an athletic population: a 17-year prospective multicenter study. *Am J Sports Med.* 2010;38:1125-33.
6. Brittberg M, Winalski CS. Evaluation of cartilage injuries and repair. *J Bone Joint Surg Am.* 2003;85 Suppl 2:58-69.
7. Park Y B, Ha C W, Lee C H et al. Restoration of a large osteochondral defect of the knee using a composite of umbilical cord blood-derived mesenchymal stem cells and hyaluronic acid hydrogel: a case report with a 5-year follow-up. *BMC Musculoskeletal Disorders.* 2017.18:59.