

## Anterior Horse Shoe Fistula: A Case Report

S Dayakar, K Lokesh

**Author's Affiliation:** <sup>1</sup>Post Graduate, <sup>2</sup>Assistant Professor, Department of General Surgery, Narayana Medical College, Nellore, Andhra Pradesh 524003, India.

### How to cite this article:

S Dayakar, K Lokesh. Anterior Horse Shoe Fistula: A Case Report. *New Indian J Surg.* 2020;11(2):252-253.

### Abstract

A 28 years female presented with discharge in the perineal area from 1 month. No history of previous surgeries and comorbidities. On examination of the perianal region, 2 external openings were noted at 11° and 1° clock positions and on per rectal examination internal opening was noted in the 12° clock position 1cm from the anocutaneous junction. MRI fistulogram showed bilateral intersphincteric perianal fistula communicating with each other and a common internal opening at midline anteriorly at 12° clock position. Patient was posted for surgery and fistulotomy was done. Patient was discharged on 2<sup>nd</sup> day and is being followed on outpatient basis. Wound healing was noted at the 2<sup>nd</sup> week. Since anterior horse shoe shaped fistulas are rare we present this case report.

**Keywords:** Horse Shoe Fistula; Goosalls Rule; Fistulotomy.

### Introduction

Horseshoe fistulae, a special type of branching fistula are a well recognized and particularly difficult variety of anal fistulae to treat.<sup>1</sup> Horseshoe fistulas usually have an internal opening in the posterior midline and these posterior tracts can extend in the superficial retroanal space, anteriorly to the anococcygeal ligament or deeper, in the

deep retroanal space, posteriorly to this ligament.<sup>2</sup> These can wrap around the body in a U shape, with external openings on both sides of the anus.

Anterior horseshoe fistulas are much less common and represent a major therapeutic problem due to a significant risk of postoperative incontinence resulting from the lack of protection of the puborectal muscle of the anterior circumference of the anal canal. The tracts of the anterior branching fistulas can run towards the perineal skin, approach or communicate with the vaginal lumen, or reach the scrotal skin in men. Even more extensive tracts can penetrate into the soft tissue of the buttock or groin. In very rare cases, they can even pierce the fascia, e.g. in the posterior femoral surface, and run between muscle bellies.

The challenge in the management of fistulas is to define the course of the track between these openings so that the appropriate surgical option can be used. Until recently, imaging had a limited role in the preoperative assessment of perianal fistulas. Magnetic resonance (MR) imaging has been shown to demonstrate accurately the perianal anatomy. Ultrasound examination of the anal canal (endosonography) and pelvic magnetic resonance imaging are performed to determine the location of the fistula canal, determine the location and the number of secondary tracts, the internal opening and the residual abscess as well as to assess the morphological picture of anal sphincters.<sup>3-7</sup>

### Case Report

A 28 years female presented with discharge in the perineal area from 1 month. No history of previous

**Corresponding Author:** S Dayakar, Post Graduate, Department of General Surgery, Narayana Medical College, Nellore, Andhra Pradesh 524003, India.

**E-mail:** [dayakarc700@gmail.com](mailto:dayakarc700@gmail.com)

**Received on** 27.12.2019, **Accepted on** 28.01.2020

surgeries and comorbidities. On examination of the perianal region, 2 external openings were noted at 11° and 1° clock positions and on per rectal examination internal opening was noted in the 12° clock position 1cm from the anocutaneous junction.

MRI fistulogram showed bilateral intersphincteric perianal fistula communicating with each other and a common internal opening at midline anteriorly at 12° clock position. Patient was posted for surgery and fistulotomy was done. Patient was discharged on 2<sup>nd</sup> day and is being followed on outpatient basis. Wound healing was noted at the 2<sup>nd</sup> week.

Since anterior horse shoe shaped fistulas are rare we present this case report.

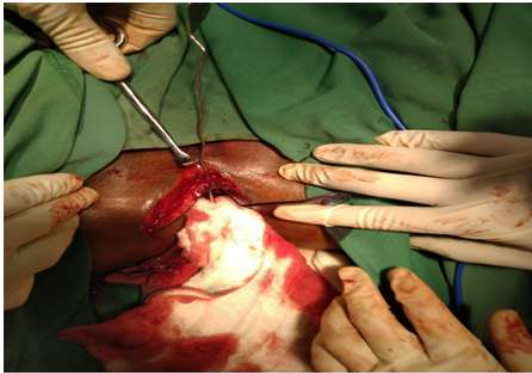


Fig. 1:

#### *Treatment of Horseshoe Fistulas:*

The surgical technique for the treatment of horseshoe fistulas generally involves the introduction of a drainage seton and resection/ transection or draining the fistula tracts.

In anterior fistulas, a seton involving the internal opening with the sphincteric mass involved by fistula can be used and Penrose drain can be passed across through the distal tracts of fistula; this is a modified Hanley<sup>8</sup> procedure proposed by Utynowski.<sup>9</sup>

In posterior fistulas, the side tracts should be first dissected with spared anococcygeal ligament, then the affected crypt should be identified and

the volume of sphincter involved by the fistula should be assessed. If less than 50% of sphincter is involved by fistula, fistulotomy can be theoretically performed. In other cases, seton drainage should be used.

#### **References**

1. Goligher JC. *Fistula in Ano*. In: *Surgery of the anus, rectum, and colon*. London: Bailliere Tindall and Cassell 1975; pp.201-53.
2. Brunicaudi FC, Anderson DK, Billiar TR, et al. 9<sup>th</sup> ed. United States of America: Library in Cataloging; 2010. *Schwartz's Principles of Surgery*; p.1064.
3. Sygut A, Mik M, Trzcinski R, Dziki A: How the location of internal opening of anal fistulas affect the treatment results of primary transsphincteric fistulas? *Langenbecks Arch Surg* 2010;395:1055-59.
4. Poen AC, Felt-Bersma RJF, Eljsoobouts QAJ, et al. Hydrogen-peroxide-enhanced transanal ultrasound in the assessment of fistula-in-ano. *Dis Colon Rectum* 1998;41(9):1147-52.
5. Sudol-Szopińska I, Szczepkowski M, Panorska KA, et al. Comparison of contrast-enhanced with non-contrast endosonography in the diagnostics of anal fistulas. *Eur Radiol* 2004;14(12):2236-41.
6. West RL, Zimmerman DDE, Dwarkasing S et al. Prospective Comparison of Hydrogen Peroxide-Enhanced Tree-Dimensional Endoanal Ultrasonography and Endoanal Magnetic Resonance Imaging of Perianal Fistulas. *Dis Colon Rectum* 2003;46:1407-15.
7. Siddiqui MR, Ashrafian H, Tozer P et al. A Diagnostic Accuracy Meta-Analysis of endoanal Ultrasound and MRI for Perianal Fistula Assessment. *Dis Colon Rectum* 2012 May;55(5):576-85.
8. Hanley PH: Reflections on anorectal abscess fistula: 1984. *Dis Colon Rectum* 1985;28(7):528-33.
9. Utynowski K, Rosen L, Stasik J et al. Horseshoe abscess fistula: Seton treatment. *Dis Colon Rectum* 1990;33(7):602-05.