

Role of Perfusion Scan in the Management of Diabetic Foot Ulcer

Nishad. K¹, Ravi Kumar Chittoria², Barath Kumar Singh³, Jacob Antony Chakiath⁴

How to cite this article:

Nishad. K, Ravi Kumar Chittoria, Barath Kumar Singh, *et al.* / Role of Perfusion Scan in the Management of Diabetic Foot Ulcer / Indian Journal of Diabetes and Endocrinology, 2023;5(1):9-11.

Abstract

Chronic ulcer of foot is a common problem which puts burden on the healthcare facilities all over the world. The cost that the chronic wound imparts on the healthcare system is ridiculously huge. Multiple etiologies play role in making one wound chronic, especially in patients with Diabetes Mellitus. The decreased blood flow to the foot is one of the causes which if detected early may influence the course of the disease. The perfusion deficit in the initial period may not be that evident to be detected in the conventional methods of vascularity assessment in such subset of patients, the Perfusion scan can help in finding the perfusion status of the foot and help making an effective treatment plan. In this article we share our experience of treating such a patient successfully with help of perfusion scan.

Keywords: Diabetes Mellitus; Diabetic foot ulcer; Perfusion Scan.

INTRODUCTION

Foot ulcers due to Diabetes mellitus is quite common. If the complications are not prevented patient might lose his limb or even life. The etiology of ulcer is multifactorial in such patients, one of the causes is decreased blood supply, because diabetes is associated with micro angiopathy and neuropathy. In a clinical scenario it is difficult to know how much the blood supply is compromised in the foot. There are various methods to know how

much blood is reduced, starting from history and clinical examination to the conventional methods. But all the conventional method can diagnose an underlying vascular disease or can diagnose the morphology of the disease, none can detect the perfusion deficit at the point of interest that is the area where the ulcer has developed. Recently we came across an article that perfusion scan can help to know the status of blood supply to diabetic foot much precisely than the other conventional methods. Perfusion scan is a nuclear medicine study. Our study will highlight the role of perfusion scan in the management of diabetic foot ulcer.

MATERIALS AND METHODS

This study was conducted in the Department of Plastic surgery in a tertiary care center during the period December 2019 to February 2020. The patient was a 70 year male, known case of hypertension, diabetes mellitus, and dyslipidemia. He was admitted with a non-healing ulcer at the

Author Affiliation: ^{1,3,4}Senior Resident, ²Professor, Department of Plastic Surgery, Jawaharlal Institute of Postgraduate Medical Education and Research, Pondicherry 605006, India.

Corresponding Author: Ravi Kumar Chittoria, Professor, Department of Plastic Surgery, Jawaharlal Institute of Postgraduate Medical Education and Research, Pondicherry 605006, India.

E-mail: drchittoria@yahoo.com

Received on: 16.12.2022

Accepted on: 25.01.2023

first web space of the left foot, of three months duration. His clinical examination as well as the conventional methods were not showing any features of gross vascular compromise. So, decision of doing a perfusion scan was taken. Informed consent was obtained, and Perfusion scan was done at Department of Nuclear Medicine. Using Tech 99M Pertechnate; 10 millicurie Technicium 99M pertechnate was injected and then with the help of Gamma Camera intra vascular blood flow was assessed for 1 minute and then for 5 minutes tissue perfusion was assessed.

RESULT

The patient remained stable throughout the procedure and after the procedure, results showed abnormal perfusion pattern over the foot. The patient was started on medications to improve blood flow to the limbs, in the form of Botox injections and Aspirin as well in the form growth factors. Wound tissue culture was sent, and appropriate antibiotic therapy was initiated. Regular cleaning and dressings were done. The wound showed features of granulation in two weeks and by the end of 6 weeks the wound showed good healing.




Fig. 1: Perfusion Scan

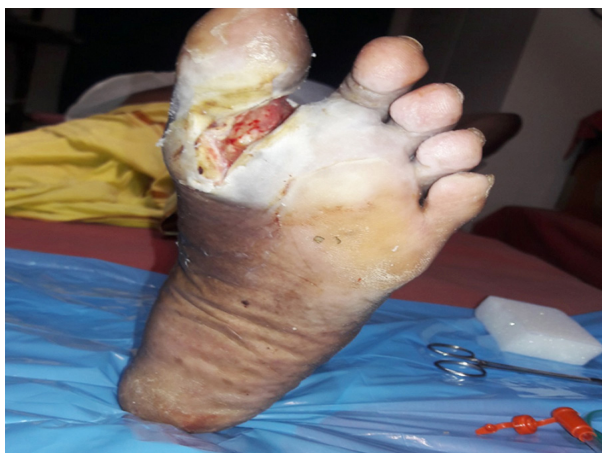

Fig. 2: Ulcer first web space

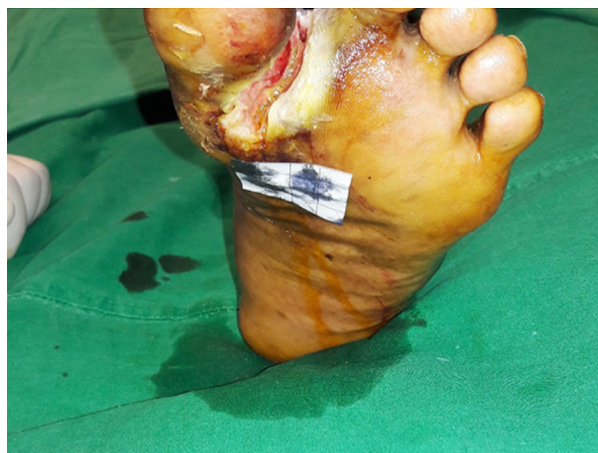

Fig. 3: Ulcer showing Granulation

DISCUSSION

The assessment of perfusion status in diabetic foot ulcer is especially important to understand the likelihood of the wound healing and risk of amputation due to compromised perfusion. All diabetic patients with ulcer should be evaluated for underlying vascular disease.¹⁻³ There are many methods to assess the perfusion status of the limb. The conventional non-invasive bedside tests used in peripheral artery diseases may be unreliable in patients with diabetes.^{4,5} The perfusion study is directed toward three aspects, to detect the severity of the underlying vascular disease, to find out the morphology of distribution of the disease and to assess the regional tissue perfusion status. Apart from these there are molecular imaging techniques the data about which are scanty as the facility to do these nuclear medicine imaging is not that common and the high cost of which is also another limiting factor.

Methods to detect the underlying vascular disease are:

Clinical examination, Ankle brachial pressure index, Toe pressure index, Doppler assessment, pulse volume recording.

Methods to assess the morphology the distribution of the vascular disease are:

Duplex ultrasound, Angiography (Digital subtraction angiography, CT angiogram, Magnetic resonance angiography).

Methods to assess the regional tissue perfusion:

Transcutaneous oxygen tension (TcPO₂), skin perfusion pressure, Laser Doppler, Hyperspectral imaging.

Molecular imaging and newer techniques:

PET, SPECT, Contrast enhanced ultrasound, multimodal MRI.

In this study we have used the nuclear study because the conventional methods to assess the perfusion are not fully reliable, due to neuropathy and vessel calcification.⁵ And moreover, nuclear study uses highly sensitive radiolabeled perfusion molecules^{6,7} which will provide highly specific cellular level perfusion details and will help to make a perfusion map of the foot. These functional data can be combined with high resolution anatomical data obtained on CT and thus produce functional

structural overview of perfusion, in addition to this nuclear study is useful in assessing the status following any intervention, in our study the changes following Botox injection was also assessed. Nuclear imaging has immense potential to increase the understanding of finer perfusion details but the high expense and the lack of centers with facility for nuclear imaging and lack of expertise will hamper these modalities becoming a standard practice for assessment of perfusion.

CONCLUSION

There is role of perfusion scan in making the treatment plan of diabetic foot ulcer. As the decrease blood flow was detected and it could be corrected, and an imminent amputation could be avoided. Limitation of the study is that this study was based on a single subject, the definite results can only be obtained after a large, randomized control trial.

Conflict of Interest: No conflict of interest

Financial support: None

Declaration: All authors have made contribution to the article.

REFERENCES

1. Scottish Intercollegiate Guidelines Network SIGN 116. Management of Diabetes. A National Clinical Guideline. <http://www.sign.ac.uk/pdf/sign116.pdf>; 2010, Accessed 18th May 2015.
2. National Institute for Health, Excellence C. NICE Guidelines [CG119] Diabetic Foot Problems. 2011.
3. Diabetes UK. Putting Feet First. Fast Track for a Foot Attack: Reducing Amputations. 2013.
4. Boyko EJ, Ahroni JH, Davignon D, Stensel V, Prigeon RL, Smith DG. Diagnostic utility of the history and physical examination for peripheral vascular disease among patients with diabetes mellitus. *J Clin Epidemiol* 1997; 50(6):659-668.
5. Suzuki E, Kashiwagi A, Nishio Y, et al. Increased arterial wall stiffness limits flow volume in the lower extremities in type 2 diabetic patients. *Dia Care* 2001; 24(12): 2107-2114.
6. Scremin OU, Fighi SF, Norman K, et al. Pre-amputation evaluation of lower-limb skeletal muscle perfusion with H₂ 15 O positron emission tomography. *Am J Phys Med Rehabil* 2010; 89(6): 473-486.
7. Depairon M, Zicot M. The quantitation of blood flow/metabolism coupling at rest and after exercise in peripheral arterial insufficiency, using PET and 15-0 labeled tracers. *Angiology* 1996; 47(10):2007; 33(1): S1-S75.