

## Drain Site Hernia in an Adult Female: A Rare Case Report and Review of Literature

Raj Ranjan Kumar<sup>1</sup>, Prachi Ranjan<sup>2</sup>

**Author's Affiliation:** <sup>1</sup>Joint Director, <sup>2</sup>Medical Officer, Department of Surgery, Durgapur Steel Plant Hospital, Durgapur, West Bengal 713205, India.

### How to cite this article:

Raj Ranjan Kumar, Prachi Ranjan, Drain Site Hernia in a Adult Female: A Rare Case Report and Review of Literature. *New Indian J Surg.* 2020;11(3):425-427.

### Abstract

A report of rare case of Drain Site Hernia through the defect created by previous scar of surgical drain tube placed twenty years back. Surgical drains are useful but have been noted not to be without complications. Small bowel herniation through a previous drain site is a rare complication of abdominal drain insertion. We report a case of drain site hernia which was diagnosed with the help of CECT abdomen due to previous drain site incision.

**Keywords:** Abdominal; Drains; Hernia complications; Small bowel; Predisposing factors; Prevention.

### Introduction

The aim of this case report is to highlight the existence of this rare condition. Drains have been used in surgical practices since the time of Hippocrates in 460-377 BC.<sup>1</sup> Drains are classified as closed or open drains. Drains are being used therapeutically or prophylactically to drain or prevent collection of fluid at surgical site and help in healing. However the drains are not without complications, which include ascending infection, herniation of abdominal contents through drain site, migration of drain and perforation of viscera. Drain site hernia is a rare but known complications of abdominal drains. Drain site hernia is thought

as an incisional hernia which may lead to complications like obstruction and strangulations<sup>5</sup> requiring emergency surgical interventions. So the knowledge of such conditions and predisposing factors<sup>3</sup> are important for early identification and prevention DSH<sup>3</sup> and other complications of drains.

### Case history

57 year hindu female, presented to us with complaints of intermittent pain and swelling over right side of abdomen for one year. The swelling is non progressive, associated with on and off discomfort; No history of fever, vomiting, abdominal distension, or obstipation. She had undergone open cholecystectomy 20 years back.

Clinical examination revealed healthy adult female with BMI of 30. Abdominal examination revealed midline scar mark of previous laparotomy which had healed by primary intention. There was a soft ill defined, parietal swelling at the right upper abdominal region about 12 cm above the umbilicus (Fig. 1). The swelling was non tender with restricted mobility, no impulse on cough or straining. There was a one centimeter scar mark over the summit of the swelling which was probably of the previous drain site scar.

The diagnosis (Fig. 2) could be established by CECT abdomen. There was a large hernia in the right side of the abdomen with omental fat and loops of the small intestine. This hernia had a narrow neck. Under general anaesthesia the hernia sac was identified under the external oblique fibres

---

**Corresponding Author: Raj Ranjan Kumar**, Joint Director, Department of Surgery, Durgapur Steel Plant Hospital, Durgapur, West Bengal 713205, India.

**E-mail:** [dr.rajaranjan@yahoo.com](mailto:dr.rajaranjan@yahoo.com).

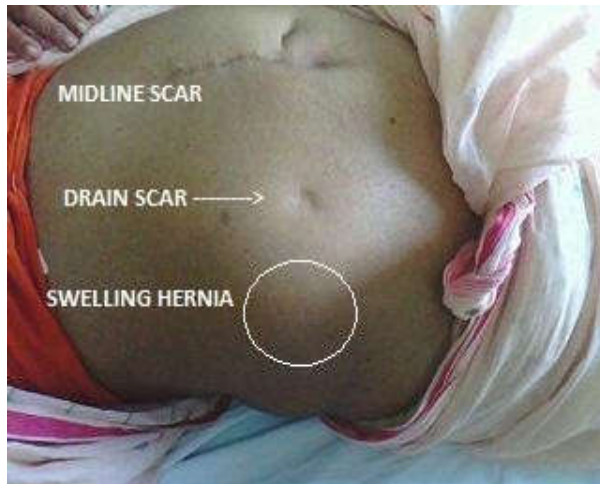

Fig. 1: Preoperative picture showing the midline laparotomy scar. Also the drain site scar and the adjacent swelling may be appreciated.

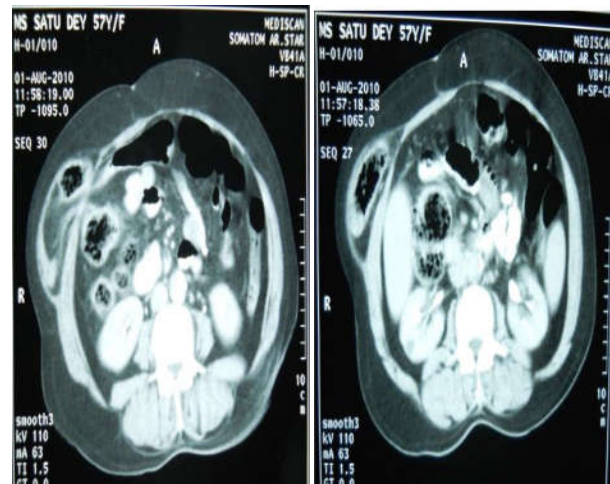


Fig. 2: CT scan shows the defect in the anterior abdominal wall, with herniating ileal loops and omentum.

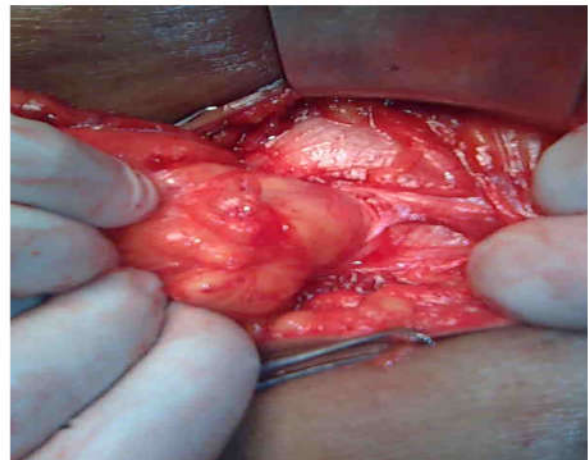
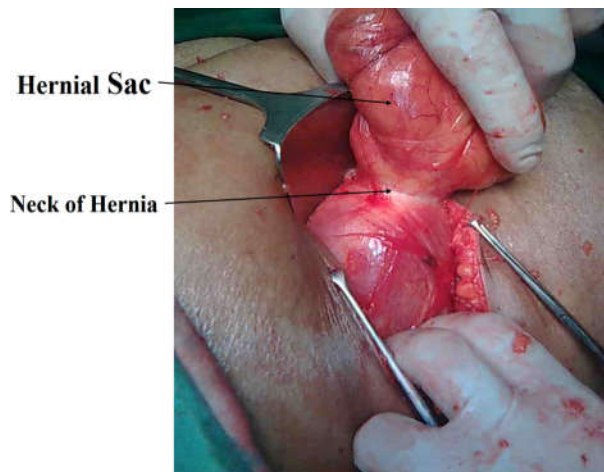


Fig. 3 and 4: Intra operative images showing Narrow neck and sac of Hernia.

had a narrow neck and contents were omentum and ileal loops.<sup>6</sup> The defect was in the abdominal wall between the fibres of internal oblique and transversus abdominis. The contents of the sac was reduced and the abdominal wall defect repaired with non-absorbable sutures.

The post operative period was uneventful. On 8<sup>th</sup> post operative day, the sutures were removed. The healing was by primary union. The predisposing factors here were probably the previous drain site incision and obesity. CT scan helps in making the diagnosis since the presence of oral contrast clearly shows in the contents of the hernia sac.

## Discussion

Drain site hernia is very rare long term complication of drain inserted into abdominal cavity to prevent or remove any collection in surgical site. The

incidence rate of DSH<sup>4</sup> quoted in literature is 0.1–3.4%. Drain site hernia is more common after post open surgery as compared to post laparoscopic surgery. The contents of DSH are usually omentum and small bowel. Other contents in DSH are appendix,<sup>8</sup> colon, gall bladder,<sup>7</sup> fallopian tubes<sup>2</sup> etc. have also been reported. In our case it is only small bowel and omentum present<sup>6</sup> in hernia sac. The morbidity and mortality associated with DSH are due to strangulation of contents. The large size drain (>10 mm), surgical site infection, obesity, increased intra-abdominal pressure, steroid<sup>6</sup> administration, diabetes have been reported as the predisposing factors. The incidence of port site hernia following laparoscopic surgery is reported to be 0.65–2.5%. Probably the same predisposing factors which cause port site hernia govern herniation from drain site following open surgery.

Various measures have been adopted to prevent DSH are based on previous reports. They are use

of drain size less than 10mm external diameter, oblique or transverse insertion of drain through abdominal wall, obliteration of tract with non-absorbable suture<sup>9</sup> after removable or shortening of drain progressively before it is removed. In laparoscopic surgery drain should be inserted through the port size <5 mm. If the drain is inserted through large size port, single narrowing facial stitch or purse string suture is recommended. It is said that DSH occurs 3–8 hrs, after removal of drain. Evangelos<sup>5</sup> Falidas et. al. described a case of DSH<sup>3</sup> occurred 15 hours after a laparotomy. Preetha Rani described a case of DSH commonly occurring several months to several years following laparotomy and mostly associated with incisional hernia of many laparotomy wound scar. In our case the diagnosis of drain site hernia was made 20 years after the initial laparotomy.

### Conclusion

Insertion of drain is a common procedure after many types of surgery. Its purpose is to minimise the postsurgical complications and morbidity of patients. Drains have their own complications increasing the morbidity of patients. Therefore, it is very important to know the presence of such complications and their predisposing factors, so that surgeons can take measures to prevent such dangerous complications. If drain is absolutely required, it should be inserted and removed by strictly adhering principles of insertion and removal of drain. Therefore unwanted surgical drains should be avoided.

### Reference

1. Memon MA. MemonMI , Donohue JH. Abdominal drains; a Brief Historical Review Med J 2001;94:164–166.
2. G. Radhika, GtaRadhakrishnan. Fallopian Tube Herniation: An Unusual Complication of Surgical Drain. Lipi Sharma, Alpana Singh, StruthiBhaskaran. Case Report in Obstetrics and Gynaecology Volume 2012, Article ID 194350.
3. Preetha Rani Kumar Prasad. Drain Site Hernia: A Rare but Recognised Complications of Surgical Drainage. A Study of their Risk factors, management and prevention. University Journal of Surgery and Surgical Specialities Volume 3 Issue2, 2017.
4. Makama JG, AmehEA ,Garba ES. Drain Site Hernia: A review of Incidence and Prevalence. West Afr J Med. 2015, Jan-Mar: 34(1): 62–8.
5. Evangels Falidas, Mthioulaskis,Konstantinos Vlachos et. al. Strangulated Intestinal Hernia Through a Drain Site. Int. J Surg Case Report, 2012; 3(): 1–2 PMID: PMC326749.
6. Lee R Raftery AT. Evisceration of small bowel at the site of an intra-abdominal drain. A complication of steroid therapy? Br J Clin Pract.1982 Jul-Aug ; 36(7–8): 282–3.
7. Vedat B, Aziz S , Cetin K. Evisceration of gall bladder at the site of a pezzet drain: a case report. Cases J . 2009 Jul 31;2: 8601. Doi:https://doi.org/10.4076/1757-1626-2-8601.
8. O ' Riordan DC , Horgan LF , Davidson BR . Drain-Site herniation of the Appendix. Br. J Surg. 1995 Dec; 82((12): 1628.
9. Nadler RB , Mc Dougal E, Bullock AD , Ludwig MA , Brunt LM. Fascial closure of laparoscopic port sites: a new technique . Urology. 1995 Jun; 45(6): 1046–8.