

Prevalence of Common Upper GI Diseases on Esophagogastroduodenoscopy

Prasad K¹, Pavan Kumar S², Suresh BP³

Author's Affiliation: ^{1,2}Assistant Professor, ³Professor and HOD, Department of General Surgery, Subbaiah Institute of Medical Sciences, Shivamogga, Karnataka 577222, India.

How to cite this article:

Prasad K, Pavan Kumar S, Suresh BP/Prevalence of Common Upper GI Diseases on Esophagogastroduodenoscopy/ New Indian J Surg. 2022;13(1):31–35.

Abstract

Objective: To document and correlate different indications and findings of EGD scopy in our endoscopy unit.

Methods: A retrospective descriptive study of 519 patients who underwent Esophagogastro duodenoscopy (EGD scopy) was conducted in the Endoscopy Unit of Department of General surgery of Tertiary Care Centre. Included patients underwent EGD scopy. Demographic data including indications and endoscopic findings of the patients were collected via study proforma.

Results: Total five hundred and nineteen patients were studied; Out of all 64.54% were males and 35.06% were females. Epigastric pain or pain abdomen was the commonest indication (41.23%) followed by dysphagia (13.48%), Hematemesis (10%), vomiting and regurgitation, screening (9.05% and 7.51% respectively). The most common endoscopic findings were gastritis (35.45%), GERD (9.82%), Varices (9.02%), Carcinoma (7.32%), GI Ulcer (5.78%), hiatal hernia (5.58%), stricture (3.08%) and normal (20.03%).

Conclusion: The most common indication was Epigastric pain or pain abdomen for EGD scopy and indications were relevant to findings.

Keywords: Esophagogastroduodenoscopy; Endoscopy; Upper GI diseases; Acidity.

Introduction

Upper gastrointestinal (UGI) complaints among other abdominal issues are associated with considerable morbidity and mortality ranging from 2% to 33%.^{1,2} EGD scopy has a better diagnostic yield than radiology and also has therapeutic potential for gastrointestinal disorders.³ Among UGI complaints, bleeding is a fatal medical emergency with a multitude of causes globally, including esophageal varices, gastric erosions, peptic ulcer, and mucosal tear.⁴

Endoscopic services are yet not readily accessible in most of the healthcare facilities in and around the Institute as we have huge dependent rural population. As the number of patients undergoing the procedure is increasing. We therefore aim to perform a study to document indications and endoscopic findings in patients undergoing EGD scopy at a Subbaiah Institute of Medical Sciences, Shivamogga, which has a large number of referrals from around the region.

Corresponding Author: Pavan Kumar S, Assistant Professor, Department of General Surgery, Subbaiah Institute of Medical Sciences, Shivamogga, Karnataka 577222, India.

E-mail: skumarpavan71@gmail.com

Received on: 06.01.21

Accepted on: 13.01.22

Materials and Methods

This was a study conducted at the Department of General surgery of Tertiary Care Centre. 519 patients were recruited over a period of 24 months who were referred from inpatient, outpatient, and emergency department.

Demographic characteristics including age, gender, indications, endoscopic findings, and the type of therapeutic intervention in patients were gathered on the structured proforma. The endoscopy was performed using endoscope. Lignocaine (4%) gargles were used for local analgesia before the procedure.

Patients were kept fasting over-night or 6 hours nil per oral. Pharyngeal spray with 10% xylocaine is sprayed topical before the procedure. Endoscopy was carried out by flexible fiberoptic esophagogastroduodenoscopy (Olympus) by placing patient in left lateral position.

A mouth guard was used to protect the instrument. Lubricated instrument was passed over the back of the tongue and under direct vision into the esophagus. Subsequently the endoscope was advanced with clear view of lumen.

During the whole procedure, examination of esophagus, stomach and duodenum was done to look for abnormal areas in the form of swelling, ulcer, growth, fibrosis, bile reflux, varices and gastroesophageal reflux and were evaluated properly and biopsy was taken from suspicious areas and wherever required. Before withdrawal of endoscope from stomach, air and gastric contents were aspirated. The whole procedure is recorded by photography and videography for documentation and further follow-up.

Inclusion criteria

Patients above the age of 16 years with stable general conditions presenting with dyspepsia, dysphagia, odynophagia, nausea and vomiting, pyrosis, occult GI bleeding, cirrhosis (both outpatients and patients referred from other hospitals) as shown in table 1, pie chart 1.

Exclusion criteria

- Patients <16 years.
- Massive upper gastrointestinal bleeding.
- Corrosive poisoning.
- Unconscious and unstable patient.

Results

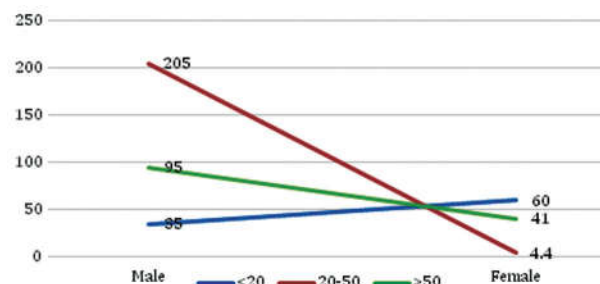
There were 335 (64.54%) males out of the total 519 patients. 311 (59.92%) patients were referred from the outpatient department while the rest were from different inpatient departments. Pain abdomen and Epigastric pain was the commonest indication (n=214; 41.23%) followed by dysphagia representing 70 (13.48%) patients. Other common endoscopic indications have been shown in Table 1.

Table 1: Distribution of Indications with gender.

	Male(n)	Female(n)	Total
Pain abdomen/ Epigastric pain	134	80	214;(41.23%)
Dysphagia	60	10	70;(13.48%)
Hematemesis	46	17	63;(12.13%)
Vomiting	26	21	47;(9.05%)
Regurgitation	27	12	39;(7.51%)

The most common findings were gastritis (35.45%) GERD (9.82%), esophageal varices (9.02%), followed by other findings and normal study (20.03%) as shown in table 2, pie chart 2.

Graph 1: Graph wise distribution of Age and gender.



Graph 2: Graph wise distribution of Indications of Surgery.

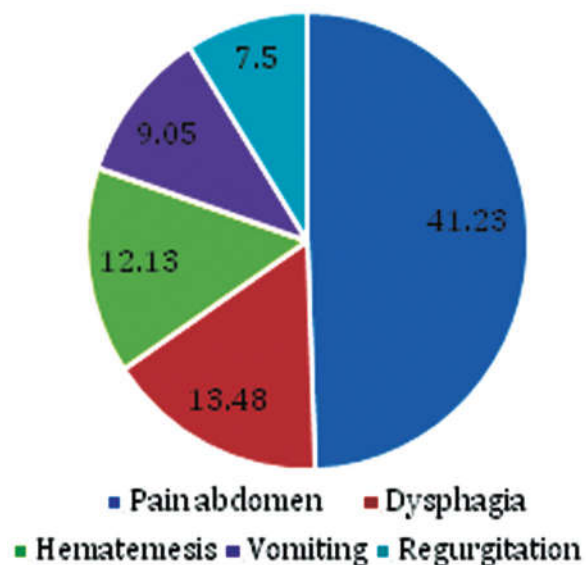


Table 2: Endoscopic findings with Gender wise distribution.

	Male(n)	Female(n)	Total
Gastritis	117	67	184;(35.45%)
Normal	58	46	104;(20.03%)
GERD	35	16	51;(9.82%)
Varices	34	13	47;(9.05%)
Carcinoma	23	15	38;(7.32%)
GI ulcer	25	5	30;(5.78%)
Hiatus hernia	20	9	29;(5.58%)
Stricture	14	2	16;(3.08%)

Graph 2: Graph wise distribution Endoscopic Findings.

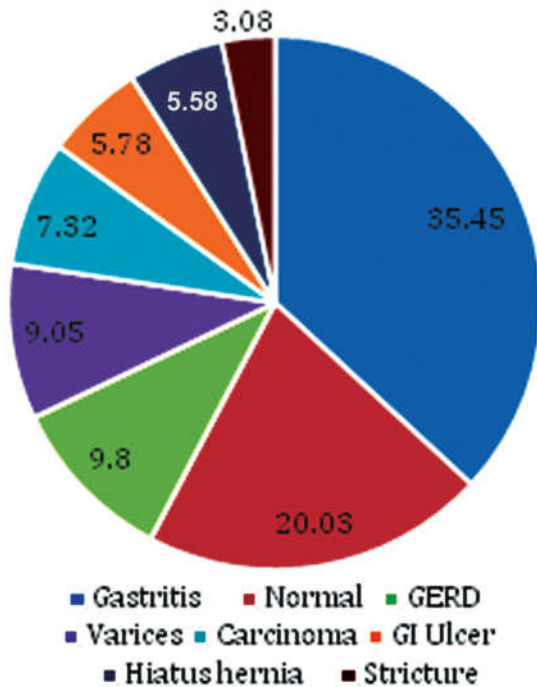


Table 2: Distribution of study subjects based of Combination of pathologies.

	Male(n)	Female(n)	Total(n)
GERD+Hiatus hernia	15	9	24
GI Ulcer+haemorrhage	9	6	15
GI Ulcer +stricture	4	2	6

Discussion

Upper GI endoscopy is a quick and cost-effective diagnostic tool for a wide variety of upper gastrointestinal disorders. In addition to its diagnostic potential, it also has the established therapeutic role for various disorders.

The clinical indications for EGD scopy is, patients presenting with upper GI symptoms which includes upper abdomen pain, heart burn that's

refractory to treatment, dysphagia, hematemesis, weight loss, anemia, foreign body ingestion. There is no absolute contraindication for upper gastrointestinal endoscopy in our study. Major complications such as perforation or aspiration are rare, occurring in less than 1 per 1000 cases⁵ nil in our study. In this study, GI symptoms were found more common in males (60%) compared to females (40%).

This might be due to alcoholism; smoking and lifestyle factors are more common in males compared to females. The present study found that majority of patients with upper gastrointestinal symptoms were diagnosed to have gastritis which was found alone or found to be co-existing with other pathologies like esophagitis, GERD, hiatus hernia followed by reflux esophagitis, carcinoma esophagus and stomach, gastric ulcer and duodenal ulcer.

Other findings were gastric outlet obstruction and foreign body. Gastritis is a condition in which the mucosa lining the stomach is inflamed, or swollen that can be acute or chronic. Common cause for gastritis is Helicobacter pylori infection, damage to the stomach lining, which leads to reactive gastritis.

Peptic ulcer disease is erosions in gastric or duodenal mucosa that extends through muscularis mucosa. Common causes are infection with H. pylori and use of non-steroidal anti-inflammatory drugs. If untreated it may lead to complications like bleeding, perforation, gastric outlet obstruction, giant gastric ulcers, refractory ulcers and malignant transformation may also occur. UGI endoscopy is more sensitive and specific for peptic ulcer disease and allows biopsy of gastric lesions.⁶

Perforation in peptic ulcer disease occurs in approximately 2 to 10 percent of peptic ulcers. It most commonly involves the anterior wall of the duodenum 60%, however it may also occur in antral 20% and lesser-curvature 20%. Hollow viscus perforation and resulting chemical and bacterial peritonitis is a surgical emergency that can cause sudden and rapid deterioration of general condition and requires immediate surgical intervention laparotomy and placement of an omental patch (Graham patch plication). In otherwise healthy patients with a history of chronic ulcer and minimal peritoneal contamination, definitive anti-ulcer procedure (vagotomy and drainage, highly selective vagotomy) may also be considered. Perforated gastric ulcers are treated with an omental patch, wedge resection of the ulcer, or a partial gastrectomy and re-anastomosis.⁶

5-8% of patients of peptic ulcer disease presents with gastric outlet obstruction. UGI endoscopy is recommended to determine the site, cause, and degree of obstruction.⁶ Biopsy was taken from the site to evaluate for the cause and found to be benign in nature. Patients were managed conservatively with nil per oral, nasogastric tube insertion for decompression and regular saline wash to reduce the oedema.

On subsequent endoscopic studies, edema reduced and the obstruction was relieved. Gastro esophageal reflux disease (GERD) is the most common benign disorder of stomach and esophagus, which occurs when there is retrograde flow of gastric contents through lower esophageal sphincter (LES), which results from the failure of endogenous anti-reflux mechanisms. GERD most commonly manifest as heart burns, which can gradually worsen causing complications like strictures, ulcers, metaplasia, dysplasia, carcinoma and pulmonary disease.⁷

Patients with GERD were sent for manometry studies and followed up with gastro-enterologist advice. Gastric cancer is the 14th most common cancer and second leading cause of death from malignant disease worldwide, with especially high mortality rates. 90% of stomach tumors are adenocarcinomas, which are subdivided into two main histologic types as well-differentiated or intestinal type and undifferentiated or diffuse type.

Multiple factors play role in etiology of gastric cancer, more than 80% of cases have been associated with H. pylori infection. Other risk factors includes diet, genetic, socioeconomic, polyps and proton pump inhibitors also attributes to gastric carcinogenesis.⁸ Carcinoma esophagus is the sixth leading cause of cancer-related mortality and the eighth most common cancer worldwide. Squamous-cell carcinoma is the predominant form of esophageal carcinoma worldwide and others forms are adenocarcinoma, mesenchymal tumor, neuroendocrine tumour and benign tumours. Tobacco and alcohol are strong risk factors and others include achalasia, socioeconomic, GERD, Barrett's esophagus.⁹ Patient with malignant changes found during endoscopy, adequate tissues (6 to 8) were taken from suspicious site and send for biopsy.

Herniation of the contents of the abdominal cavity most commonly the stomach is referred as hiatus hernia, through the esophageal hiatus of the diaphragm into the mediastinum. GERD is the main clinical manifestation of hiatus hernia.

Other symptoms associated with hiatus hernia are reflux esophagitis, Barrett's esophagus and esophageal adenocarcinoma.

Hiatus hernias of three types which are type 1 (sliding) hiatus hernia, which is the commonest and accounts for about 90%, type 2 (para-esophageal or rolling) hiatus hernia and type 3 are mixed types I and II i.e., with a sliding element to the type II hernia.¹⁰

Endoscopy plays a significant role in the diagnosis of hiatus hernia. Varices are dilated sub-mucosal veins, that commonly occurs as consequences of portal hypertension. Mortality after an index hemorrhage in patients with varices is as high as 50% and with subsequent bleeding it's 30% mortality rate. Endoscopy plays an essential role in the management of varices as it identifies patients in initial stage and helps to prevent variceal hemorrhage and helps to initiate specific therapies such as banding and sclerotherapy.¹¹ Foreign body ingestion is one of the rare indication seen in our practice such as accidental swallowing fish bone. In some studies 10-20% of ingested foreign bodies require treatment.

Incidence of complications caused by foreign bodies in the upper gastrointestinal tract is 15-42%, that varies with time, higher the complications, longer the foreign bodies had been impacted. Complications were observed in 60% of foreign bodies that had been impacted for 48-72h and 10.5% of those impacted for up to 24h. These complications may vary from mild such as erosions superficial lacerations, oedema, hematoma, and mild respiratory complications to severe forms such as perforation (most frequent), and hemorrhage resulting from injury to large vessels that could be fatal.^{12,13} UGI endoscopy is a safe and effective tool that helps in early removal of foreign bodies from the upper gastrointestinal tract.

The high incidence of Gastritis could be due to more Alcohol consumption, UGI bleeding due to esophageal varices could be attributed to the end-stage liver diseases due to cirrhosis and also possibly due to alcoholism.^{14,15} Whereas a comparatively lower incidence of peptic disease as a cause of UGI bleeding could be attributed to the common prescription of PPI and other acid-suppressive therapy by primary care physicians.

Conclusion

Upper GI endoscopy is one of the most essential tools to evaluate gastrointestinal disorders with both diagnostic and therapeutic potential. In this

study we found out that indications and findings were almost matching and appropriate because prior to procedure patients were subjected thorough questioning and physical examination by attending consultants and post graduate students as we found on records. When compared to previous studies, upper abdomen pain abdomen and heart burn as the most common indication for the procedure and Gastritis and GERD were found to be the leading underlying pathology in the present study.

References

1. Stanley AJ, Laine L. Management of acute upper gastrointestinal bleeding. *Bmj* [Internet]. 2019;364.
2. Moledina SM, Komba E. Risk factors formortality among patients admitted with upper gastrointestinal bleeding at a tertiary hospital: A prospective cohort study. *BMC Gastroenterology* [Internet]. 2017; 17(1):165.
3. Agyei-Nkansah A, Amoako Duah MA. Indications and findings of upper gastrointestinal endoscopy in patients presenting to a District Hospital, Ghana. *The Pan African Medical Journal* [Internet]. 2019;34.
4. Ahmad I, Ma A. Upper Gi Endoscopy A review of 500 cases at Sheikh Zayed Medical College / Hospital Rahim Yar Khan. *Dysphagia* [Internet]. 2010; 46:9-13.
5. Shah JV, Shah S. Upper gastrointestinal endoscopy in early diagnosis of gastric disorders. *Int J Contemp Med Res*. 2016;3(7):1943-5.
6. Ramakrishnan K, Salinas RC. Peptic ulcer disease. *Am Fam Phys*. 2007;76(7).
7. Yates RB, Oelschlager BK, Pellegrini CA. Gastroesophageal reflux disease and hiatal hernia. *Sabiston Textbook of Surgery*. 20th ed. Philadelphia, PA: Elsevier; 2017: 1043-1064.
8. Crew KD, Neugut AI. Epidemiology of gastric cancer. *World J Gastroenterol*. 2006;12(3):354.
9. Pennathur A, Gibson MK, Jobe BA, Luketich JD. Oesophageal carcinoma. *Lancet*. 2013;381(9864):400-12.
10. Gordon C, Kang JY, Neild PJ, Maxwell JD. The role of the hiatus hernia in gastro-oesophageal reflux disease. *Alimentary Pharmacol Therapeutic*. 2004;20(7):719-32.
11. Hwang JH, Shergill AK, Acosta RD, Chandrasekhara V, Chathadi KV, Decker GA, et al. The role of endoscopy in the management of variceal hemorrhage. *Gastrointestinal Endoscopy*. 2014;80(2):221-7.
12. Chaves DM, Ishioka S, Felix VN, Sakai P, Gama-Rodrigues JJ. Removal of a foreign body from the upper gastrointestinal tract with a flexible endoscope: a prospective study. *Endoscopy*. 2004;36(10):887-92.
13. Keren D, Rainis T, Stermer E, Lavy A. A nine-year audit of open-access upper gastrointestinal endoscopic procedures: Results and experience of a single centre. *Canadian Journal of Gastroenterology* [Internet]. 2011;25.
14. Patel HS, Vaishnav U. Analysis of upper gastro intestinal scopy finding in public hospital associated with medical college. *International Surgery Journal* [Internet]. 2016;3(4):1964-6.
15. Rabbani A. Experience with endoscopy at Bin Jalawi Hospital KSA. *Journal of Ayub Medical College Abbottabad* [Internet]. 2005;17(1).
16. Jalpa Devi, Muhammad AkramBajwa. Upper Gi Endoscopy-indications and Findings at Tertiary Care Hospital Hyderabad/Jamshoro. *Journal of Pharmaceutical Research International* 33(14): 46-50, 2021.
17. Puttaraju S, Sreramaseshadri SRM. Study of upper gastrointestinal endoscopy in patients with gastrointestinal symptoms. *Int Surg J* 2019;6:3595-9.