

## Morphometric Study of Ventral Branches of Abdominal Aorta

Prajakta A Thete<sup>1</sup>, Mehra Bhoir<sup>2</sup>, MV Ambiyee<sup>3</sup>

### How to cite this article:

Prajakta A Thete, Mehra Bhoir, MV Ambiyee. Morphometric Study of Ventral Branches of Abdominal Aorta. Indian J Anat. 2020;9(2):112-117.

**Author's Affiliation:** <sup>1</sup>Assistant Professor, Department of Anatomy, Grant Govt. Medical College and JJ Hospital, Mumbai, Maharashtra 400008, India. <sup>2</sup>Professor and Head, Department of Anatomy, HBT Medical College And Dr. R N Cooper Municipal General Hospital, Juhu, Mumbai, Maharashtra 400056, India. <sup>3</sup>Professor, Department of Anatomy, SIA College of Physiotherapy, Dombivli East, Mumbai, Maharashtra 421201, India.

**Corresponding Author:** Prajakta A Thete, Assistant Professor, Department of Anatomy, Grant Govt. Medical College and JJ Hospital, Mumbai, Maharashtra 400008, India.

**E-mail:** drprajktathete@gmail.com

**Received** 03.04.2020 | **Accepted** 17.06.2020

### Abstract

*Introduction:* Abdominal aorta and its major branches supply oxygenated blood to all the organs in abdominal cavity and lower limbs. Ventral branches of abdominal aorta supply the gastrointestinal tract. Anatomical knowledge of the abdominal aorta and its branches is important not only to determine flow dynamics but also crucial in understanding pathogenesis of vascular diseases.

*Aim:* To measure the External diameters of ventral branches of abdominal aorta (coeliac trunk, superior mesenteric artery and inferior mesenteric artery) at its origin

*Material and Method:* The study was carried out on 60 adult cadavers over a period of 2 years. Measurement of external diameters of ventral branches of abdominal aorta was taken with the help of digital vernier calliper.

*Result:* The mean external diameter of coeliac trunk, SMA, IMA at its origin is  $0.64 \pm 0.08$  cm,  $0.77 \pm 0.07$  cm,  $0.37 \pm 0.06$  cm respectively.

*Conclusion:* The knowledge of normal arterial diameters in a specific population is of great importance in order to make correct and precise radiological diagnosis of arterial aneurysms.

**Keywords:** Abdominal aorta; Coeliac Artery; Superior Mesenteric Artery; Inferior Mesenteric Artery

### Introduction

Aorta enters the abdomen via the aortic hiatus in the diaphragm at the level of the 12<sup>th</sup> thoracic vertebra and ends at 4<sup>th</sup> lumbar vertebra in the transcrystal plane. Abdominal aorta and its major branches supply oxygenated blood to all the organs in abdominal cavity and lower limbs. Ventral branches of abdominal aorta supply the gastrointestinal tract.<sup>1</sup> Anatomical knowledge of the abdominal aorta and its branches is important not only to determine flow dynamics but also crucial in understanding pathogenesis of vascular diseases.<sup>2</sup>

Despite that the celiac trunk anatomical variations are well explored in the literature, information on the arterial diameter of its main branches is still scanty. Arterial diameter of celiac trunk hepatic branches has gained importance especially due to development of techniques for liver transplantation.<sup>2,3</sup>

It is reasonable to assume that the life expectancy for the general population will continue to increase, generating a greater number of problems of vascular disease. New materials suitable for prostheses may help to meet the challenge. In addition to this, it is necessary for the surgeon to continue investigations in the pathogenesis of obstructive and aneurysmal aortic lesions and to review the anatomy of the vascular tree with a new perspective.<sup>4</sup>

The material reported in this paper will be helpful not only to the vascular surgeon, but also to those who study the fluid dynamics involved and to others engaged in designing the vascular prostheses of tomorrow.

### Materials and Methods

The Dissection of the abdominal aorta was carried out in 60 cadavers which were embalmed using 10% formalin. Each cadaver was kept in supine position, it was numbered.

Cadavers were procured from the department of Anatomy of Medical Colleges with prior

permission. Ethics committee approval for the study was taken.

The skin was reflected from medial to lateral aspect in four quadrants towards the midaxillary line. Anterior abdominal wall was dissected layer by layer. Muscles of anterior abdominal wall were incised and reflected laterally. Peritoneal cavity was opened & branches of coeliac trunk were identified. Then as dissection proceeded, different organs of abdomen were removed & simultaneously different branches of abdominal aorta were identified. Satisfactory exposure of abdominal aorta and its branches was done. The following observations were made and noted.



Fig 1: External diameters of coeliac trunk.



Fig 2: External diameters of superior mesenteric artery.



Fig. 3: External diameters of inferior mesenteric artery.

External diameters of ventral branches, coeliac trunk (Fig. 1), superior mesenteric artery (Fig. 2) and inferior mesenteric artery (Fig. 3) of abdominal aorta were measured with the help of digital vernier calliper

### Inclusion Criteria

Cadavers of either sex with age group between 25 to 75 years

### Exclusion Criteria

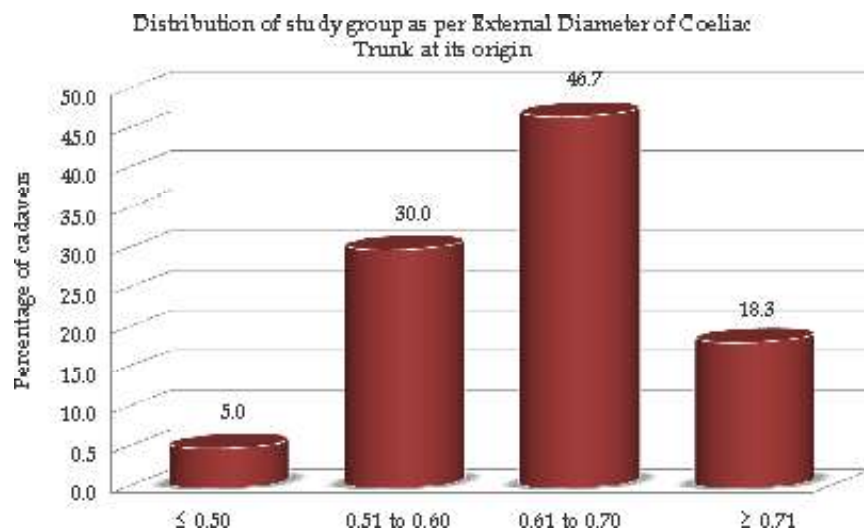
Cadavers of any other age than mentioned above were excluded. Cadavers showing anomalous tortuosities, dilatation and aneurysms of abdominal aorta were excluded.

### Results

The Abdominal Aorta was exposed from its aortic opening in diaphragm to its bifurcation into common iliac arteries in all cadavers. All the branches of abdominal aorta were identified and dissected meticulously. And all the features were noted and measurements were taken.

**Table 1:** External diameter of Coeliac Trunk at its origin (in cm)

Distribution by groups		
Diameter in cm	No. of Cadavers	Percent (%)
≤0.50	3	5.0
0.51 to 0.60	18	30.0
0.61 to 0.70	28	46.7
≥0.71	11	18.3
<b>Total (N)</b>	<b>60</b>	<b>100.0</b>



**Graph 1:** The distribution of study group as follows.

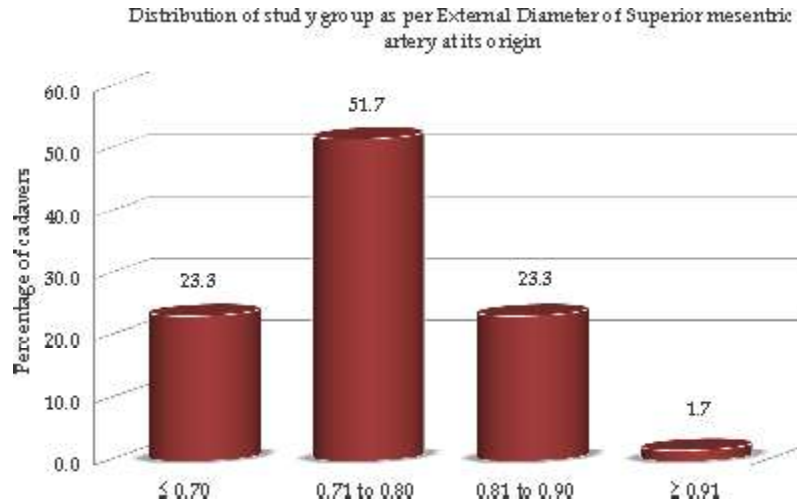
The data was tabulated and statistically analysed for various parameters described subsequently.

Out of 60 cadavers, maximum number (46.7%) of cadavers were having the External diameter of

Coeliac Trunk at its origin in the range of 0.61 cm - 0.70 cm and minimum number (5%) of cadavers were having the same in the group of less than or equal to 0.50 cm (Table 1 and Graph 1).

**Table 2:** External diameter of Superior mesenteric artery at its origin in cm

Distribution by groups		
Diameter in cm	No. of Cadavers	Percent (%)
≤0.70	14	23.3
0.71 to 0.80	31	51.7
0.81 to 0.90	14	23.3
≥0.91	1	1.7
<b>Total (N)</b>	<b>60</b>	<b>100.0</b>



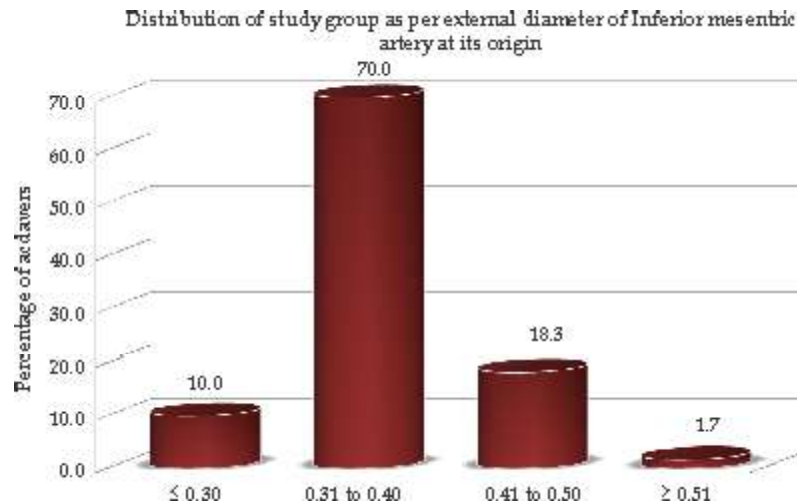
**Graph 2:** The distribution by groups as follows.

Out of 60 cadavers, maximum number (51.7%) of cadavers were having the External diameter of Superior mesenteric artery at its origin, in the range of 0.71 cm – 0.80 cm and minimum number (1.7%)

of cadavers were having the same in the group of more than or equal to 0.91 cm (Table 2 and Graph 2).

**Table 3:** External diameter of Inferior mesenteric artery at its origin (in cm)

Distribution by groups		
Diameter in cm	No. of Cadavers	Percent (%)
≤ 0.30	6	10.0
0.31 to 0.40	42	70.0
0.41 to 0.50	11	18.3
≥ 0.51	1	1.7
<b>Total (N)</b>	<b>60</b>	<b>100.0</b>



**Graph 3:** The distribution by groups as follows.

Out of 60 cadavers, maximum number (70%) of cadavers were having the External diameter of inferior mesenteric artery at its origin, in the range of 0.31 cm – 0.40 cm and minimum number (1.7%)

of cadavers were having the same in the group of more than or equal to 0.51 cm (Table 3 and Graph 3).

## Discussion

We think that the demographic information of the cadavers from which the specimens were taken is consistent with the demographic data of adults in our country. Therefore, we think that the results obtained from AA and its ventral branches can be considered as data belonging to the average individuals.

### *The external diameter of coeliac trunk at its origin*

The external diameter of coeliac trunk at its origin

(0.64 cm) in present study is in agreement with the study of Ahmet Songur<sup>7</sup> (0.64 cm).

Best IM et al. (1991)<sup>8</sup> determined diameter of Coeliac trunk by using 3MHz duplex scanner in 11 normal controls and 14 diabetic patients and found average diameter of coeliac trunk as  $0.8 \pm 0.09$  cm.

Sehgal G. et al. (2013)<sup>9</sup> measured the diameter of Coeliac trunk near its origin in 50 subjects during computed tomographic angiography and found to range from 4 mm to 10 mm.

**Table 4:** Comparison of external diameter of coeliac trunk

Authors	No. of Cadavers	Mean Diameter	Standard Deviation
Pennington (2005) <sup>3</sup>	15	0.76 cm	0.2
Silveira LA et al. (2009) <sup>5</sup>	21	0.79 cm	0.04
D Malnar et al. (2010) <sup>6</sup>	90	0.78 cm	0.08
Ahmet Songur (2010) <sup>7</sup>	95	0.64 cm	0.1
Present study (2013)	60	0.64 cm	0.08

External diameter of coeliac trunk in study by Pennington<sup>3</sup> (0.76 cm), Silveria<sup>5</sup> (0.79 cm) and Malnar<sup>6</sup> (0.78 cm) is more than external diameter of coeliac trunk (0.64 cm) in present study this could be attributed to the racial differences in the study sample. Arterial diameter of celiac trunk branches is of importance especially because of development of organ transplant surgery and precise radiological diagnosis of arterial aneurysms.<sup>6</sup>

### *The external diameter of Superior Mesenteric Artery at its origin*

Akira imura et al. (2007)<sup>10</sup> observed the external diameter of SMA as 0.66 cm in a case report.

Best IM et al. (1991)<sup>8</sup> determined diameter of Superior mesenteric artery by using 3MHz duplex scanner in 11 normal controls and 14 diabetic patients and found average diameter of Superior mesenteric artery as  $0.7 \pm 0.07$  cm.

**Table 5:** Comparison of external diameter of Superior Mesenteric Artery

Authors	No. of Cadavers	Mean Diameter	Standard Deviation
Pennington (2005) <sup>3</sup>	15	0.91 cm	0.2
Ahmet Songur (2010) <sup>7</sup>	95	0.73 cm	0.16
Present study (2013)	60	0.77 cm	0.07

External diameter of Superior mesenteric artery in Pennington<sup>3</sup> study (0.91 cm) is more than external diameter of Superior mesenteric artery in present study (0.77 cm) this could be attributed to the racial differences in the study sample.

### *The external diameter of Inferior Mesenteric Artery at its origin*

External diameter of Inferior mesenteric artery in Pennington<sup>3</sup> study (0.45 cm) is more than external diameter of Inferior mesenteric artery in present study (0.37 cm) this could be attributed to the racial differences in the study sample.

**Table 6:** Comparison of External diameter of Inferior Mesenteric Artery

Authors	No. of Cadavers	Mean Diameter	Standard Deviation
Pennington (2005) <sup>3</sup>	15	0.45 cm	0.1
Ahmet Songur (2010) <sup>7</sup>	95	0.36 cm	0.07
Present study (2013)	60	0.37 cm	0.06

## Conclusion

The knowledge of normal arterial diameters in a specific population is of great importance in order to make correct and precise radiological diagnosis of arterial aneurysms. Also, evaluation of arterial diameters is fundamental for liver transplantation follow up. Previous knowledge of the normal and expected values for a specific artery might help the early diagnosis, through radiological exams, of an arterial stenosis, even before clinical signs of low arterial flow.

## References

1. Borley NR. Chapter 68 Posterior abdominal wall and retroperitoneum. In: Standring S., Collins P., Wigley C., editors. *Gray's Anatomy*. 39<sup>th</sup> Edition. London: Churchill Livingstone, Elsevier Ltd 2005–06. pp.1116–20.
2. McMinn R. M. H. *Last's Anatomy*. 8<sup>th</sup> Edition. Edinburgh. Churchill Livingstone, Medical Division of Longman Group Ltd 1990. p.681.
3. Pennington N, Soames RW. The anterior visceral branches of the abdominal aorta and their relationship to the renal arteries. *Surg Radiol Anat* 2005 Sep;27:395–403.
4. Feller I, Russell MD, Woodburne T. Surgical Anatomy of the Abdominal Aorta. *Annals of Surgery* 1961 Dec;154:239–52.
5. Silveira LA, Silveira FB and Fazan VP. Arterial diameter of the celiac trunk and its branches. Anatomical study. *Acta Cirúrgica Brasileira* 2009;24(1):43–47.
6. Malnar D, Klasan GS, Miletic D, et al. Anatomical Properties of the Celiac Trunk. *Coll. Antropol* 2010;34(3):917–21.
7. Songür A, Toktaş M, Alkoc O, et al. Abdominal Aorta and Its Branches: Morphometry - Variations In Autopsy Cases. *European Journal of General Medicine* 2010;7(3):321–325.
8. Irwin M Best, Annette Pitzele, Andrew Green et al., Mesenteric blood flow in patients with diabetic neuropathy 1991;13(1):84–89.
9. Sehgal G, Srivastava A, Sharma P, et al. Morphometry of celiac trunk: A multidetector computed tomographic angiographic study. *Journal of The Anatomical Society of India* 2013;62(1):23–27.
10. Jimura A, Oguchi T, Shibata M, et al. An Anomalous Case of the Hepatic Artery Arising from the Superior Mesenteric Artery. *Okajimas Folia Anat Jpn*. 2007 Aug;84(2):61–5.