

Leiomyoma of Vulva

Ramesh Babu Chidambaram*, K. Rama**

*Postgraduate, Institute of Pathology, Madras Medical College, Chennai, Tamil Nadu. **Professor, Department of Pathology, Kasturba Hospital, Madras Medical College, Chennai, Tamil Nadu.

Abstract

Leiomyoma is a benign soft tissue tumor that arises from the smooth muscle, commonly occurs in Uterine Myometrium. Extrauterine Leiomyoma are rare. Smooth muscle tumors may arise from the erector pili muscle, the erectile tissue, insertion of the round ligaments and are usually well circumscribed. Vulval Leiomyomas are rare in occurrence with as few as 300 cases reported in the literature. In our institution this is the first case of Vulval Leiomyoma among the 37 Extrauterine Leiomyoma during January 2013 to June 2016. Hence we report a case of Vulval Leiomyoma, clinically diagnosed as Bartholins cyst.

Keywords: Vulval Leiomyoma; Extrauterine Leiomyoma; Leiomyoma.

Introduction

Leiomyoma is a benign soft tissue tumour that arise from the smooth muscle, account for 3.8% of all benign soft tissue tumor. Most common site is Uterine myometrium. Extrauterine Leiomyoma commonly affects the bladder, labia majora, labia minora, ovaries, urethra. Labia majora being the most common site. Median age group varies from 13 to 71 years. The tumor size varies from 0.5 to 15cm. Clinically there is a possibility of misdiagnosis, being an uncommon location. Extrauterine leiomyoma are rare and considered as greater diagnostic challenge.

Case Presentation

A 45 year old female admitted with a history of swelling in the right labia majora for 5 months. On examination, there was a mass measuring 1x1cm over the right side of labia majora. The mass had smooth surface and firm in consistency. The mass was clinically diagnosed as Bartholin gland cyst and excision of the cyst was done. Grossly the cyst was

well circumscribed, measuring 2x1cm. Cut surface showed whitish solid area (Figure 1). Microscopy showed an encapsulated neoplasm arranged in bundles and interlacing fascicles. The cells are spindle to oval shaped with dark staining eosinophilic nucleus. There was no cytological atypia or necrosis (Figure 2 & 3). Impression given as Vulval Leiomyoma. IHC was done to confirm the diagnosis of Vulval Leiomyoma. SMA (Figure 4) and Desmin (Figure 5) showed positivity in the smooth muscle. Van Gieson special stain also done (Figure 6).

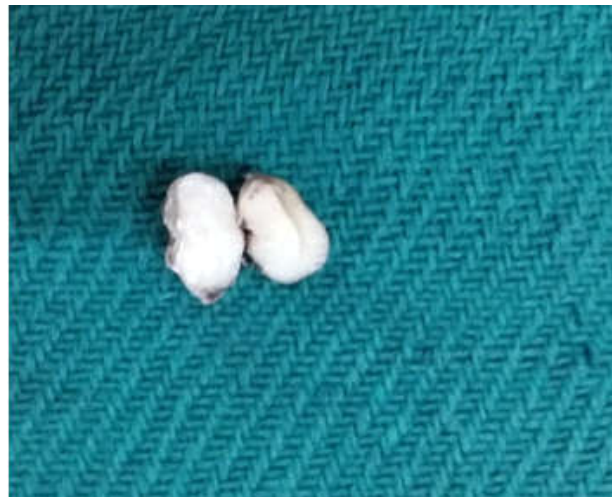

Fig. 1: Gross specimen - cut surface showing whitish areas

Corresponding Author: C. Ramesh Babu, 53/23, Patchaiappan Street, Mount Road, Chennai-600002, Tamil Nadu.

E-mail: dr raja1981@gmail.com, dr raja81@yahoo.com

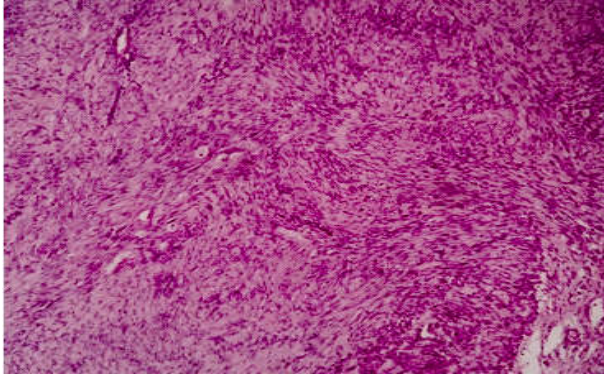


Fig. 2: Images showing bundles and fascicles of benign spindle shaped cells (H&E,10X)

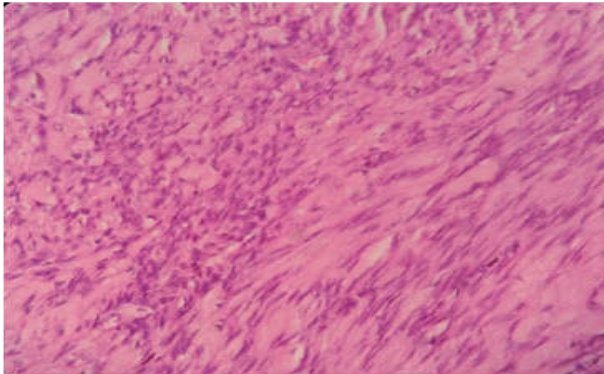


Fig. 3: Images showing bundles and fascicles of benign spindle shaped cells (H&E, 40X)

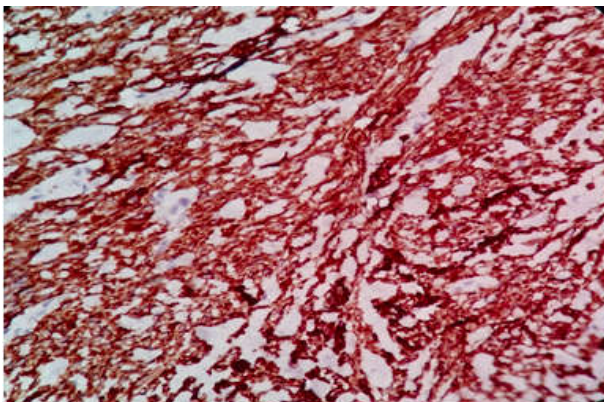


Fig. 4: Image showing SMA positivity ,40X

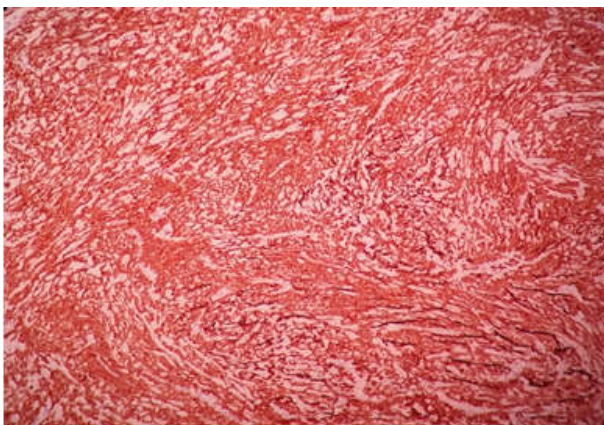

Fig. 5: Image showing DESMIN positivity,10X

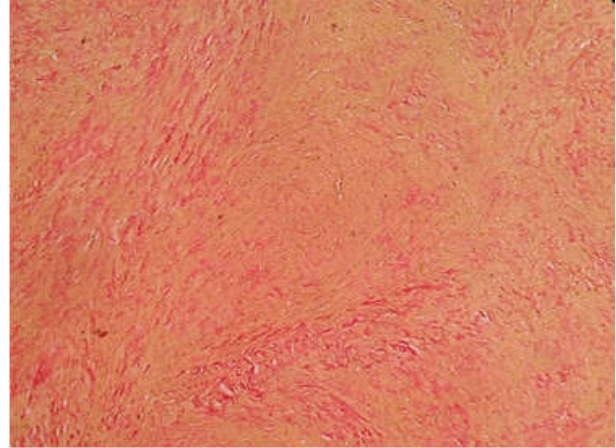


Fig. 6: image showing Van Gieson special stain ,muscle taken yellow colour, collagen taken red colour (under 10X magnification)

Discussion

Leiomyoma accounts for 3.8% of all benign soft tissue tumor and 0.03% of all patients with gynaecological neoplasm [1]. Uterine myometrium being the commonest site. Extrauterine leiomyoma commonly seen in urinary bladder, ovary, urethra. The most common site being labia majora. Vulval leiomyoma are rare in occurrence with as few as 300 cases reported in the literature [2].

Vulval leiomyoma are most commonly seen in anterior vaginal wall. Leiomyoma typically present as single mass and are well circumscribed. The size of the tumor vary from 2 to 10 cm. Most of the patients were asymptomatic. Vulval leiomyoma may be clinically misdiagnosed as Bartholin's cyst, lipoma or fibroma.

Bartholins abscess needs to be re-examined once the inflammation subsides. Inverted labia minora, firm consistency and intact hymen leading towards reconsidering the diagnosis. Smooth muscle tumours though rare but do occur in vulva. On initial presentation most of the Vulval Leiomyoma are usually misdiagnosed as Bartholin cyst or abscess [1]. USG and MRI are most commonly used for diagnosis though histopathology of the surgical specimen is the gold standard for diagnosis [3].

The most confusing problem with vulval smooth muscle tumor is to distinguish benign from malignant. Nielsen et al. evaluated the tumors on the basis of size (≥ 5 cm), infiltrative margins, mitoses ($\geq 5/10$ HPF), and moderate to severe cytologic atypia. Tumors that had three or all four of these features were regarded as leiomyosarcomas, tumors that had none or one of the features were called leiomyomas, and tumors that had two features were designated atypical leiomyomas.

Nielson et al performed clinicopathological study of 25 cases of vulval smooth muscle tumors and reviewed the literature. Most of these swellings were diagnosed as Bartholins cyst prior to surgery. There were 20 cases with leiomyoma and 5 with leiomyosarcoma. There was recurrence of disease in 1 of 20 and 4 of 5 cases with leiomyoma and leiomyosarcoma respectively [4].

In 2002 Kajiwarra et al performed a literature review which showed in a selection of 36 cases of vulval smooth muscle tumors (2 of which were their own cases); 27 were typical leiomyoma, 4 were atypical leiomyoma, 5 were leiomyosarcoma [5].

CT may not be of much use in delineating these tumors because of its inherent poor soft tissue contrast. Low signal intensity mimicking that of smooth muscle on T2 weighted images is the key to diagnosis. A typical whorled appearance at USG and signal intensity similar to that of smooth muscle at T1 and T2 weighted MRI imaging strongly favors the diagnosis of leiomyoma [6].

Vulval leiomyoma is an estrogen dependent neoplasm. Estrogen-progesterone therapy was closely related to recurrent vulval leiomyoma. Labial leiomyoma are treated with conservative surgery. Longterm follow up is advisable.

Conclusion

Vulval Leiomyoma are very rare. It can be treated by conservative surgery. These tumors rarely metastasize but chances of recurrence are known. So long term

follow up is advisable. USG and MRI helps in the diagnosis, but histopathology is the gold standard. Good clinical history and evaluation of the patient, histopathology examination with proper immunohistochemistry studies helps to establish an accurate diagnosis.

References

1. A. Youssef, K. Neji, M.M. Barki, F. Ben Amara, M. Malek and H. Rezig, leiomyoma of the vulva, *La Tunisie Medicale*, 2013; 91(1):78-80.
2. Devalla A, Warke HS, Mayadeo NM, Vulval leiomyoma; A case report, *Journal Postgraduate Gynaecology and Obstetrics* 2016; 3(3).
3. Deeksha Pandey, Jyothi Shetty, Aashish Saxena and P.S. Srilatha, Leiomyoma in vulva: A diagnostic dilemma, case reports in obstetrics and gynecology, 2014; p3. article id 386432.
4. G.P. Nielson, A.E. Rosenberg, F.C. Koerner, R.H. Young, R.E. Scully, Smooth muscle Tumors of the Vulva: A Clinicopathological study of 25 cases and review of literature, *The American Journal of Surgical Pathology* 1996; 20(7):779-793.
5. Kajiwarra H, Yasuda M, Yahata G, Yamauchi I, Satoh S, Hirasawa T, Osamura RY. Myxoid leiomyoma of the vulva a case report. *Tokai J Exp Clin Med*, 2002; 27(3): 57-64.
6. Fasih N, Prasad SAK, Macdonald DB, Fraser-Hill MA, Papadatos D, Kielar AZ et al. Leiomyomas beyond the uterus, unusual locations, rare manifestations. *Radiographics*, 2008 Nov-Dec; 28(7):1931-48.