

Denture Fabrication in Resorbed Mandibular Ridge using Modified Impression Technique – A Case Report

Pankaj Datta¹, Yuvraj Kapoor²

Author's Affiliation: ¹Dean, Professor & Head, ²Post Graduate Student, Department of Prosthodontics and Crown & Bridge, Inderprastha Dental College and Hospital, Ghaziabad 201301, Uttar Pradesh, India.

Corresponding Author: Pankaj Datta, Dean, Professor & Head, Department of Prosthodontics and Crown & Bridge, Inderprastha Dental College and Hospital, Ghaziabad 201301, Uttar Pradesh, India.

E-mail: pankajdatta97@gmail.com

How to cite this article:

Pankaj Datta, Yuvraj Kapoor/Denture Fabrication in Resorbed Mandibular Ridge using Modified Impression Technique – A Case Report/Indian J Dent Educ. 2021;14(1):25-28.

Abstract

The complete edentulism is most often witnessed among geriatric age group undergoing changes associated with ageing. One of the commonest issues of concern among such patients as well as the Prosthodontists is continuous loss of alveolar bone and its consequences. Making an impression of such resorbed ridges is often very troublesome to the dentist as the tissues become unsupported and displaceable thereby, jeopardising the success of the prosthesis. The key to such cases is to record the supporting tissue in its resting state while maintaining its integrity. This clinical case report presents a case of severely resorbed ridge managed using the cocktail impression technique to improve mandibular denture stability in an atrophic mandibular ridge.

Keywords: Resorbed Mandibular Ridge; denture Fabrication; Modified Impression Technique.

Introduction

Alveolar bone is always under constant bone remodelling and requires constant stimulation to maintain its strength, form, function, and density¹. In the presence of teeth all the compressive and tensile forces are transmitted to the surrounding bone. However, once a tooth is lost from its bony socket the bone is not stimulated in the same fashion as it was in the presence of a tooth. The load is transferred directly to the bone surface rather than its internal structure thus leading to residual ridge resorption².

Residual ridge resorption is an inevitable process following tooth extractions, which continue even after healing of the extraction socket. Ridge resorption is more pronounced in the mandible and is most dramatic during the first year after tooth loss followed by a slower but more progressive rate of resorption thereafter³.

Highly resorbed mandibular ridge is a common finding in the elderly. Along with it there are several confounding factors like, thin atrophic

mucosa, lower threshold of pain, diminished resiliency of tissues and reduced muscle tonicity accompanied by poor adaptive capacity⁴, which make the prognosis guarded. All these factors combined make it difficult for a prosthodontist to provide the patient with a prosthesis that is stable and functions optimally⁵.

Although there are many surgical options available for ridge augmentation but only few patients opt for it because of the tomophobia and persisting co-morbidities which directly or indirectly affect the surgical interventions⁶.

Thus, recording an accurate impression of the atrophic ridge is the first step towards a successful prosthesis in such cases. As it helps to attain adequate support and ensures that the denture is stable, which provides physiological comfort to the patient⁷. So, efforts have been made to improve the stability of mandibular denture by combining various techniques to obtain an accurate impression.

Cocktail impression technique⁸ is one such technique which is a combination of various other impression techniques to obtain a definitive

impression. The technique described here utilizes the customized tray fabricated according to dynamic impression technique described by Tryde⁹, impression material recommended by McCord and Tyson's technique¹⁰ for atrophic mandibular ridge followed by functional impression as in close mouth technique.

Case Study

A 55 years old male patient came to the department of Prosthodontics and Crown and Bridge, with a chief complaint of difficulty in talking and chewing food with his old dentures due to loss of teeth in both upper and lower arch. A thorough medical and dental history was elicited from the patient followed by clinical and radiographic examination. Dental history revealed that he had lost his teeth due to periodontal involvement and had been edentulous for three years.

Intra-oral examination revealed a resorbed ridge of order III in maxilla and a atrophic ridge of order V in mandible respectively, according to Atwood classification³ (Fig. 1).

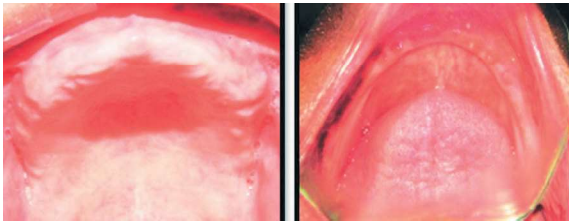


Fig. 1: Intraoral view of maxillary and mandibular residual ridge.

Treatment options discussed were pre-prosthetic surgery including ridge augmentation followed by conventional complete denture or implant supported prosthesis. All treatment modalities were discussed at length with the patient. Patient preferred to opt for a conventional complete denture as the patient did not want to go for any surgical procedures associated. Time, cost & phobia of the surgical procedures were the factors which turned the patient's decision in favour of conventional complete denture.

After analysing the severity of resorption associated with mandibular ridge it was decided to fabricate a conventional maxillary complete denture and a mandibular complete denture using cocktail impression technique. The patient was informed about the procedure and informed consent was taken.

Technique

Preliminary impression were made with impression compound (Fig. 2) using open mouth technique

and poured with type II gypsum plaster.

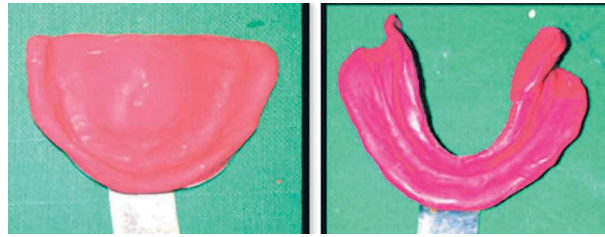


Fig. 2: Maxillary and mandibular primary impressions

Customized tray with 1 mm wax spacer and cylindrical mandibular rests (concave lingually to provide space for tongue) in the posterior region were made at increased vertical height fabricated with auto-polymerizing acrylic resin according to dynamic impression technique⁹ (Fig 3).

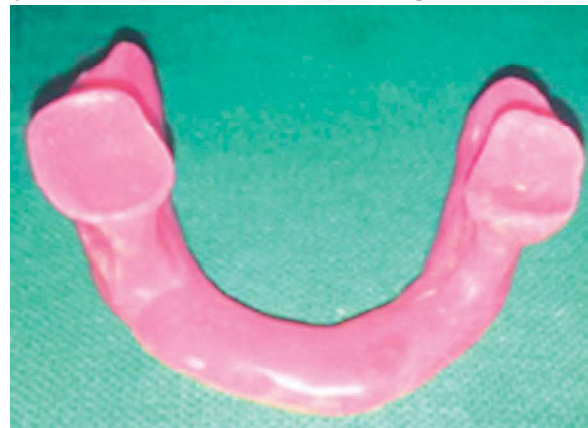

Fig. 3: Customized impression tray.

The final impression was made using cocktail impression technique in which initially impression compound was softened, placed on top of the mandibular rests and inserted in the patient's mouth. Patient was advised to close his mouth such that the mandibular rest fit against the maxillary alveolar ridges (Fig 4). This helps to stabilize the tray in position by preventing antero-posterior and medio-lateral displacement of the tray during definitive impression.

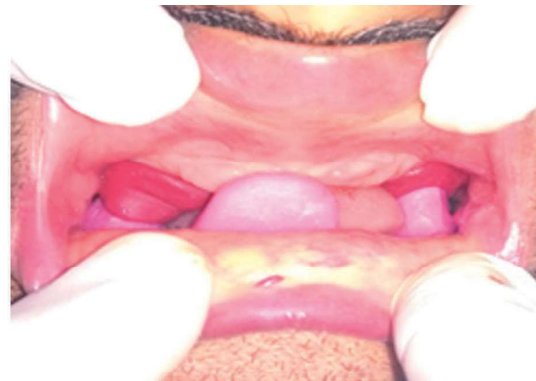

Fig. 4: Final impression being made using cocktail impression technique.

McCord and Tyson's technique¹⁰ for flat mandibular ridges was then followed for definitive impression. According to this technique, impression compound and green tracing stick in the ratio 3:7 parts by weight was placed in a bowl of hot water (60° C). Hand kneading was done to obtain a uniform mass and then loaded into the customized tray after removal of wax spacer and the patient was instructed to close his mouth on the mandibular rests which fits against the maxillary alveolar ridge helping to stabilize the tray. For recording the functional state of the oral tissues, patient was instructed to run his tongue along the vermilion border of the lips, suck in his cheeks, pull in his lips and swallow by keeping his mouth closed till the impression material hardens (Fig. 5).

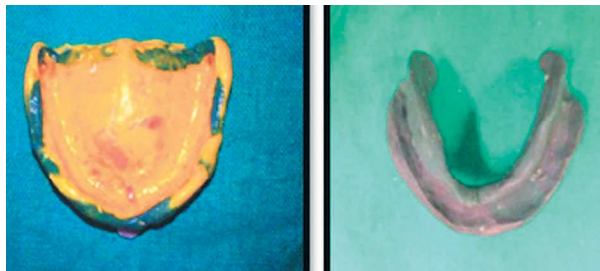


Fig. 5: Maxillary and mandibular final impressions

The final impressions were poured with type III dental stone. Record base using auto polymerizing acrylic resin and occlusal rims were fabricated and Jaw relation recorded in a conventional manner (Fig 6).

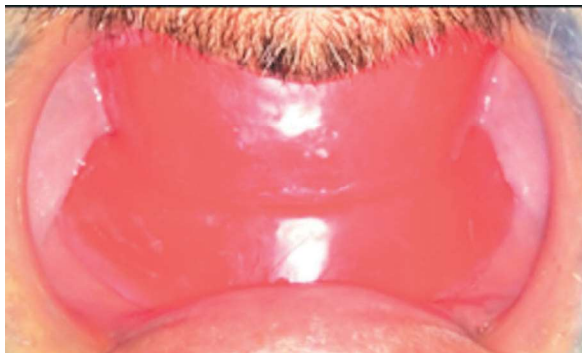

Fig. 6: Jaw relation recorded.

Trial was done to evaluate the retention, stability, aesthetics and phonetics as usual before the final insertion (Fig 8).

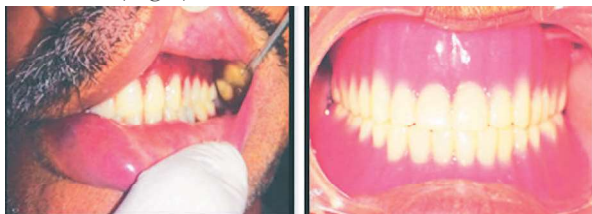

Fig. 7: Trial insertion and Fig. 8: Final denture.

Discussion

To make any removable prosthesis a success, it relies on the three fundamental parameters of retention, stability and support⁶. But the same is difficult to achieve with extensively resorbed ridges which is a common finding among geriatric patients.

In a patient with accentuated bone resorption, it is difficult to obtain good retention and stability of the prosthesis as the muscle attachments are located near the crest of the ridge, causing greater dislocating effect on the prosthesis⁴.

For these reasons, the range of muscle action, as well as spaces into which the denture can be extended without dislocation, must be accurately recorded in the impression. Such impressions can be made by means of dynamic methods, as with cocktail impression technique⁸.

Customised tray that is fabricated in this technique has the advantage of avoiding the dislocating effect of the muscles on denture borders. The mandibular rests that fit against the maxillary alveolar ridge offer the advantage to stabilize the custom tray by preventing horizontal displacement of the tray during definitive impression.

These features of the tray result in impression material being shaped by the functional movements of the muscles and their attachments, giving the much desired shape to the denture borders. This technique helps in achieving an accurate, stable, functional impression in a single clinical step.

Conclusion

This impression technique combines both traditional and contemporary methods which results in a prosthesis which provides better retention, stability and support in cases with Atwood's Order V & VI ridge deformities.

References

1. Pietrokovski J. The bony residual ridge in man. *J Prosthet Dent.*1975; 34:456-62.
2. Gruber H, Solar P, Ulm C. Maxillo-m a n d i b u l a r a n a t o m y a n d patterns of resorption during atrophy. *Endosseous implants: scientific and clinical aspects*, Chicago, Quintessence. 1996; 29-62.
3. Atwood DA. Post extraction changes in the adult mandible as illustrated by microradiographs of midsagittal sections and serial cephalometric roentgenograms. *J Prosthet Dent.* 1963; 13: 810-24.
4. Atwood DA. The problem of reduction of residual ridges. In: Winkler S (ed) *Essentials*

- of complete denture prosthodontics. 2nd edn, Ishiyaku EuroAmerica, St Louis. 1996; 22-38.
5. Prithviraj DR, Singh V, Kumar S, Shruti DP. Conservative prosthodontic procedure to improve mandibular denture stability in an atrophic mandibular ridge. JIPS. 2008;8:178-83.
 6. Fernandes V, Singh RK, Chitre V, Aras M. Functional and aesthetic rehabilitation of a patient with highly resorbed, asymmetrical residual ridge. JIPS. 2001; 1: 22-4.
 7. Jacobson TE, Krol AJ. A contemporary review of the factors in complete denture retention, stability and support. J Prosthet Dent. 1983; 49: 306-13.
 8. Praveen G, Gupta S, Agarwal S, Agarwal SK. Cocktail Impression Technique: A New Approach to Atwood's Order VI Mandibular Ridge Deformity. JIPS. 2011; 1:32-5.
 9. Tryde G, Olsson K, Jensen SAA, Cantor R, Taretano JJ, Brill N. Dynamic impression methods. J Prosthet Dent. 1965; 15: 1023-34.
 10. McCord JF, Tyson KW. A conservative prosthodontic option for the treatment of edentulous patients with atrophic (flat) mandibular ridges. Br Dent J. 1997; 182: 469-72.
-
-