

A Rare Case of Unilateral Star Shaped Cataract Following Electric Shock

Meena Ashok Kr*, Soni Akshar**, Gupta Tarun***

Authors Affiliation: *Professor & Head, **3rd Yr Resident ***2nd Yr Resident, Department of Ophthalmology, Government Medical College, Kota, Rajasthan.

Abstract

A 25 year old male reported to eye- opd with complaint of diminution of vision of left eye for 20 days following electric shock (11,000v) approximately three months back. On examination he had a unilateral star shaped anterior subcapsular cataract in his left eye. He was operated for cataract and achieved 6/6 and N6 visual acuity 3 weeks after surgery. This case highlights rare unilateral cataract following electric shock and excellent outcome following surgery provided fundus and optic nerve are unaffected. Need for awareness of this complication and screening of all cases of electric injury is emphasized.

Keywords: Anterior Subcapsular Cataract Electric Shock; Unilateral Star Shaped Cataract.

Introduction

Systemic complications from electrical injury can be multisystemic, varied, debilitating, and are frequently fatal[1]. It can result in a wide range of ocular injuries with resultant ocular complications [2,3]. Cataracts develop in approximately 6% of cases of high-voltage injuries, especially whenever electrical injury occurs in the vicinity of the head [4]. Of these, electrical cataract can occur after a latent period and then progress with startling rapidity [5]. However proper surgical management can result in good and stable visual acuity as is seen in this case. The need for awareness of the possibility of this complication and screening of all cases of electrical injuries is stressed.

This is a case report of unilateral star shaped cataract in a 25 year old male secondary to electric shock.

Key Message

Unilateral star shaped cataract following high voltage electric shock and excellent outcome

following surgery provided fundus and optic nerve are unaffected. Need of screening of all cases of electric shock so that this complication can be managed early and effectively.

Case Report

A 25yr old male with a history electric shock reported to eye-opd with complaint of diminution of vision in his left eye for 20 days. Patient had sustained an electric shock from a high tension line (11,000 volts) approximately three months back while he was working in fields. Patient got unconscious and was admitted in our hospital for burns on his body. The electric current passed from his left hand and exited through his right foot (Figure 1). He received burn on his left arm, trunk, right hand and right foot for which his left arm had to be amputated below elbow.

Reprint Request: Ashok Kumar Meena,
27, Atwal Nagar, Kota-324001, Rajasthan.
E-mail: dr.ashokmeena10@gmail.com

On examination visual acuity of his right eye was 6/6 and left eye has only finger counting at 2m improving to 6/36 with pinhole. Right eye examination was within normal limits whereas left eye had a characteristic anterior subcapsular star shaped cataract (Figure 2) and posterior subcapsular cataract (Figure 3) with normal depth of anterior chamber and fundus was not clearly visible.

He was operated for left eye cataract and a posterior chamber IOL was placed. The surgery was

uneventful.

His first post-op day vision was 6/36 improving to 6/18 with pinhole. Cornea was clear, anterior chamber was deep, and good red reflex was seen.

On review 3 weeks later, his best corrected visual acuity is 6/6, N6 in left eye.

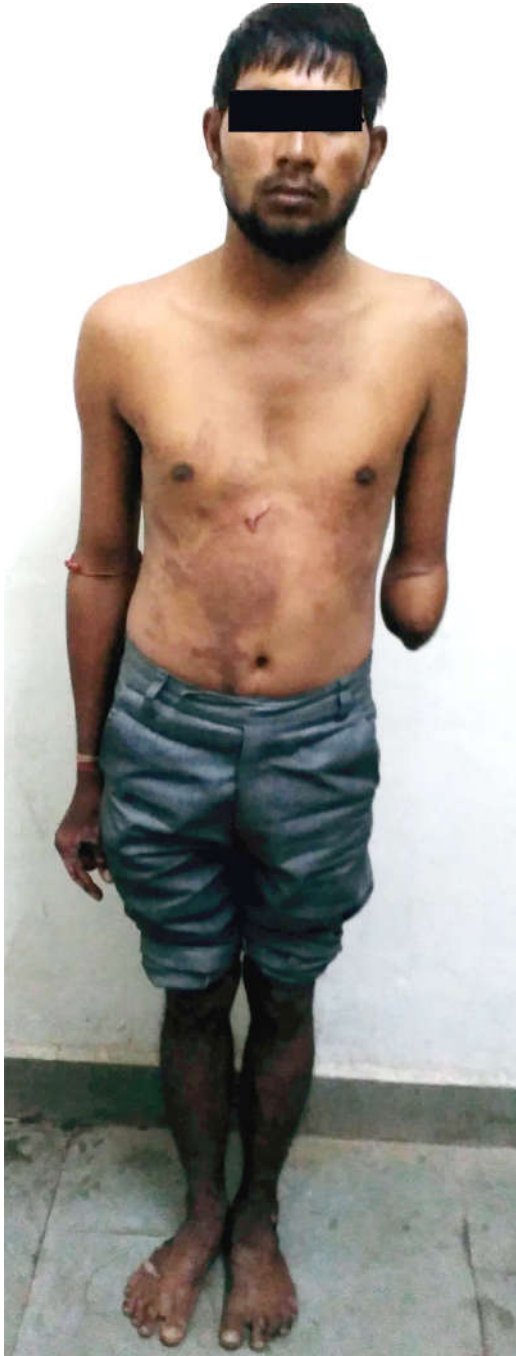

Fig. 1: Amputated left hand and arrow showing exit wound

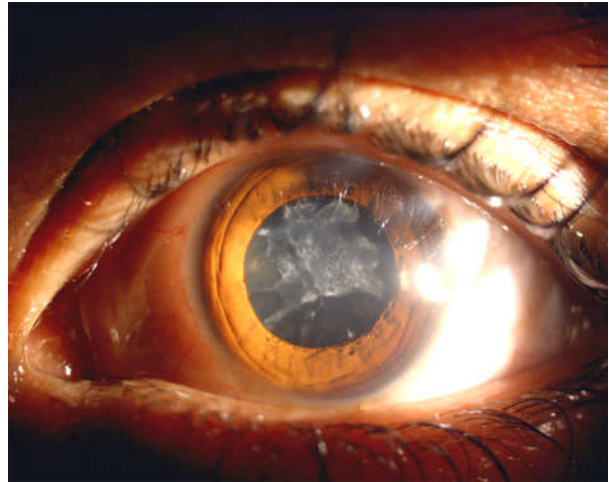


Fig. 2: Star shaped anterior subcapsular cataract

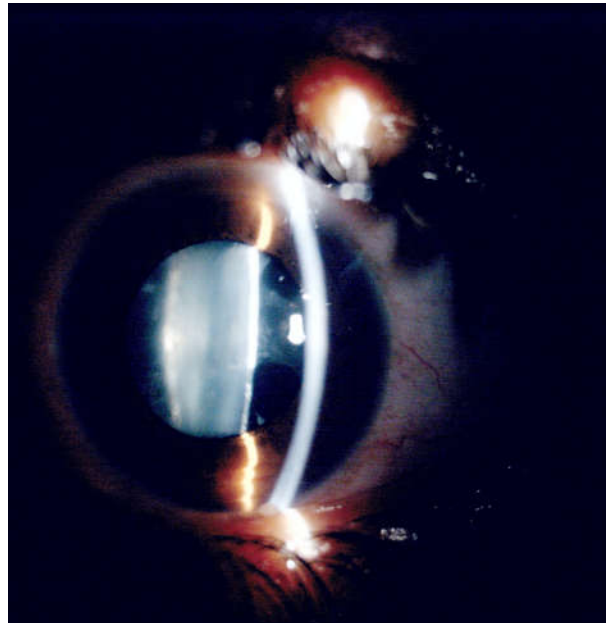

Fig. 3: Anterior and posterior subcapsular cataract

Discussion

High voltage electric burns can cause various ocular injuries and may manifest in the form of conjunctival hyperemia, corneal opacities, uveitis, miosis, spasm of accommodation, cataract, retinal edema, papilledema, chorio-retinal necrosis/atrophy, retinal detachment and optic atrophy.

Choroidal rupture, optic neuritis and retinal detachment may also be seen. Macular edema may progress to macular cysts or holes [2,3,6]. Although a number of these ocular changes occur immediately after injury [7], many develop days and even years after [4,6]. The cataract may develop immediately after injury or be delayed a few days; the latency varies from 1 to 18 months [8] although a latent period of 11 years has also been reported [9]. It is usually bilateral [2] but can also occur unilaterally [7]. If the point of contact is near to one side, the cataract may develop on that side first and then on the other side. The interval between cataracts occurring in the 2 eyes can vary from 3 weeks to 2 years. As in this case who developed unilateral cataract. Cataract usually occurs 1-12 month [4] after the accident and is frequently associated with no other observable ocular damage. The exact pathogenesis of these cataracts is unknown, but direct coagulation of proteins and osmotic changes following damage to the subcapsular epithelium are thought to be responsible [2]. The earliest changes seen in the lens after electrical injury are a collection of multiple fine vacuoles beneath the anterior capsule, usually in the midperiphery of the lens, requiring dilation of the pupil for visualization. These collections are always present in the anterior subcapsular area and show no apparent relationship to lens fiber configuration. Over intervals varying from weeks to months, these vacuoles are replaced with flake-like opacities that coalesce and migrate into the line of vision. Electrical burn can cause scar formation in the anterior capsule, leading to impairment of lens nutrition and, eventually, cataract formation.

Rarely, the cataract may become complicated by secondary glaucoma in the intumescent stage [10].

Thus, proper surgical management of electric cataract will result in a good visual rehabilitation if the eye has otherwise escaped damage as in this case.

Conclusion

Electric injuries can cause unilateral or bilateral cataracts. Proper and timely management of electric cataract have excellent outcome provided fundus and optic nerve are unaffected.

References

1. Demling RH. Electrical trauma: pathophysiology and clinical management. In: Lee RC, Cravalho EG, Burke JF, eds. *Electrical Trauma: The pathophysiology, manifestations and clinical management*. Cambridge: Cambridge University Press. 1992: 122-132.
2. Boozalis GT, Purdu GF. Ocular changes from electric burn injuries: a literature review and report of cases. *J Burn Care Rehabil*. 1991; 12: 458-62.
3. Albert, Jakobiec. *Principles and Practice of Ophthalmology, Posterior Segment Trauma*. Philadelphia: Paul Dieckert, B Saunders Company; 1994: 3419.
4. Saffle J R, Crandall A :Cataracts a long term complication of electrical injury. *J Trauma*. 1985 Jan; 25(1): 17-21.
5. Stephen V, John SR, Chakraborty A, Chakrabarti M. Bilateral cataract following electrical injury. *Kerala J Ophthalmol*. 2006; 18(3): 252e254.
6. Grewal DS, Jain R, Brar GS, Grewal SPS. Unilateral electric cataract: Scheimpflug imaging and review of the literature. *J Cataract Refract Surg*. 2007; 33(6): 1116e1119.
7. Mutlu FM, Duman H, Cil Y. Early-onset unilateral electric cataract: a rare clinical entity. *J Burn Care Rehabil*. 2004; 25: 363-365.
8. Duke-Elder S, MacFaul PA. Injuries; Non-Mechanical Injuries. In: Duke-Elder, ed, *System of Ophthalmology*. London, Henry Kimpton. 1972; 14(2): 813-835.
9. Skoog T. Electrical injuries. *J Trauma*. 1970; 10: 816-830.
10. Reddy SC. Electric cataract: a case report and review of the literature. *Eur J Ophthalmol*. 1999; 9: 134-138.