

## Acute Onset Quadriplegia as a Complication of Hepatitis a Infection: A Case Report

Noorulla Khan Mayana<sup>1</sup>, Mohammed Ismail Nizami<sup>2</sup>, Kiran Kumar Ramineni<sup>3</sup>, Kiran Kumar Verma<sup>4</sup>

**Author's Affiliation:** <sup>1</sup>Senior Resident, <sup>2</sup>Assistant Professor, <sup>3</sup>Consultant Neurophysician, <sup>4</sup>Consultant Emergency Physician and HOD, <sup>1,2</sup>Department of Emergency Medicines Nizam's Institute of Medical Sciences Hyderabad, <sup>3,4</sup>Department of Emergency Medicines Yashoda Super Speciality Hospital, Malakpet Hyderabad 500024, India.

**Corresponding Author:** Mohammed Ismail Nizami, Assistant Professor, Department of Emergency Medicines Nizam's Institute of Medical Sciences Hyderabad 500024, India.

**Email:** [ismil\\_nizami@rediffmail.com](mailto:ismil_nizami@rediffmail.com)

### How to cite this article:

Noorulla Khan Mayana, Mohammed Ismail Nizami, Kiran Kumar Ramineni, et al./ Acute Onset Quadriplegia as a Complication of Hepatitis A infection: A Case Report. Indian J Emerg Med. 2021;7(3):21–23.

### Abstract

Acute onset quadriplegia is a potentially treatable neurological emergency. Common etiologies include radiculoneuropathies, compressive and non-compressive myelopathies. Spontaneous non traumatic spinal epidural hematoma is a relatively uncommon phenomenon. Here we report an interesting patient who developed coagulopathy related spinal epidural hematoma resulting in acute painful quadriplegia as a complication of hepatitis A infection.

**Keywords:** Coagulopathy; Spontaneous spinal epidural hematoma; Hepatitis A; Quadriplegia.

### Introduction

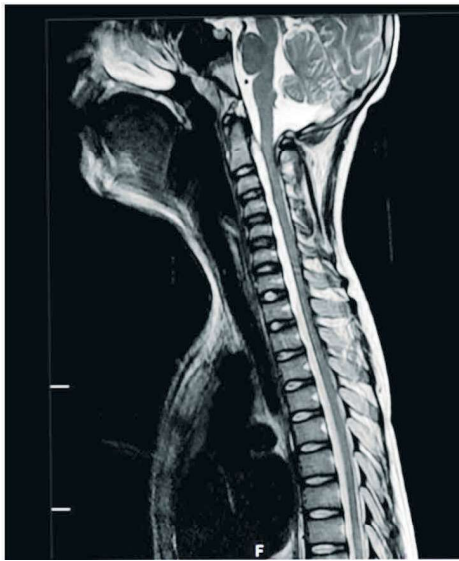Acute hepatitis due to Hepatitis A virus is usually a benign self-limiting disease conferring longterm immunity. Hepatitis A virus (HAV) infection rarely causes fulminant hepatic failure in people with no underlying liver disease.<sup>1</sup> The outcome of Hepatitis A in patients with chronic Hepatitis B has been addressed in few reports.<sup>2</sup> HAV is a single-stranded, positive-sense, linear RNA entero-virus of the Picornaviridae family. Virus acquisition results almost exclusively from ingestion fecal oral transmission, although isolated cases of parenteral transmission have been reported. In general, the prognosis is good and recurrence or progression to chronic hepatitis do not occur usually. We report this extremely rare case of an adolescent male who developed acute onset quadriplegia due to severe coagulopathy induced spinal epidural hematoma as a complication of viral Hepatitis A infection.

### Case presentation

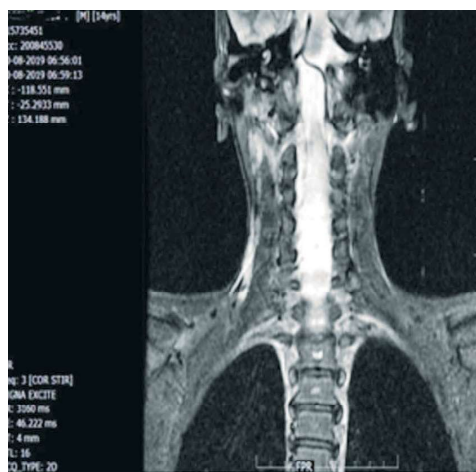
A 14 years old boy was brought to the emergency department with history of sudden onset neck pain, one episode of non - bilious vomiting after getting up from bed followed by weakness of lower and upper limbs which progressed to trunk and respiratory muscle weakness and urinary retention over few hours. There was no history of headache, seizures or altered sensorium. He had a history of fever with jaundice 14 days back and was diagnosed as viral hepatitis A. He was treated symptomatically and discharged. There was no past history of any significant neurological illness, trauma or bleeding manifestations. He was born to non-consanguineous marriage with normal development.

On examination patient was moderately built and nourished. He had a pulse rate of 104/min, blood pressure of 110/70 mmHg in rightarm, respiratory rate of 30/min, Spo2 98% on room air

and temperature of 99 degree F. Single breath count (SBC) was.<sup>8</sup> General examination revealed deep icterus. Cardiovascular examination and chest auscultation were unremarkable and abdomen was soft. On neurological examination he was conscious, irritable but obeying commands. Pupils were bilateral 2mm reacting to light, no nystagmus, normal fundus, no facial weakness and other cranial nerves examination was grossly normal. He was unable to lift his neck against gravity, power in all 4 limbs was grade 1/5 with hypotonia and deep tendon reflexes were absent with extensor plantars. Sensory level was appreciated at T5/T6 level and patient had urinary retention.



**Fig. 1:** MRI Sagittal view showing anterior epidural collection with layering extending from C2 to D8 level causing posterior displacement and compression of cervical and dorsal cord likely due to haemorrhage.



**Fig. 2:** MRI Coronal view showing mild sprain of posterior paraspinal soft tissues in cervical region.

MRI of whole spine with brain was done which revealed long segment anterior epidural collection (Figure 1) which was hyper intense on T2 and hypointense on T1. Complete blood picture revealed a low hemoglobin of 7.5gr %. Leucocytes and platelets were within normal limits. Liver function tests were grossly deranged with a Bilirubin of 21.90 mg% (Direct-13.70 and Indirect-8.20), SGPT 254u/l, SGOT 180u/l, Alk phosphatase 265.00 and total proteins 6.00 g%. PT was 68.0 sec, INR >8.0 and APTT was 86.8 sec. HAV IgM antibody was positive. HBsAg, HBeAg, HCV and HIV were not reactive. ANA profile was negative.

Patient was admitted in intensive care unit and received 7 units of FFPs, 3 PRBCs along with parenteral Vitamin K injections and ventilatory supportive care. Neuro-surgery consultation was taken followed by C3-C6 laminoplasty with evacuation of hematoma done on day 2 of admission. On day 5 tracheostomy was done and patient was gradually weaned of ventilator. He was discharged on day 15 with non-invasive ventilatory support to rehabilitation centre. Quadriplegia was persisting with grade 2 power in upperlimbs and grade 1 in lower limbs.

At two weeks follow up he improved further with spastic quadriplegia-grade 2 power in all limbs, stable hemodynamics and normal liver function tests.

## Discussion

Neurological complications from hepatitis A are rare which include encephalitis, meningitis, Guillain-Barre syndrome, chronic inflammatory demyelinating polyradiculo-neuropathy, sensory neuropathy, mono-neuropathy simplex and multiplex, myasthenia gravis, myopathy and transverse myelitis.<sup>3</sup>

Our patient with history of HAV -Acute hepatitis diagnosed 14 days back presented with rapidly progressive ascending type of paralysis leading to respiratory muscle weakness. The presence of bladder involvement early in the course and bilateral extensor plantars in examination raised the possibility of alternative diagnoses other than Guillain Barre syndrome. The differentials for acute flaccid paralysis with extensor plantars include bilateral anterior cerebral artery infarct, bilateral medial medullary syndrome and acute transverse myelitis. Magnetic resonance imaging (MRI) of whole spine with brain was done, which showed spinal epidural hematoma extending from C2 to D8 level causing posterior displacement and compression of cervical and dorsal cord. MRI brain was normal.

Spontaneous spinal epidural Hematoma is frequently defined as occurring in the absence of any trauma and any iatrogenic procedure. This definition includes hematomas secondary to many causes including vascular malformations, coagulopathy and tumors.<sup>4,5</sup> The term non-traumatic spinal epidural hematoma is used alternatively for such conditions.<sup>6</sup>

Intraspinal hemorrhage was initially described by Du-Verney in 1688, although a later description of SSEH in a 14-year-old female by Jackson in 1869 often is considered the initial report of this entity.<sup>7</sup> Irritability and neck pain in an afebrile child may be early sign of SSEH and often precede the onset of neurologic deficits by several hours to days (8,9). These signs should alert the treating clinician to consider SSEH and need for urgent MRI of spine for early diagnosis and treatment to minimise morbidity.

SSEH accounts for 40-50% of all reported cases of spinal epidural hematoma.<sup>10</sup> About 25-30% are associated with the use of anticoagulants.<sup>11</sup> Other causes include coagulopathies resulting from blood dyscrasias, such as leukemia and hemophilia, arterio-venous malformations and epidural hemangiomas.<sup>12,13,14</sup> Other rare causes include toxic infectious states and whooping cough.<sup>15</sup> Hematoma is frequently found in the cervico-thoracic and thoraco-lumbar junction, which are the sites of least resistance in the normal curved spine.<sup>16</sup>

Our patient had grossly deranged liver function tests and obvious laboratory evidence of coagulopathy at the time of onset of quadriplegia. In view of the supportive imaging evidence and positive serology for hepatitis A, final diagnosis of coagulopathy induced spontaneous spinal epidural hematoma as a complication of viral hepatitis A was made. Surprisingly, no other bleeding manifestations were noted during hospital stay. In addition to supportive care and management of complications of viral hepatitis A, prophylactic measures include community level education about good hygiene, clean water supplies and avoidance of raw shellfish or uncooked food. Immunization for the high risk group should also be encouraged.

## Conclusion

Spinal epidural hematoma should be considered in the differential diagnosis of acute onset quadriplegia. Patients with viral hepatitis and fulminant hepatic failure should be closely monitored for the development of neurological complications especially when coagulopathy is obvious. High index of clinical suspicion coupled with judicious utilization of imaging modalities including magnetic resonance imaging helps in appropriate management and reduction of

morbidity.

## References

1. Lemon SM. Type A viral hepatitis: new developments in an old disease. *N Engl J Med* 1985;313:1059-1067.
2. Keeffe EB. Is hepatitis A more severe in patients with chronic hepatitis B and other chronic liver diseases? *Am J Gastroenterol* 1995;90:201-20.
3. Johannes H, Michael PM MPM: Immune response to hepatitis A and E viruses. *Liver Immunol* 2007;163-177.
4. Groen RJM, van Alphen HAM: Operative treatment of spontaneous spinal epidural haematomas: a study of factors determining postoperative outcome. *Neurosurgery* 39:494-509, 1996
5. Kweon SM, Jin BH, Kim YS : Spontaneous spinal epidural hematoma mimicking lumbar disc herniation. *J Korean Neurosurg Soc* 28:713-719, 1999.
6. Lonjon MM, Paquis P, Chanalet S, Grelhier P: Nontraumatic spine epidural hematoma: report of 4 cases and review of the literature. *Neurosurgery* 41: 483-486, 1997
7. Bruyn GW, Bosma NJ. Spinal extradural hematoma. In: Vinken PJ, Bruyn GW, eds. *Handbook of clinical neurology*. In: Vol. 26, Injuries to spine and spinal cord. Amsterdam, Holland: North Holland Publishing, 1976:1-30.
8. Tewari MK, Tripathi LN, Mathuriya SN, Khandelwal N, Kak VK. Spontaneous spinal extradural hematoma in children. *Childs Nerv Syst* 1992;8:53-5.
9. Patel H, Garg BP. Increasing irritability with sudden onset of flaccid weakness. *Semin Pediatr Neurol* 1996;3:192-7.
10. Penar PL, Fischer DK, Goodrich I, Bloomgarden GM, Robinson F. Spontaneous spinal epidural hematoma. *Int Surg* 1987;72:218-21.
11. Zucarello M, Scanarini M, D'Avella D, Andrioli GC, Gerosa M. Spontaneous spinal extradural hematoma during anticoagulant therapy. *Surg Neurol* 1980;14:411-3.
12. Hamre MR, Haller JS. Intraspinal hematomas in hemophilia. *Am J Pediatr Hematol Oncol* 1992;14:166-9.
13. Muhonen MG, Piper JG, Moore SA, Menezes AH. Cervical epidural hematoma secondary to an extradural vascular malformation in an infant: Case report. *Neurosurgery* 1995;36:585-8.
14. Spill HWT, Tijssen CC. Spinal epidural hematoma due to a vertebro-epidural hemangioma. *Clin Neurol Neurosurg* 1989;91:91-3.
15. Jackson FE. Spontaneous spinal epidural hematoma coincident with whooping cough, case report. *J Neurosurg* 1963;20:715-7.
16. Groen RJM, Ponsen H. The spontaneous spinal epidural hematoma. A study of the etiology. *J Neurol Sci* 98:121-138, 1990

## Instructions to Authors

Submission to the journal must comply with the Guidelines for Authors.  
Non-compliant submission will be returned to the author for correction.

To access the online submission system and for the most up-to-date version of the Guide for Authors please visit:

<http://www.rfppl.co.in>

Technical problems or general questions on publishing with **IJEM** are supported by Red Flower Publication Pvt. Ltd.'s Author Support team ([http://rfppl.co.in/article\\_submission\\_system.php?mid=5#](http://rfppl.co.in/article_submission_system.php?mid=5#))

Alternatively, please contact the Journal's Editorial Office for further assistance.

Editorial Manager  
Red Flower Publication Pvt. Ltd.  
48/41-42, DSIDC, Pocket-II  
Mayur Vihar Phase-I  
Delhi - 110 091(India)  
Mobile: 9821671871, Phone: 91-11-22754205, 79695648, 22756995  
E-mail: [author@rfppl.co.in](mailto:author@rfppl.co.in)