

Original Research Article

A Throwback on Hemangioblastomas with a Special Reference to Von Hippel-Lindau Syndrome A Rarity

Nivetha S¹, Rama K², Devanand Senthilkumar³, Bharanidharan M⁴

¹Post Graduate, ²Professor, Department of Neuropathology, ³Professor, ⁴Post graduate, Department of Neurosurgery, Institute of Neurosurgery/ Neurology, RGGGH/ Madras Medical College, Chennai 605003, Tamil Nadu, India.

Corresponding Author:

Rama K, Professor, Department of Neuropathology, Institute of Neurosurgery/ Neurology, RGGGH/ Madras Medical College, Chennai 605003, Tamil Nadu, India.

E-mail: snrani93@gmail.com

Received on 16.01.2020

Accepted on 15.02.2020

Abstract

Background: Hemangioblastomas are benign vascular tumors with large majority of them arising within the cerebellum and produce the neurologic manifestations. They can appear either sporadically or due to an association with von Hippel-Lindau (VHL) disease. This study was done with the aim of knowing the current spectrum of incidence, varied locations, age and gender distribution in hemangioblastomas and their association with von-Hippel-Lindau (VHL) disease. **Methods:** A 5 year retrospective study was conducted in the Department of Neuropathology, Institute of Neurosurgery from January 2014 to December 2018 and histopathologically confirmed cases of Hemangioblastomas were compiled. **Results:** A total of 20 cases of hemangioblastomas were identified during the study, all of which were histopathologically confirmed. Among them 18 were intracranial and 2 were spinal hemangioblastoma. The most common age group affected in sporadic cases were 41-50 years (7 cases) and in VHL associated case was 11-20 years (1 case). Cerebellar location was the commonest seen in 13 cases (65%), followed by medullary, cerebellopontine angle, parieto occipital and cervical spine in decreasing order of frequency. Male predominance was seen unlike previous studies. **Conclusion:** The current spectrum of cases of hemangioblastomas with respect to incidence, various locations encountered, age and gender distribution were seen. The nature of presentation of paediatric hemangioblastomas is different, genetic heterogenicity and association with VHL has to be ruled out. Histological subtyping of the hemangioblastomas is necessary, after ruling out the differentials. Proper follow-up of the cases of hemangioblastomas are needed to look for recurrence.

Keywords: Hemangioblastomas; Cerebellar location; Von Hippel-Lindau disease.

How to cite this article:

Nivetha S, Rama K, Devanand Senthilkumar, et al. A Throwback on Hemangioblastomas with a Special Reference to Von Hippel-Lindau Syndrome A Rarity. Indian J Pathol Res Pract. 2020;9(1 Part II):171-176.

Introduction

Hemangioblastomas are benign vascular neoplasms that belongs to WHO grade I constituting roughly

2% of intracranial neoplasms and 2 to 10% of primary spinal cord neoplasms.¹ It frequently arises below the tentorium, predominantly in the cerebellar hemispheres (upto 76%), near

brainstem or along the spinal cord.^{2,3} They can appear either sporadically (57-75%) or due to an association with von Hippel-Lindau (VHL) disease (20-43%).³ Von Hippel-Lindau (VHL) syndrome is a rare autosomal dominant condition caused by deletion or point mutations in a tumor suppressor gene. Those who inherit a mutated gene are at greatly increased risk for retinal hemangioblastoma; cerebellar hemangioblastoma; pheochromocytoma; pancreatic and renal cysts; spinal hemangioblastoma; renal cell carcinoma; hemangiomas of adrenal liver and lungs; endolymphatic sac tumors and papillary cystadenoma of epididymis or broad ligament.⁴⁻⁶ Up to 50% of patients in VHL families show only one manifestation of the syndrome.^{7,8}

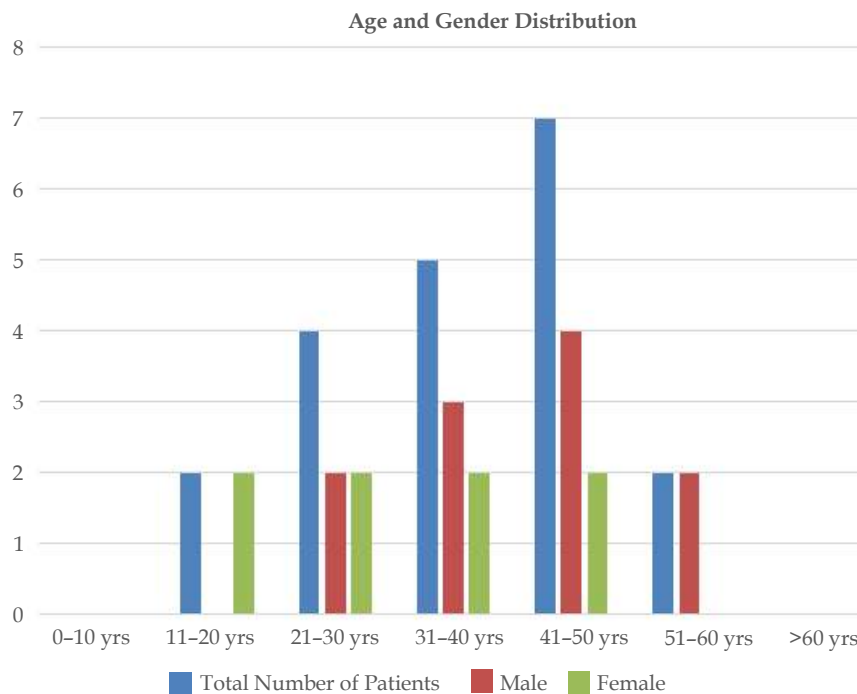
Materials and Methods

A 5 year retrospective study was conducted in the Department of Neuropathology, Institute of

Neurosurgery from January 2014 to December 2018 and histopathologically confirmed cases of Hemangioblastomas were compiled. Clinical details of the cases were retrieved from medical records.

Results

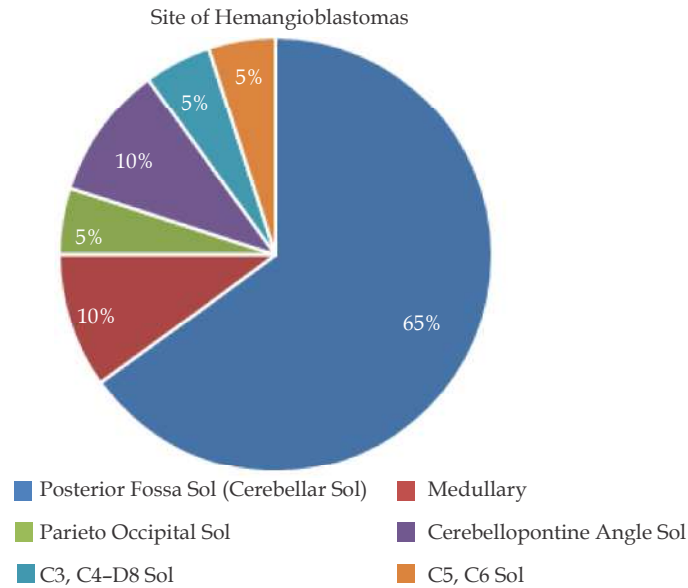
A total of 20 cases of hemangioblastoma were identified during the study all of which were histopathologically confirmed. All were single lesions. The commonest age group affected is between 41 to 50 years: 7 cases (35%), followed by 31 to 40 years: 5 cases (25%), whereas in hemangioblastomas associated with VHL syndrome the age group affected is between 11 to 20 years (1 case). The youngest age documented is 13 years which was associated with VHL and the eldest age documented is 55 years. Male to female ratio of 1.5:1, Males were predominantly affected compared to females (Graph 1).



Graph 1: Age and Gender distribution in hemangioblastoma.

Among the 20 cases, 18 cases (90%) were intracranial and 2 cases (10%) were spinal hemangioblastomas. The various locations of the

intracranial hemangioblastomas as per MRI are depicted in (Graph 2) with cerebellum being the commonest location.



Graph 2: Site of Hemangioblastomas in our study population.

Paediatric Hemangioblastoma an Association with VHL to Think about

A 13 year old female presented with complaints of left sided headache for 2 months. Headache was gradually progressive in nature associated with vomiting. Family history revealed that her mother was operated twice for bilateral cerebellar hemangioblastoma in 2001 and 2008 respectively and was diagnosed to be a case of Von Hippel-Lindau syndrome. Her maternal aunt and grandmother were also having cerebellar hemangioblastoma. Her physical examination was normal. Cerebellar functions were intact. Her blood investigations were normal.

Investigations: Contrast enhanced MRI of brain was done and it showed a well defined T2 hyper, FLAIR suppressed 5*3.6*3.3cm cystic lesion with intensely enhancing T2 hypointense mural nodule of 1.2*1 cm in left cerebellum with the possibility of left cerebellar hemangioblastoma with obstructive

hydrocephalus [Fig. 1]. Clinically patient was diagnosed to have cerebellar hemangioblastoma. Right ventriculoperitoneal shunt was kept during admission.

Procedure Done: Left suboccipitalcraniectomy and excision of mural nodule and evacuation of the cyst was done. Per operatively the cerebellum was bulging, pulsatile and straw colour cyst fluid with bluish grey mural nodule within the cyst wall was seen. The tissue was received and fixed in 10% buffered formalin.

Histopathological Examination: It showed portion of brain parenchyma with an adjacent neoplasm composed of numerous blood vessels of varying sizes [Fig. 2]. Intervening stromal cells are oval to spindle with hyperchromatic nuclei and scant to moderate eosinophilic to foamy cytoplasm. Extensive areas of haemorrhage and focal necrosis were also seen. A diagnosis of cerebellar hemangioblastoma was made.

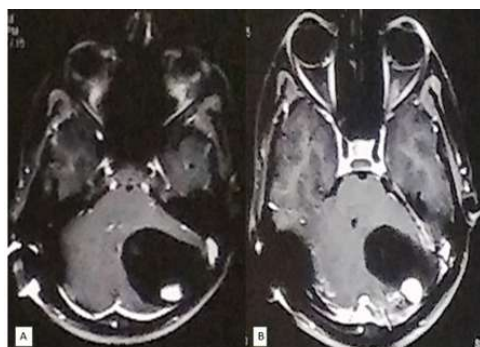


Fig. 1: (A) & (B) Contrast enhanced MRI shows a cystic lesion with intensely enhancing mural nodule in left cerebellum.

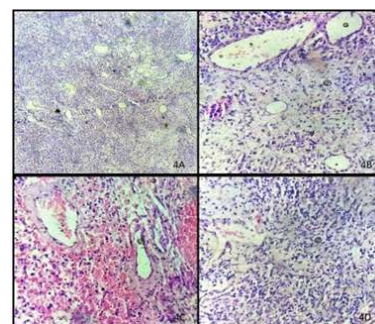


Fig. 2: A) Cerebellar hemangioblastoma (H & E * 10) composed of numerous blood vessels of varying sizes. 2B), 2C) and 2D) Stromal cells seen between the vascular arcades (H & E * 40).

Discussion

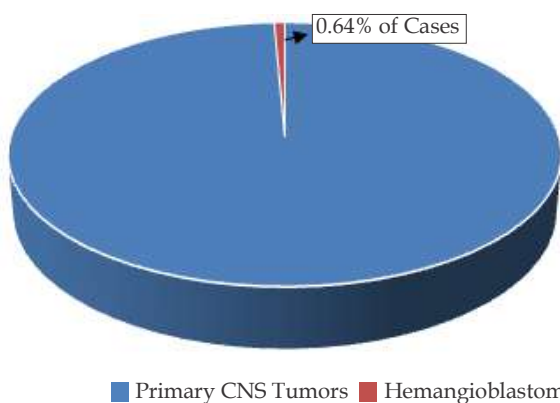
The incidence of hemangioblastomas among the primary intracranial tumors in our study is 0.64%, which is lower than the incidence observed in national and international data as per review of literature.⁹⁻¹² Among the primary spinal tumors the incidence of hemangioblastomas observed in our study is 2.6%, which is corresponding with the incidence observed in literature.¹³⁻¹⁵ (Graph 3, Graph 4) Most common location of hemangioblastomas in our study is cerebellum (65%), followed by medullary (brainstem), cerebellopontine angle, cervical spine and parieto occipital region. The incidence in sporadic cases

is increasing with age and peaks at 41–50 years which is earlier compared to the SEER based analysis¹⁶ and in case associated with VHL the age of onset is much earlier between 10–20 years. The male to female ratio in our study is 1.5:1 (12 male cases and 8 female cases) which is corresponding with the observations made in literature.^{12,16} But in the literature, there are also studies that showed equal risk in male and female¹⁷ or moderate male preponderance.^{9,11,18} In our study there is striking male predominance.

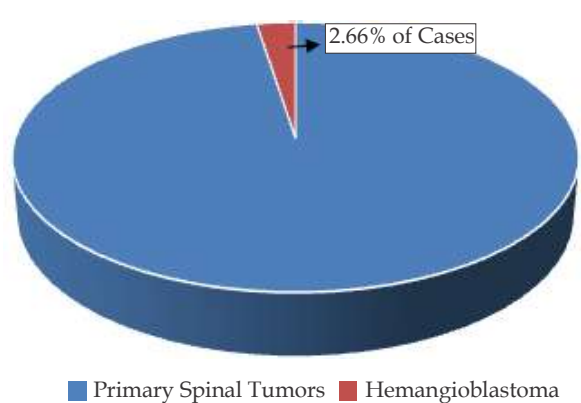
During our observation we found only one case of paediatric hemangioblastoma and it was associated with VHL. Hence paediatric hemangioblastomas constituted 5% of our study population.

Table 1: Parameters Compared

Parameters Compared	Conway JE et al.	Chawhan SM et al.	Our Study
1. Incidence (Intracranial Hemangioblastomas)	-	1.62%	0.64%
2. Location	-	Cerebellum (82%)	Cerebellum (65%)
3. Male To Female Ratio	1.11:1	1.75:1	1.5:1
4. Sporadic Cases	62%	100%	95%
5. Syndromic Association	38%	Nil	5%
6. Histopathology Variant Commonly Encountered	-	Cellular Variant	Reticular Variant
7. Spinal Hemangioblastomas	25%	9%	2.6%



Graph 3: Incidence of hemangioblastomas among Primary CNS tumors.



Graph 4: Incidence of hemangioblastomas among Primary spinal tumors.

Differentials and Importance of Histological Subtypes¹⁹⁻²⁵

Among the histological subtypes of cellular and reticular variant, 18 cases (90%) in our study falls under the reticular variant and 2 cases

(10%) were mixed subtypes. The importance of histological subtyping is that, in literature it was found to correlate positively with the probability of haemangioblastoma recurrence, with a 25% recurrence rate in cellular subtype and an 8% recurrence rate in reticular subtype.²⁶

Treatment for hemangioblastoma is mainly surgical excision. Stereotactic radiosurgery for hemangioblastomas results in a high local control rate in CNS HBs with acceptable levels of radiation-induced complications.²⁷ Principally, stereotactic radiosurgery can be used for surgically inaccessible or multiple cranial and spinal tumors.²⁸

VHL patients with CNS HBs should undergo MRI of the brain and spinal cord at least once

a year. VHL patients above 10 years old, who do not display CNS HBs, should undergo MRI screening of their whole neuro-axis every two years. An annual ophthalmoscopy should be performed to screen for retinal HBs. A yearly MRI of the abdomen is recommended to screen for renal cell carcinoma, pancreatic lesions, and pheochromocytoma.^{29,30}

Table 2: Variant

Variant	Differential Diagnosis	Histological Feature	IHC
1. Cellular	Secondary deposits of clear cell carcinoma of the kidney	Atypia, mitosis and necrosis seen in metastatic clear cell renal cell carcinoma is lacking in hemangioblastomas.	Cytokeratin, Vimentin and Epithelial membrane antigen (EMA) is positive in renal cell carcinoma and is absent in hemangioblastomas.
2. Reticular	Hemangiopericytoma	Cells of hemangiopericytomas are homogenous with abundant cytoplasm, oval nuclei, small nucleoli and moderate pleomorphism with characteristic staghorn vascular pattern lined by flat endothelial cells; the cells tend to bulge into the vascular lumina without bursting through endothelium.	Stromal cells are positive for S100 and Neural specific enolase (NSE) which distinguishes hemangioblastomas from hemangiopericytomas and angiomas.
3. Cellular	Lipidized angiomatous meningioma	Angiomatous meningioma have thick walled hyalinised vessels and will show sheets of meningothelial cells at places.	Stromal cells fail to express EMA distinguishing hemangioblastomas from Lipidized angiomatous meningioma.

Conclusion

The current spectrum of hemangioblastoma is that apart from presenting as a cerebellar lesion it can also present in brainstem, cerebellopontine angle, cervical spine, extradural and parieto occipital region. It had much earlier presentation when associated with VHL, hence any hemangioblastomas encountered in paediatric age group mandates a workup to rule out other manifestations of VHL syndrome. Patient counselling plays a vital role as the disease is inherited in an autosomal dominant pattern. Hence with proper follow-up of patients and screening of the other family members in the setting of VHL can reduce the morbidity and mortality. Histologically classifying the subtype is important in terms of recurrence as said in literature. Hence proper diagnosis keeping in mind the current spectrum of cases, ruling out the differentials and subtyping of the hemangioblastomas is necessary for management and follow-up of the patients.

References

- Pan J, Jabarkheel R, Huang Y, et al. Stereotactic radiosurgery for central nervous system hemangioblastoma: Systematic review and meta-analysis. *J Neurooncol* 2018;137:11-22.
- Tang Z, Wang C, Shi J. A solitary hemangioblastoma located on the trochlear nerve. *J Clin Neurosci* 2014;21:333-35.
- Kuharic M, Jankovic D, Splavski B, et al. Hemangioblastomas of the Posterior Cranial fossa in Adults: Demographics, Clinical, Morphologic, Pathologic, Surgical Features and Outcomes. A Systematic Review. *World Neurosurg* 2018;110:e1049-62.
- Maher ER, Iselius L, Yates JR, et al. Von Hippel-Lindau disease: A genetic study. *J Med Genet* 1991;28:443-7.
- Linehan WM, Lerman MI, Zbar B. Identification of the von Hippel-Lindau (VHL) gene: its role in renal cancer. *JAMA* 1995;273:564-70.
- Maher ER, Kaelin G Jr., Von Hippel-Lindau

- disease [Reviews in molecular medicine]. *Medicine (Baltimore)* 1997;76:381-91.
7. Neumann HPH, Wiestler OD. Clustering of features of von Hippel-Lindau syndrome: Evidence for a complex genetic locus. *Lancet* 1991;337:1052-4.
 8. Maher ER, Yates JRW, Harries R, et al. Clinical features and natural history of von Hippel-Lindau disease. *Q J Med* 1990;77:1151-63.
 9. Conway JE, Chou D, Clatterbuck RE, et al. Hemangioblastomas of the central nervous system in von Hippel-Lindau syndrome and sporadic disease. *Neurosurgery* 2001;48:55-62.
 10. Tarantino R, Isidori A, Raco A, et al. Supratentorial hemangioblastoma in a patient with breast cancer. A case report. *J Neurosurg Sci* 2000;44:137-9.
 11. Iplikcioglu AC, Yaradanakul V, Trakya U. Supratentorial haemangioblastoma: A ppearances on MR imaging. *Br J Neurosurg* 1997;11:576-8.
 12. Chawhan SM, Dani AA, Meshram SA, et al. Central nervous system hemangioblastomas: Epidemiology, pathology and clinical spectrum in a tertiary care centre. *Astrocyte* 2014;1:186-9.
 13. Hurth M. [Intraspinal hemangioblastomas]. *Neurochirurgie*. 1975;21(Suppl 1):1-136.
 14. Murota T, Symon L. Surgical management of hemangioblastoma of the spinal cord: A report of 18 cases. *Neurosurgery*. 1989;25(5):699-07.
 15. Yasargil MG, Antic J, Laciga R, et al. The microsurgical removal of intramedullary spinal hemangioblastomas. Report of 12 cases and a review of the literature. *Surg Neurol* 1976;3:141-48.
 16. Nguyen HS, Doan NB, Gelsomino M, et al. (2018) Intracranial hemangioblastoma: A SEER-based analysis 2004-2013. *Oncotarget* 9:28009-28015.
 17. Rosenblum MK, Bilbao JM, Cyn-Ang L. Neuromuscular system. In: Rosai & Ackerman's *Surgical Pathology*. 9th ed. India: Mosby Publication, Thomson Press (India) Ltd 2004:2587-9.
 18. Berger PC, Scheithauer BW. Tumors of the central nervous system. *Atlas of Tumor Pathology. Series 3, Fascicle 10. Tumors of Uncertain Origin. Ch. 7.* Washington DC: Armed Forces Institute of Pathology 1994:239-43.
 19. Commins DL, Hinton DR. Cytologic features of hemangioblastoma: Comparison with meningioma, anaplastic astrocytoma and renal cell carcinoma. *Acta Cytol* 1998;42:1104-10.
 20. Bret P, Streichenberger N, Guyotat J. Metastasis of renal carcinoma to a cerebellar hemangioblastoma in a patient with von Hippel Lindau disease: A case report. *Br J Neurosurg* 1999;13:413-6.
 21. Hussein MR. Central nervous system capillary haemangioblastoma: The pathologist's viewpoint. *Int J ExpPathol* 2007;88:311-24. doi: 10.1111/j.1365-2613.2007.00535.x.
 22. Hamazaki S, Nakashima H, Matsumoto K, et al. Metastasis of renal cell carcinoma to central nervous system hemangioblastoma in two patients with von Hippel-Lindau disease. *Pathol. Int* 2001;51:948-53.
 23. Becker I, Paulus W, Roggendorf W. Histogenesis of stromal cells in cerebellar hemangioblastomas. An immunohistochemical study. *Am J Pathol* 1989;134:271-5.
 24. Rubinstein LJ. *Atlas of Tumor Pathology: Tumors of the Central Nervous System.* Washington, DC: US Government Printing Office 1972:235.
 25. Hufnagel TJ, Kim JH, True LD, et al. Immunohistochemistry of capillary hemangioblastoma. Immunoperoxidase-labeled antibody staining resolves the differential diagnosis with metastatic renal cell carcinoma, but does not explain the histogenesis of the capillary hemangioblastoma. *Am J Surg Pathol* 1989;13:207-16.
 26. Hasselblatt M, Jeibmann A, Gerss J, et al. Cellular and reticular variants of haemangioblastoma revisited: A clinicopathologic study of 88 cases. *Neuropathol. Appl. Neurobiol* 2005;31:618-22.
 27. Asthagiri AR, Mehta GU, Zach L, et al. *Neuro Oncol* 2010;12(1):80-86.
 28. Moss JM, Choi CY, Adler JR, et al. Stereotactic radiosurgical treatment of cranial and spinal hemangioblastomas. *Neurosurgery* 2009;65(1):79-85.
 29. Lonser RR, Glenn GM, Walther M, et al. Von Hippel-Lindau disease. *Lancet* 2003;361(9374):2059-67.
 30. Krüger MT, Klingler JH, Steiert C, et al. Current diagnostic and therapeutic strategies in treatment of CNS hemangioblastomas in patients with VHL. *J Trans Med Epidemiol* 2014;2(1):1016.

