

A Rare Case of Rapunzel Syndrome with Double Impaction of Trichobezoar

Farhanul Huda, Deepak Sah

*Assistant Professor, Department Of Surgery, Teerthanker Mahaveer Medical College & Research Centre, Bagarpur, Moradabad (U.P.)- 244001

**Assistant Professor, Department Of Surgery, Teerthanker Mahaveer Medical College & Research Centre, Bagarpur, Moradabad (U.P.)- 244001

Abstract

Bezoars are foreign bodies in the lumen of the digestive tract. If a foreign body comprises of hair, it is known as Trichobezoar. Rapunzel syndrome is an uncommon presentation of trichobezoar in which the swallowed hairs extend as a tail through the small intestine, beyond the stomach. Till now, cases of isolated bezoars in the bowel and those of Rapunzel syndrome have been reported but in the present case, there was double impaction of trichobezoar, one in the stomach and another in the ileum, which has rarely been reported in the literature.

Keywords: Trichobezoar; Terminal ileum; Rapunzel syndrome.

Introduction

Bezoars are foreign bodies in the lumen of the digestive tract. If a foreign body comprises of hair, it is known as Trichobezoar. Human hair is resistant to digestion as well as peristalsis due to its smooth surface. Therefore it accumulates between the mucosal folds of the stomach. Over a period of time, continuous ingestion of hair leads to the impaction of hair together with mucus and food, causing the formation of a trichobezoar. In most cases the trichobezoar is confined within the stomach.

In some cases, however, the trichobezoar extends through the pylorus into jejunum,

ileum or even colon. This condition, called Rapunzel syndrome, was first described by Vaughan *et al* in 1968.[1,2] In addition, incidentally, parts of the tail can break off and migrate to the small intestine, causing intestinal obstruction.[3-5] Trichobezoar usually occurs in young females with Trichotillomania, which is a psychiatric disorder characterised by recurrent hair pulling and its subsequent chewing and swallowing (Trichophagia), in almost half of the patients. Bezoars may be made up of vegetable fibres (Phytobezoar), or masses of drugs (Pharmacobezoar).[6] We hereby report a rare case of Rapunzel syndrome with another trichobezoar impacting in the terminal ileum.

Case Report

A 13 year old female presented to the surgery outpatient department with complaints of pain in upper abdomen, weight loss and infrequent episodes of vomiting, especially after taking meals since 10 months. She was treated in different health centers as a case of recurrent gastroenteritis and parasitic infestation. On examination the patient was alert, malnourished and pale. Abdominal palpation revealed an elongated well defined mobile mass of approximately 10 x 8 cm palpable in the epigastrium. Patient had a history of trichotillomania and trichophagia since early childhood though she quitted this

Corresponding Author: Dr. Farhanul Huda, C/o Dr. S Huda, 783/1 Zaidi Nagar Society, Meerut U.P 250001

E-mail: farhanul1973huda@gmail.com

Figure 1A: Gastric Trichobezoar

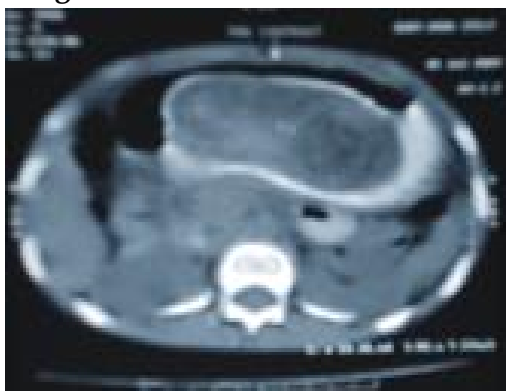

Figure 1B: Trichobezoar in Ileum

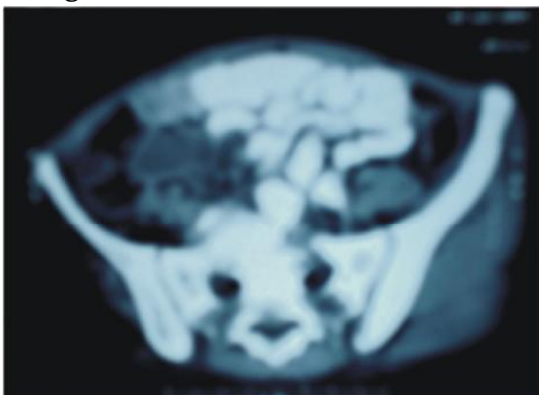


Figure 2A: Gastric Trichobezoar with Tail

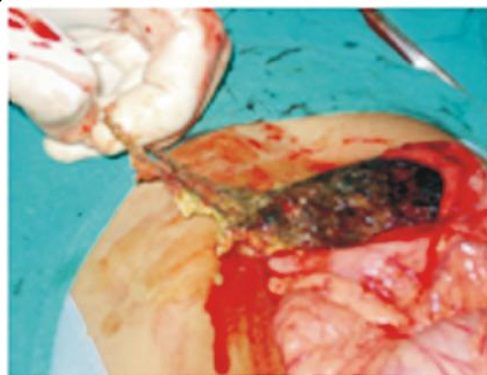
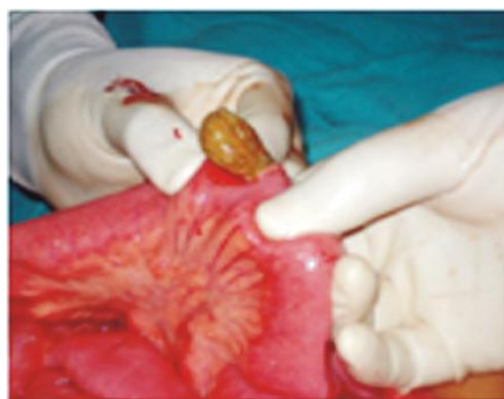
Figure 2B: Ileal Trichobezoar being Removed



habit 2 years back.

Sonographic report of abdomen showed a mass of 54x25 mm in the cavity of stomach.

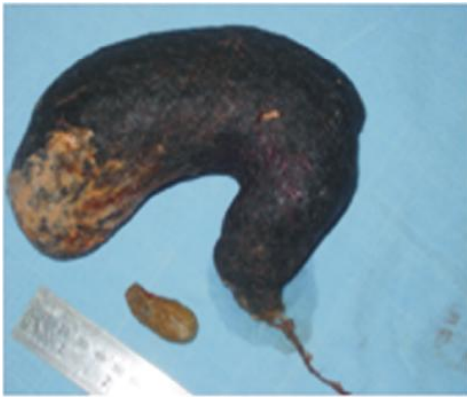A contrast CT scan of abdomen performed to determine the extent of mass revealed a 135 x 60 mm, non-enhancing lesion in stomach and a similar lesion of 37 x 21 mm size, impacted in the terminal small bowel [Fig 1]. An upper GI endoscopy was also performed which revealed a large trichobezoar, occupying whole of the stomach.

An exploratory laparotomy was performed via midline skin incision. Anterior Gastrotomy was done and a large trichobezoar, with its tail extending till the duodenojejunal junction was removed and gastrotomy closed in two layers. The distal trichobezoar was removed by an enterotomy performed approximately one foot proximal to the ileocaecal junction [Fig 2]. The resected specimen sizes were sent for histopathological evaluation. The post operative course remained uneventful. The patient was also consulted with a psychiatrist who following two sessions declared that at

present the patient is having no psychiatric ailment. The patient was discharged on 7th post-operative day in good health.

Discussion

A bezoar, (badzehr, Arabic, meaning antidote) is a mass of undigested material (usually hair or fibre) in the gastrointestinal tract. Trichobezoar, from the Greek word trich, meaning hair is the most commonly encountered bezoar. Hairs are nonabsorbable and indigestible and also due to their slippery nature they remain stuck in the folds of the gastric mucosa. This bunch of hair can have extension through the pylorus into the distal bowel, the so called Rapunzel Syndrome, which was described by Vaughan et al in 1968.[1] Incidentally parts of the tail can break off and migrate into the small intestine.[3-5] However, the presence of discrete gastric and intestinal trichobezoars,

Figure 3: Both Specimens

as in our case, has been rarely presented in the literature. Trichobezoars commonly occur in adolescent females with a preceding history of trichotillomania (pulling of hairs) and trichophagia (hair swallowing). Trichophagia occurs in up to 18% of patients with trichotillomania, and one-third patients with trichophagia develop trichobezoar.[7-9] Although the exact cause of trichotillomania is not clear but certain theories are proposed which say that psychosocial, behavioural and biological factors lead to this condition.[10,11] Majority of the cases of trichobezoar present late due to low index of suspicion. Of 131 reported cases of trichobezoar, a palpable mass was found in 87.7%, abdominal pain in 70.2%, nausea and vomiting in 64.9%, weakness, weight loss in 38.1%, constipation and/or diarrhea in 32% and haematemesis in 6.1%.[12]

The complications range from gastric mucosal erosion, ulceration, gastric outlet obstruction, intussusceptions, obstructive jaundice, protein losing enteropathy, pancreatitis, perforation peritonitis, intestinal obstruction and death.[13-17]

Ultrasound shows a mass in the stomach. Computed tomography (CT) best describes its size, extent, configuration and differentiates trichobezoars from neoplasms. The drawback is that sometimes, CT cannot differentiate small bowel faeces from trichobezoars. Endoscopy is diagnostic, which reveals a large ball of hair in the stomach. The most common diagnostic tool used in the literature is the CT scan with typical image showing a well defined intraluminal ovoid heterogeneous mass with

interspersed gas.[2].

Management options include endoscopic removal, laparoscopy or laparotomy. Other newer methods include laser ignited mini explosive techniques. Gorter *et al* in a retrospective review of 108 cases of trichobezoar, evaluated the available management options. It was noted endoscopic removal was successful in 5%, laparoscopy in 75% and laparotomy in 100% patients.[18]

Conclusion

Trichobezoars should be considered in the differential diagnosis in adolescent female patients presenting with nonspecific gastrointestinal infections and infestations or a palpable epigastric mass. We recommend that CT scan should be done routinely in all the patients with gastric trichobezoar to rule out any synchronous presence of small intestinal trichobezoar. Further, the importance of a clinical evaluation of the small bowel at the time of removal of a gastric bezoar is emphasised.

References

1. Vaughan ED Jr, Sawyers JL, Scott HW Jr. The Rapunzelsyndrome. An unusual complication of intestinal bezoar. *Surgery*. 1968; 63: 339-343.
2. Palanivelu C, Rangarajan M, Senthilkumar R, Madankumar MV. Trichobezoars in the stomach and ileum and their laparoscopy-assisted removal: a bizarre case. *Singapore Med J*. 2007; 48: 37-39.
3. Khattak S, Kamal A. Trichobezoar. *Gomal J Med Sci*. 2004; 2: 25-26.
4. Hoover K, Piotrowski J, Pierre K, Katz A, Goldstein AM. Simultaneous gastric and small intestinal trichobezoars – a hairy problem. *J Pediatr Surg*. 2006; 41: 1495-1497.
5. Samad A, Ahmad M, and Latif Z. Bezoars: a review and report of two cases. *Journal of the College of Physicians and Surgeons Pakistan*. 1997; 7(6): 263-265.

6. Rabie ME, Arishi AR, Khan A, Ageely H, El-Nasr GAS, and Fagihi M. Rapunzel syndrome: the unsuspected culprit. *World Journal of Gastroenterology*. 2008; 14(7): 1141-1143.
7. American Psychiatric Association. *Diagnostic and Statistical Manual of Mental Disorders*. 4th edition. Washington, DC, USA: American Psychiatric Association; 2000.
8. Christenson G.A and Crow S.J, "The characterization and treatment of Trichotillomania," *Journal of Clinical Psychiatry*, vol. 57, no. 8, pp. 42-49, 1996.
9. Bouwer C and Stein DJ. Trichobezoars in trichotillomania: case report and literature overview. *Psychosomatic Medicine*. 1998; 60(5): 658-660.
10. Salaam K, Carr J, Grewal H, Sholevar E, Baron D. Casereport untreated trichotillomania and trichophagia: surgical emergency in a teenage girl. *Psychosomatics*. 2005; 46: 362-6.
11. Topness E. What Are the Causes of Trichotillomania? [Internet] ehow available online at http://www.ew.com/about_5104343_causestrichotillomania.html Accessed on 19.1. 2011.
12. Naik S, Gupta V, Rangole A, Chaudhary AK, Jain P, Sharma AK. Rapunzel syndrome reviewed and redefined. *Dig Surg*. 2007; 24: 157-161.
13. Ventura DE, Mardiros FA, Schettini ST, and Delmonte C. Rapunzel syndrome with a fatal outcome in an neglected child. *Journal of Pediatric Surgery*. 2005; 40(10) 1665-1667.
14. Mehta MH and Patel RV. Intussusception and intestinal perforations caused by multiple trichobezoars. *Journal of Pediatric Surgery*. 1992; 27(9): 1234-1235.
15. Schreiber H and Filston HC. Obstructive jaundice due to gastric trichobezoar. *Journal of Pediatric Surgery*. 1976; 11(1): 103-104.
16. Hossenbocus A and Colin Jones DG. Trichobezoar, gastric polyposis, protein losing enteropathy and steatorrhea. *Gut*. 1973; 14(9): 730-732.
17. Shawis RN and Doig CM. Gastric trichobezoar associated with transient pancreatitis. *Archives of Disease in Childhood*. 1984; 59(10): 994-995.
18. Gorter RR, Kneepkens CMF, Mattens ECJL, Aronson DC, and Heij HA. Management of trichobezoar: casereport and literature review. *Pediatric Surgery International*. 2010; 26(5): 457-463.

Red Flower Publication Pvt. Ltd,

CAPTURE YOUR MARKET

For advertising in this journal

Please contact:

International print and online display advertising sales

E-mail: redflowerppl@vsnl.net / tel: +91 11 22754205, 45796900

Recruitment and Classified Advertising

E-mail: redflowerppl@vsnl.net / tel: +91 11 22754205, 45796900