

## Post Caesarian Intestinal Obstruction Due to a Retained Artery Forceps

Manohar L. Dawan

Associate Professor, Dept. of Surgery, S.P.Medical College, Bikaner.

### Abstract

Surgical instruments and materials continue to be retained in the peritoneal cavity despite precautionary measures. Even though uncommon it is also under-reported and carries serious medico-legal consequences. Gauzes and sponges are the most commonly retained materials and intra-abdominal retained artery forceps are much rarer but when they do occur lead to chronic abdominal pain and can be a rare cause of intestinal obstruction or strangulation with significant morbidity and mortality. The retained large artery forceps during a caesarian delivery is never reported before in literature searched.

**Keywords:** Retained Intra-Abdominal Artery Forceps; Post Caesarian Intestinal Obstruction.

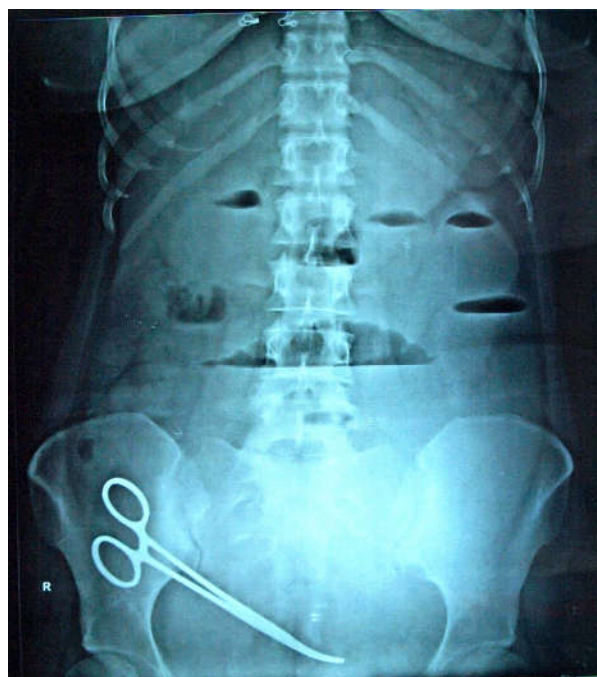
### Introduction

Intestinal obstruction due to forgotten surgical instrument in the abdomen is a surgical complication. Due to medico-legal implications these cases are rarely reported. This happens presumably because of inadequate surgical ethics in the operating room, among the scrub nurses and the operating surgeons. A case of acute intestinal obstruction with retained artery forceps presented after 18 days of caesarian surgery.

### Case History

A 28 year young multiparous woman was referred from medicine ward to our surgical emergency unit

with features of acute intestinal obstruction. The Patient's complains were abdominal pain, distention and recurrent vomiting after an emergency caesarian delivery 18 days back, not relived by medications. The vitals were stable all blood investigations were in normal limit except some electrolytes imbalance. On examination patient was dehydrated, abdomen severely distended with palpable bowel loops and metallic sound. A low midline scar of recent caesarian surgery with a pfannenstiell scar of previous caesarian surgery done 2 year back was present. The patient had history of two deliveries by caesarian surgery at around two year's interval by same gynecologist at a private hospital. The plain abdominal x-ray was showing multiple air-fluid levels with an artery forceps in-situ (Figure 1). Patient was prepared for emergency



**Fig. 1:** Plain abdominal x-ray showing artery forceps in-situ with multiple air-fluid levels

**Corresponding Author:** Manohar L. Dawan, Associate Professor, Dept. of Surgery, S.P.Medical College, Bikaner, Rajasthan 334001.

E-mail: [drmanohar\\_dawan1234@yahoo.com](mailto:drmanohar_dawan1234@yahoo.com)

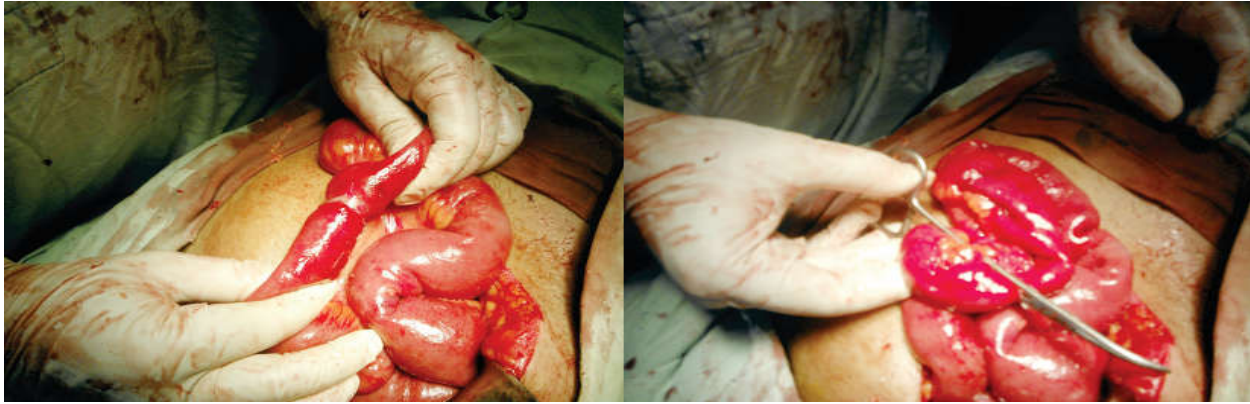


Fig. 2: Showing Ileal loop within gap of artery forceps.

exploration after primary resuscitation, CRTS, Intra venous fluid, broad spectrum antibiotics, ant-acids, electrolytes and analgesics. On exploration by a mid-line incision, stomach and small gut found massively dilated up to one feet proximal to the ileo-caecal junction with mild adhesions and with few amount of reactionary fluid. The artery forceps found in right iliac fossa holding end of a corner suture of uterine scar of caesarian with ileal loop double folded and locked in between the gap of lock and two limbs of forceps (Figure 2). The artery forceps's lock opened and removed from abdominal cavity, locked ileal loop released. The ileal loop was healthy with normal peristaltic movements were present on stimulation, obstruction was relived. A prophylactic drain was put in pelvis and closure done. The post operative recovery was uneventful, abdominal drain and Ryle's tube were removed on 2<sup>nd</sup> post-operative day and orally allowed on 3<sup>rd</sup> post-operative day. The patient's bowel habit becomes normal and stitches removed on 8<sup>th</sup> post operative day and discharged. Patient is in regular follow-up and healthy.

### Discussion

The small intestinal mechanical obstruction accounts for about 80 percent of all cases of mechanical obstructions. The case presented was caused by retained artery forceps during previous Caesarian operation.

The incidence of retained intra-operative foreign body is increasing so increasing the morbidity and mortality of patient. According to literature searched the complications due to retained foreign body after intra abdominal surgery are adhesion obstruction, perforation, sepsis and death may occur. The retention of sponges and instruments are avoidable mistakes but when it occurs may jeopardize the professional life of the surgeon [1]. According to

literature searched the exact incidence of retained foreign body is yet not determined but estimated incidence may be around one in every 1000 to 1500 cases. The possible risk factors identified in literature were a change in nursing staff during surgery, uses of inexperienced and untrained nursing staff without supervision. Others are excessive blood loss, incomplete count of sponges and instruments, fatigue of surgical team due to prolonged period of procedure and in emergency surgery [2]. In our patient relative risk factor was emergency caesarian delivery. A case of retained large artery forceps following Caesarian delivery is never reported before in world literature searched.

### Summery

This case stresses the long time recommendations of counting and documenting sponges and instruments before and after surgery. The authors recommend early abdominal x-ray and ultrasound in post surgical cases with complains of pain and vomiting not relived by medications. This may reduce the morbidity and mortality due to late detection of such things, but will not prevent the embarrassment and medico-legal problems to the surgeon, the scrub nurses and the hospital.

### References

1. Fadiora SO, Olatoke SA, Bello To, Adeoti ML, Agodirin SO. Intestinal obstruction from a forgotten artery forceps: a case report. *West Afr J of Med.* 2004; 23(4): 330-331.
2. Ugochukwu AI, Edeh AJ. Retained intra-abdominal artery forceps - An unusual cause of intestinal strangulation. *N Am J Med Sci.* 2011; 3(7): 339-343.