

Surgical Outcome of Free Flap Surgery in a Tertiary Referral Center in Maharashtra

Apurva Nayan Samant¹, Sagar Gundewar², Yogesh Jaiswal³, Rajat Kapoor⁴

How to cite this article:

Apurva Nayan Samant, Sagar Gundewar, Yogesh Jaiswal, *et al.*/Surgical Outcome of Free Flap Surgery in a Tertiary Referral Center in Maharashtra/New Indian J Surg. 2023; 14(3):133-138.

Abstract

Introduction: Reconstruction with a free flap is routinely done at site especially head and neck and oral because of better surgical and functional outcomes, improved esthetics results, and overall higher success rates.

Aim & Objective: To evaluate the clinical outcomes in patients undergoing different microvascular free flap reconstructions and study various demographic and pre-operative factors associated with it.

Methods: This was a retrospective study of 45 patients undergoing reconstructions with free flaps from January 2020 to December 2022. Different types of free flap were performed like Anterolateral thigh, Free fibula osteocutaneous flap (FFOCF), free functioning muscle transfer (FFMT), Free radial artery forearm flap (FRAF), The medial sural artery perforator (MSAP), latissimus dorsi (LD), myocutaneous flap, superficial circumflex iliac artery perforator (SCIP).

Results: The patients included total 45 participants, with 35 men and 10 women, with a mean age of 45.56 years. Oral malignancy was the most common cause. Squamous cell carcinoma represented the majority of the diagnosed tumors (31.1%) followed by ameloblastoma. The most common recipient vessels were the internal jugular vein (91.4%), the facial artery (77.4%) followed by superior thyroid artery. The overall flap success rate was 93.33%. Venous thrombosis was the most common cause for re-exploration. The majority of patients had satisfactory cosmetic and functional results of both donor site and recipient site on 1 month follow up.

Conclusion: Microsurgical free flap seems to be a valuable and successful method in head and neck surgery. The reconstruction can be done by skilled surgeons with post-op monitoring.

Keywords: Free flap; Venous thrombosis.

Author Affiliation: ¹Final Year Resident, ^{2,4}Assistant Professor, Senior Consultant, ³Consultant, Department of Plastic Surgery, Grant Medical College & Sir J.J. Group of Hospitals, Mumbai 400008, Maharashtra, India.

Corresponding Author: Apurva Nayan Samant, Final Year Resident, Department of Plastic Surgery, Grant Medical College & Sir J.J. Group of Hospitals, Mumbai 400008, Maharashtra, India.

Email: dr.samant1313@gmail.com

Received on 27-06-2023

Accepted on 08-08-2023

INTRODUCTION

Surgery for tumors of head and neck and in slower limbs due to trauma results in significant soft tissue, bony and skin defects. This may result in cosmetic and impairment in speech and swallowing. Also, the reconstruction of extensive defects after resection has constantly been challenging due to risk factors, fibrosis, site and

trauma. The free flap technique brought revolution in more complex reconstructive procedures. Different free tissue flaps, such as Latissimus Dorsi (LD) flap, Radial Forearm (RF) flap, scapula flap, Anterolateral Thigh (ALT) flap, Jejunum flap, and Rectus Abdominis muscle (RA) flap had been used in the reconstruction of tumor defects of head and neck region. The ALT flap has a large and long vascular pedicle and is widely useful in soft tissue reconstruction. Pectoralis Major Myocutaneous (PMMC) flap was important due to its simple technical aspects and flexibility but was too large and so there were cosmetic problems. The RF flap was used in China before 2007 and is a fasciocutaneous flap. Though useful and feasible, it had a high rate of donor site morbidity. The Free fibula osteocutaneous flap (FFOCF) provided an ideal reconstructive option. The aim of this study was to present results or outcomes seen with different free flaps for head and neck defects used, and to analyze the pre-operative factors associated with outcomes.

METHODOLOGY

A retrospective analysis was conducted in 45 consecutive patients undergoing microsurgical reconstructions, in Grant government medical college hospital between January 2020 and December 2022. Various demographic, clinicopathologic features and surgical data were included. The medical records details of the primary tumor site, flap type, vessels from the donor site and at the recipient site, and complications seen were analyzed. All subjects gave their informed consent for the study, and the protocol was approved by our institutional ethics board.

Patients were given pre-operative care which included incentives, pirometry, hydration and protein supplementation.

The one team of experienced plastic surgeons performed tumor resections with or without neck dissections depending on the nodal status. The other team present was responsible for reconstruction of the defects, including flap harvesting, and vascular anastomosis. After the surgery, flap monitoring was performed every hourly during the first 48 hrs, then every 4 hourly for the next three days. The patients were followed-up clinically for surgical outcome. Diet was assessed by the patient's dietary intake and was classified as taking a normal diet, a soft diet, and a liquid diet. If uneventful all patients were discharged on 10th day. During

the follow-up after 1 month the cosmetic results were evaluated by clinical examination and the patient's own observation. Compliance was 100%. All data was entered first in Microsoft excel coded and analysis was performed by SPSS version 25. Percentages or proportions for qualitative data and mean and standard deviation for quantitative data was calculated. A $p < 0.05$ value was considered statistically significant.

RESULTS

Mean age was 45.56 years (+/-16.363)

There were 35 (77.8%) males and 10 (22.2%) females in our study.

Oral malignancy seen in 31.1%, trauma in 24.4% ameloblastoma in 20%, panbrachial plexus injury in 13.3%, mucormycosis in 6.7%, basosquamous carcinoma in 2.2%, arteriovenous malformation in 2.2% patients.

Mean duration of surgery was 11.02 hours (+/-2.398)

Different types of free flaps were performed. Anterolateral thigh in 37.8%, Free fibula osteocutaneous flap (FFOCF) in 35.6%, free-functioning muscle transfer (FFMT) in 13.3%, Free radial artery forearm flap (FRAF) in 4.4%, latissimus dorsi (LD) in 4.4%, The medial sural artery perforator (MSAP) and superficial circumflex iliac artery perforator (SCIP) in 2.2% each respectively.

Majority of the patients were extubated on day 1.

All patients of head neck reconstruction were given RT feeding others continued oral diet. from day 1.

Here 3 patients i.e. 6.7% patients required emergency surgical re-exploration, 3(6.7%) patients had minor infection and 2 (4.4%) patients had surgical dehiscence that was managed conservatively while only 3 patients had complete taken down. Thus the total flap success rate was 93.33%. Venous thrombosis was the seen as most common cause for re-exploration. Other complications included wound infection for which debridement was done and fistula formation.

There were no significant differences found between the outcomes seen in terms of gender, age, duration of surgery, types of free flaps ($p > 0.05$). But there was significant association between preoperative patient built up, addiction to nicotine, surgery in zone of trauma. Our analysis also showed significant association between presence of

Table 1: Summary of variables and flap status at day 10

Variables	Healthy	Nonhealthy	P-value
Age in years			
</=30	10	1	0.92
31-40	8	1	
41-50	6	0	
51-60	8	1	
>60	8	2	
Gender			
Male	30	5	0.266
Female	10	0	
Comorbidities			
Yes	0	5	<0.01
No	40	0	
Cause			
Ameloblastoma	9	0	0.308
Avm	1	0	
Basosquamous carcinoma	1	0	
Face Trauma	1	0	
Lower Limb Trauma	6	0	
Mucormycosis	3	0	
Oral malignancy	11	3	
Pan brachial plexus	6	0	
Upper limb Trauma	2	2	
Flap			
ALT	14	3	0.174
FFOCF	15	1	
FFMT	6	0	
FRAF	2	0	
LD	2	0	
MSAP	0	1	
SCIP	1	0	
Duration in hours			
</=9	9	1	0.694
>9	31	4	
Addiction			
Alcohol	1	1	<0.01
Smoking	2	4	
nil	37	0	
Zone of trauma			
Arterial thrombosis	0	1	<0.01
Venous thrombosis	0	4	
nil	40	0	

diabetes in patient and increased risk of flap failure.

Table, Supplementary Digital Content 2. A table 1 that shows Summary of variables and flap status at

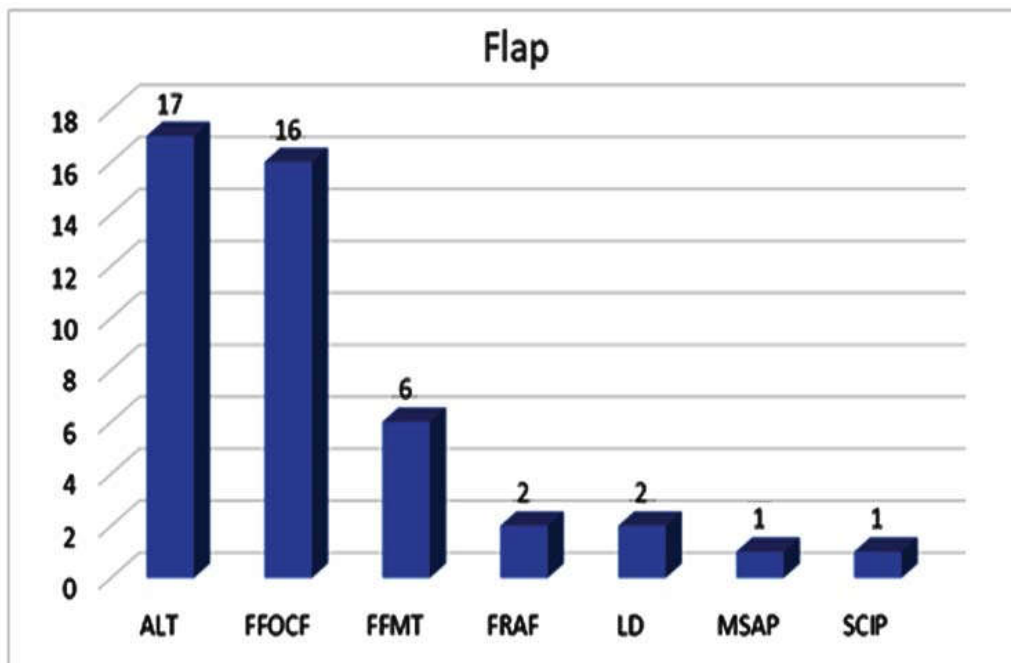


Fig. 1: A graph that shows Types of flap.

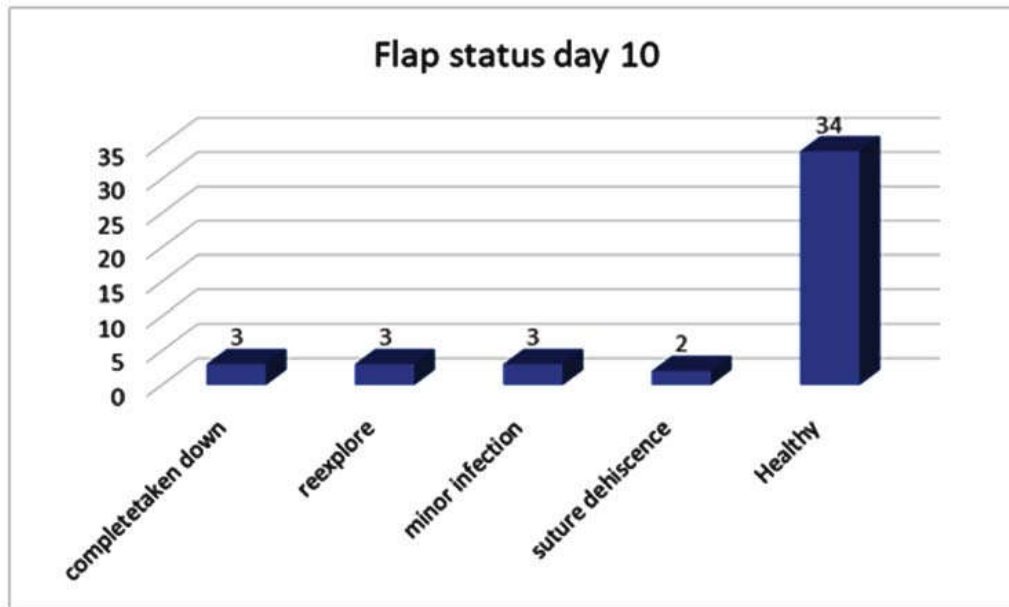


Fig. 2: A Graph that shows Flap status at day 10

day 10.

DISCUSSION

Free flap transplantation for soft tissue reconstruction has become the method of choice in defects of significant size and depth, seen with exposed vulnerable structures such as vessels, tendons, or bones and in patients with comorbidities. This single center study investigated patient demographics, patient characteristics, comorbidities and medication, perioperative details, microcirculation, and free flap outcome. In our study it was seen that age is not significantly associated with flap status.

In Jiwang Liang *et al* study it is seen that there is no significant difference seen between the outcomes and age.²

In Jiwang Liang *et al* study it is seen that no significant differences were seen with gender ($p > 0.05$), this finding is similar to our study. In Peirong Yu *et al* study it was seen that sex was a significant predictor of flap failure, with rates in women being twice as high as those in men. It was thought to be due to the overall very low failure rate and the inadequate study's statistical power.⁵ A literature search showed similar findings of failure.²

In our study significant association was seen between comorbidities and flap status. In Jiwang Liang *et al* study there is no association seen between presence of hypertension or diabetes and

increased risk of flap necrosis (p 0.549 and p 0.310 respectively).²

Plastic surgeons often evaluate free flap transfer according to revision rates, flap outcome, and flap failure. The free flap outcome has significantly increased over time, and has become a highly standardized, safe, and successful means of providing reconstruction of large sized defects in a extensive indications. Thus this free flap transfer is often challenging, as several comorbidities complicate the procedure and perioperative patient management.

In our study it is seen that oral malignancy is seen in 31.1%, trauma in 24.4% ameloblastoma in 20%, panbrachial plexus injury in 13.3%, mucormycosis in 6.7%, basosquamous carcinoma and arteriovenous malformation each in 2.2% patients.

In Jiwang Liang *et al* study it is seen that the histologic diagnosis of the tumors was squamous cell carcinoma (89.2%), adenoid cystic carcinoma (4.3%), adenocarcinoma (2.2%), basal cell carcinoma (1.1%), malignant melanoma (1.1%), mucoepidermoid carcinoma (1.1%), and malignant fibrous histiocytoma (1.1%).²

In our study it is seen that is seen that FFOCF flap have better result than ALT flap. ALT flap has more soft tissue that could reduce fibrosis. FFOCF flap is considered to be best for mandibular reconstruction and in our study oral cases were more In study by Prabha Yadav *et al* it is seen that majority of oral mandibular defects could be

reconstructed with free Fibula Osteo Cutaneous Flap (FFOCF), anterolateral thigh (ALT) flap and radial artery free flap.⁶

In our study venous thrombosis was more than arterial and it was significant associated with outcome.

Jiwang Liang *et al* study it was seen that venous thrombosis was more common than arterial thrombosis.²

Peirong Yu *et al* study shows that arterial thromboses behave differently from venous thromboses. Arterial thrombosis tends to occur early and is less likely to result in flap salvage.⁵ Also, post-operative arterial thrombosis is often associated with intra-operative arterial thrombosis due to technical difficulties such as artery size mismatch, calcified vessels, and technical errors.

In our study duration of surgery was not significantly associated with outcome of flap status on post-operative day 10 this is similar to study by Nicholas Moellhoff *et al* where duration of surgery did not significantly influence outcome in terms of patient survival.⁷ Nina Irawat *et al* study it is seen that duration of surgery equal to or more than 9 hours created a 92% increase in complications and it was statistically significant (p 0.009). Increased operative time was associated with increased length of stay and resurgeries, but not medical complication.⁸

In a study by Ishimaru *et al* a significant association between very long surgery times more than 18 hours and flap complications was found to be high.⁹

In our study, 3 i.e. 6.7% patients required emergency surgical re-exploration, 3 (6.7%) patients had minor infection and 2 (4.4%) patients had surgical dehiscence that was managed conservatively while only 3 patients had complete taken down. Thus the total flap success rate was 93.33% and venous thrombosis was more common. In study by Bui DT *et al* total of 1193 free flaps were performed during the study period, of which 6 percent required emergent reexploration. The most common causes for reexploration were pedicle thrombosis (53%) and hematoma/bleeding (30%). The overall flap survival rate was 98.8% and venous thrombosis was more common.¹⁰

CONCLUSION

Success rate of 95-98% in free flap reconstruction is achieved with proper skills and procedure. It is

possible to reconstruct most of defects in the head and neck region by using FFOC, radial artery forearm flap or ALT free flap If these 3 flaps are successfully performed, other flaps also can be performed with ease following same protocol and procedures. Therefore assessment of wound defect, selection of appropriate flap and along with surgical techniques for vascular anastomosis and skilled hands and proper monitoring from preoperative to post-operative stage is required.

REFERENCES

1. Alberto Grammatica^{1*}, Cesare Piazza², Raul Pellini³, Nausica Montalto, Davide Lancini, Alperen Vural¹, Francesco Barbara Free flaps for advanced oral cancer in the "Older Old" and "Oldest Old": A Retrospective Multi-Institutional Study Front. Oncol. Head and Neck Cancer 03 July 2019; Volume 9.
2. Jiwang Liang a, Tao Yu b, Xu Wang c, Yuejiao Zhao a, Fengqin Fang a, Wei Zeng Free tissue flaps in head and neck reconstruction Clinical application and analysis of 93 patients of a single institution Brazilian Journal of Otorhinolaryngology Volume 84, Issue 4, July–August 2018, Pages 416-425 Craft AB. Title with initial cap in Roman: Subtitle also with initial cap in Roman. Plast Reconstr Surg. 1997;100:111-115.
3. Chen KH, Kuo SCH, Chien PC, Hsieh HY, Hsieh CH. Comparison of the surgical outcomes of free flap reconstruction for primary and recurrent head and neck cancers: a case-controlled propensity score-matched study of 1,791 free flap reconstructions. Sci Rep. 2021 Jan 27;11(1):2350. doi: 10.1038/s41598-021-82034-5. PMID: 33504947; PMCID: PMC7840944.
4. Brian Somoano MD, Jeremy Kampp MD, Hayes B. Gladstone MD Accelerated takedown of the paramedian forehead flap at 1 week: Indications, technique, and improving patient quality of life Journal of the American Academy of Dermatology Volume 65, Issue 1, July 2011, Pages 97-105.
5. Yu P, Chang DW, Miller MJ, Reece G, Robb GL. Analysis of 49 cases of flap compromise in 1310 free flaps for head and neck reconstruction. Head Neck. 2009 Jan; 31(1):45-51. doi: 10.1002/hed.20927. PMID: 18972428.
6. Yadav PS, Shankhdhar VK, Dushyant J, Seetharaman SS, Rajendra G. Two in one: Double free flap from a single free fibula osteocutaneous unit. Indian J Plast Surg. 2012 Sep;45(3):459-65. doi: 10.4103/0970-0358.105942. PMID: 23450653; PMCID: PMC3580343.
7. Moellhoff, N.; Taha, S.; Wachtel, N.; Hirschmann, M.; Hellweg, M.; Giunta, R.E.; Ehrl, D. Analysis of Factors Determining Patient Survival

- after Receiving Free-Flap Reconstruction at a Single Center – A Retrospective Cohort Study. *Diagnostics* 2022, 12, 2877.
8. Nina Irawati, James Every, Rebecca Dawson, *et al.* Effect of operative time on complications associated with free flap reconstruction of the head and neck. Authorea. March 20, 2022.
 9. Ishimaru M, Ono S, Suzuki S, Matsui H, Fushimi K, Yasunaga H. Risk factors for free flap failure in 2,846 patients with head and neck cancer: a national database study in Japan. *J Oral Maxillofac Surg.* 2016;74(06):1265-127.
 10. Bui DT, Cordeiro PG, Hu QY, Disa JJ, Pusic A, Mehrara BJ. Free flap reexploration: indications, treatment, and outcomes in 1193 free flaps. *PlastReconstr Surg.* 2007 Jun; 119(7):2092-2100. doi: 10.1097/01.prs.0000260598.24376.e1. PMID: 17519706.
 11. Yadav P. Head and neck reconstruction. *Indian J Plast Surg.* 2013 May;46(2):275-82. doi: 10.4103/0970-0358.118604. PMID: 24501464; PMCID: PMC3901909.

