

## Role of Unilateral Guided Chest Expansion Technique after Decortications in Reversing Unilateral Atelectasis

Neha Bala<sup>1</sup>, Ravinder Narwal<sup>2</sup>, Anju Verma<sup>3</sup>

### How to cite this article:

Neha Bala, Ravinder Narwal, Anju Verma. Role of Unilateral Guided Chest Expansion Technique after Decortications in Reversing Unilateral Atelectasis. *Physiotherapy and Occupational Therapy Journal*. 2020;13(2):67-73.

### Abstract

**Background:** Decortication is a common surgical procedure done to free a part of fibrous capsule, formed around the lung, secondary to an inflammatory process. The risk of postoperative pulmonary atelectasis following Decortication is relatively high which is recorded at 90%. Therefore this case study has been designed to find out a better physiotherapy technique to reverse atelectasis in short period of time. **Methodology:** This case study was based on two sample subjects. Case I who received Unilateral guided chest expansion after decortication and Case II who did not received Unilateral guided chest expansion after decortication. **Outcome Variables:** Radiological and Auscultation findings collected and compared; and length of hospital stays were considered as outcome variables. **Result:** Unilateral guided chest expansion technique after decortication has much more significant effect in reversing atelectasis than Non-unilateral guided chest expansion technique after decortication. **Conclusion:** This case study has shown that Case I who received Unilateral guided chest expansion after decortication has better improvement than the Case II who did not received Unilateral guided chest expansion after decortication. Therefore this technique should be practiced in every unilateral atelectasis, especially after decortication.

**Keywords:** Decortications; Unilateral guided chest expansion; Chest X-ray.

### Introduction

Decortication refers to a fairly invasive surgical procedure done to free a part of fibrous capsule that has formed around the lung, secondary to an inflammatory process, such as an infection. The common indications for decortication are fibrothorax, chronic empyema, trapped lung, restrictive pleurisy and tuberculous Infection.

The main aim of decortications is to restore or to improve lung function and chest wall compliance; to allow the lung to expand to a greater capacity; to control infection as in empyema; to prevent deformity which almost always complicates the development and progression of fibrothorax; and to remove cancerous tissue and tumor in advanced stages of the illness.

It is well documented that in some postoperative cases, especially undergone thoracic surgery, patients have an increase risk of developing reduced respiratory function and pulmonary complications through atelectasis, secretion retention, altered chest wall mechanics and abnormal breathing pattern,<sup>1</sup> which is been recorded high at between 19% and 59%, compared with only 16% and 17% for upper abdominal surgery and 0% and 5% for lower abdominal surgery.<sup>2</sup>

The most common complication undergone pulmonary decortication is the pulmonary

---

**Author Affiliation:** <sup>1</sup>MPT, Department of Physiotherapy, C.P. & I.C, Utrakhand, <sup>2</sup>MPT Ortho and MPT Cardiopulmonary, Department of Physiotherapy, Bhagat Phool Singh Government Medical College, Khanpur Kalan, Haryana 131305, India, <sup>3</sup>MPT Cardiopulmonary, Lecturer, Prince Sattam Bin Abdul Aziz University, Alkharaj, KSA.

**Corresponding Author:** Ravinder Narwal, MPT Ortho and MPT Cardiopulmonary, Department of Physiotherapy, Bhagat Phool Singh Government Medical College, Khanpur Kalan, Haryana 131305, India.

**E-mail:** [ravinarwal@gmail.com](mailto:ravinarwal@gmail.com)

atelectasis, which is recorded at 90% and it remains so today.<sup>3-5</sup> This is because of regional hypoventilation which occurs in the dependent areas of the lung compressed through the effects of supine positioning with concurrent respiratory muscle paralysis<sup>6</sup> and positive pressure ventilation.<sup>7</sup> Similarly during decortications, which necessitate lateral positioning, the dependent lung is more vulnerable to the effects of compression and absorption, and up to double the resting lung volume (functional residual capacity) may be lost compared with that of the lung in a supine subject.<sup>8</sup> Preoperative medications, anesthetic agents, and drugs given in the intraoperative period may also lead to decrease lung compliance, which contributes to diminished lung volume and atelectasis.<sup>9</sup>

**Table 1:** A summary of postoperative pathophysiologic changes outlined by Tisi.<sup>10</sup>

Factors Measured	Changes			
<b>Lung Volume</b>	TLC	VC	ERV	RV
<b>In Thoracic surgery</b>	↓	↓	↓	↓
<b>Ventilatory Pattern</b>	TV	RR	Compliance	Sigh Mechanism
<b>In Thoracic surgery</b>	↓	↑	↓	↓

Where, TLC = total lung capacity; VC = vital capacity; ERV = expiratory reserve volume; RV = residual volume; TV = tidal volume and RR = respiratory rate.

Other factors that may contribute to atelectasis include supplemental oxygen delivered to a patient at low lung volumes.<sup>11</sup> In the immediate postoperative period, a combination of drowsiness, pain and analgesia may lead to a slow, monotonous, shallow breathing pattern,<sup>12</sup> recumbent positioning and decreased mobility, leading to further regional hypoventilation. Depth of respiration in thoracic surgery patients may also be impaired by chest wall incisions and insertion of intercostal chest drains. As the functional residual capacity decreases, tidal breathing occurs in the range of closing capacity, leading to further collapse of dependent airways. Unless these problems are reversed, atelectasis will progress in a self-perpetuating cycle. Therefore this case study has been designed to find out a better physiotherapy technique to reverse atelectasis in short period of time.

Other complications of decortications are pleural effusion and/or Pneumonia, transient hypoxemia, infections like peri-operative sepsis syndrome, bronchopleural fistulas, bleeding, and persistent air leak due to tearing of pleura. This inability of the lungs can cause severe breathing problems associated with chest pain, tightness, potentially leading to increasing length of hospital stay and can eventually lead to death if not addressed

immediately. Therefore pulmonary rehabilitation programme has to be started as early as possible after surgery.

Pulmonary rehabilitation is a nonpharmacological intervention aims to reverse atelectasis and secretion retention. It may include deep breathing exercises, positioning, airway clearance techniques and mobilization. Intermittent, deep, prolonged inspiratory efforts are thought to reinflate collapsed alveoli, increase pulmonary compliance and reduce regional ventilation-perfusion inequalities.<sup>13</sup> Therefore Incentive spirometry is most commonly used which involves deep breathing through a device with visual feedback, thought to maximize accuracy of breathing technique and motivation.<sup>14</sup>

Physiologic changes resulting from atelectasis include increased alveolar surface tension caused by deficient amounts of surfactant in the atelectatic area.<sup>15</sup> With persistent atelectasis and the subsequent decrease in surfactant, increased inspiratory pressures are needed to reinflate the atelectatic area.<sup>16</sup> It has also been documented that pulmonary rehabilitation represents a potentially useful intervention, especially if applied in a period less than one week after the surgery. And when it is performed by specialized therapists, the rates of pulmonary morbidity have been reported to improve from 15.5% to 4.7%.

Therefore through this study we want to see the effect of Unilateral guided chest expansion technique in subjects recovering recent thoracopulmonary surgery for pleural decortications. We also want to see how it differs from the effects of non unilateral guided chest expansion after decortications.

### Methodology

*Study design:* Experimental case study.

*Population:* Patients admitted in the CTVS ward of Himalayan hospital, Jollygrant, Dehradun.

*Sample size:* Two.

*Inclusion criteria:* Both male and female of age 35-40; underwent thoracotomy with intercostal drainage; pulmonary complications like atelectasis, pleural effusion and or hemothorax.

*Exclusion criteria:* Patients with cardiac implant, rib fracture and cardiac abnormalities.

*Instrumentation used:* Incentive spirometer, Stethoscope, Inch tape.

*Outcome variables:* Radiological and Auscultation findings collected and compared; and length of

hospital stay were considered as outcome variables.

*Independent Variables:* Unilateral Guided Chest Expansion technique.

*Dependent variables:* Radiological findings, Auscultation findings, and length of hospital stay.

#### Procedure

Two subjects meeting the inclusion criteria were recruited from CTVS ward of Himalayan hospital, Jollygrant. The purpose of the study was explained to them and an informed consent was obtained from both of them. Then the subjects were divided into two groups as case I and case II having 1 subject in each. Case I included a 40 yrs old male undergone post thoracotomy left lung atelectasis with same side pleural effusion. And Case II included a 38 yrs old female undergone post thoracotomy right lung atelectasis with same side pleural effusion.

In case I, patient had received Unilateral guided chest expansion technique (as shown in Fig. 1), in which the patient was asked to sit upright in a chair with back free of support and relax quietly for few minutes. Then the patient was provided with an incentive spirometer, holding in front at the level of the mouth and was asked to close his lips tightly around the mouthpiece and inhale as deeply as he can. The patient was then instructed to try to move the ball as high up as he can and hold breathe for 2 to 5 seconds. Meanwhile the therapist, who was standing at the side of the unaffected lung, placing both hands contralaterally over the anterior and posterior aspects of same side of the thorax, applied a forceful compression on contralateral sides of the thorax in order to shift the air from unaffected to the affected lung.

This technique was further followed by Incentive Spirometry that included total 5 sets of 10 repetitions each; 2 sets without Unilateral guided chest expansion technique, 3 sets with Unilateral guided chest expansion technique, and was practiced for duration of 5-10 minutes per set in every 3 hourly; Chest physiotherapy including percussion, vibration followed by huffing and coughing; Diaphragmatic breathing exercise including 1 set with 10-15 repetitions in every 2 hourly for duration of 5-8 minutes per set; Segmental Breathing including bilateral costal, apical and posterior basal expansion; Arm raising exercise including 1 set with 10-15 repetitions in every 2 hourly for duration of 5-8 minutes per set; and lastly Mobilization i.e., corridor walking within 100 meters.

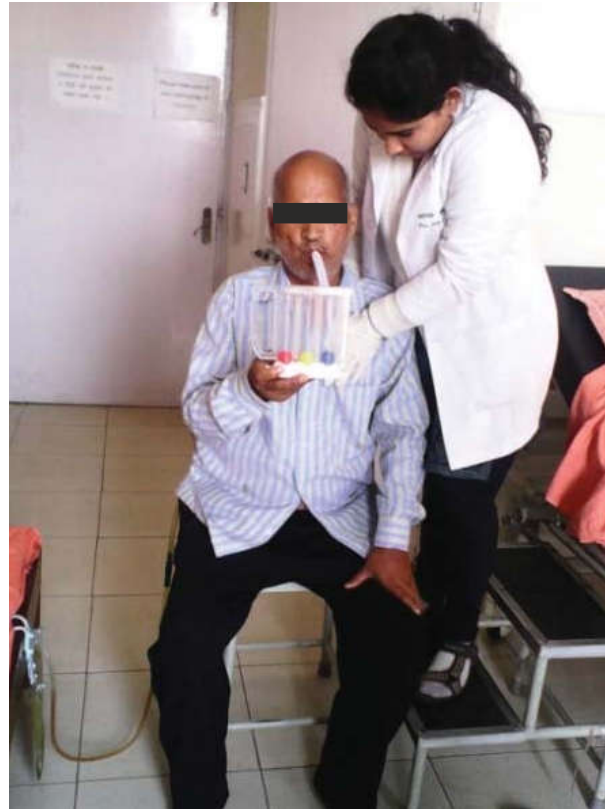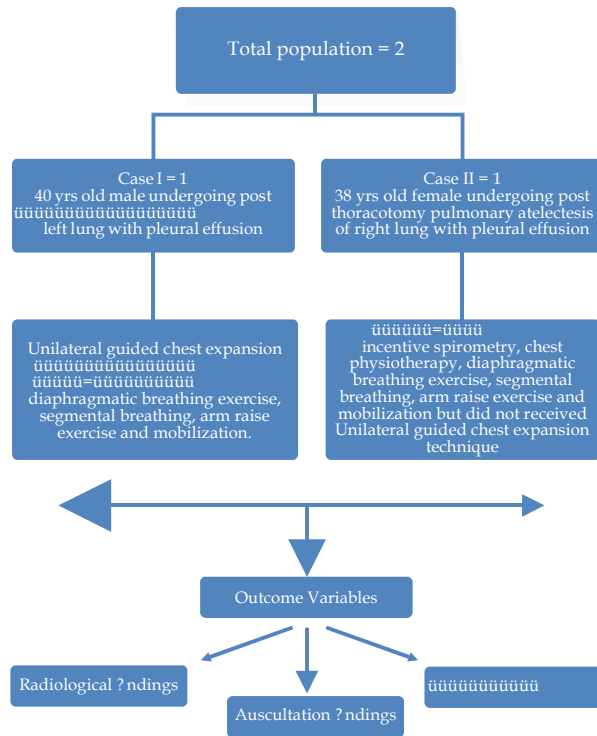


Fig. 1: Showing the patient with Unilateral guided chest expansion technique.

And in case II, patient had received the same protocol including Incentive spirometry, Chest physiotherapy, Diaphragmatic breathing exercise, Segmental Breathing exercise, Arm raising exercise and Mobilization but did not received unilateral guided chest expansion technique (Fig. 2).

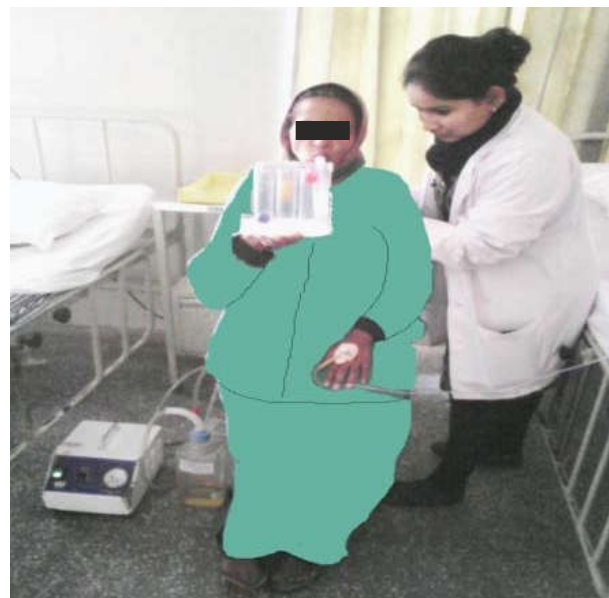

Fig. 2: Showing the patient without Unilateral guided chest expansion technique.



**Discussion**






In this study we demonstrated that Case I who received Unilateral guided chest expansion after decortication had a significant improvement than Case II who did not received Unilateral guided chest expansion after decortication.

In previous studies, some authors choose only one criterion i.e., radiography<sup>17</sup> as an outcome variable, others choose a combination of factors like radiography, temperature changes, breath sound changes, pulmonary function changes and length of hospital stay.<sup>18-20</sup> Similarly in this study, we took 3 variables which are radiography, breath sound changes and length of hospital stay.

*Radiological and Auscultation findings*






After comparing the radiological and auscultation findings of both case I and case II, we saw that Case I who received Unilateral guided chest expansion after decortication has shown an immediate and significant improvement in reversing atelectasis than Case II who did not received Unilateral guided chest expansion after decortications. The results are as follows:

**Table 2a:** Case I- 40 yrs/Male. Post-op Thoracotomy with Unilateral guided chest expansion.

	X-ray Findings-	Auscultation findings-
Day 1 	Lungs are mildly congested. Homogenous opacity is seen in lower zone of left lung.	Vesicular sound absent in left upper and lower lobes. Crackles are present all over the lung field.
Day 2 	Left Pleural effusion with underlying pulmonary atelectasis. Left Hemothorax. Left costophrenic angle obliterated	Vesicular sound diminished in left upper lobe; absent in left lower lobe. Crackles present all over the lung field.
Day 3 	Left Pleural effusion with underlying pulmonary atelectasis. ICD tube seen on left lung.	Vesicular sound present in left upper lobe; diminished in left lower lobe. Crackles present in left lower lobe.
Day 4 	Mild Pleural effusion of left lung. Underlying pulmonary atelectasis. ICD tube seen on left lung.	Vesicular sound present in all over the lung field. Crackles present in left lower lobe.
Day 5 	Clear left lung. Atelectasis reversed. ICD tube seen on left lung. Chest leads are seen in situ.	Vesicular sound present in all over the lung field. Crackles absent.

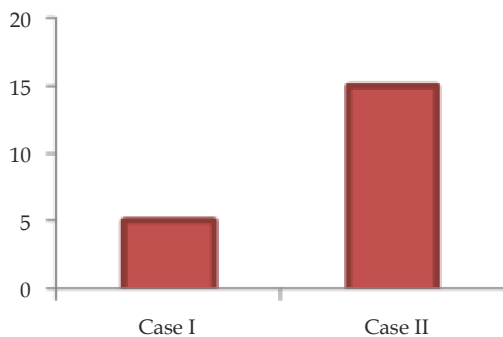


**Table 2b:** Case II- 38 yrs /female. Post-op Thoracotomy without Unilateral guided chest expansion.

	X-ray Findings	Auscultation findings
Day 1 	Right pulmonary atelectasis associated with right pleural effusion.	Vesicular sounds absent in right upper, middle and lower lobes associated with Crackles present all over the lung field. Transmitted sounds are present.
Day 3 	Right pulmonary atelectasis associated with right pleural effusion. Right costophrenic angle obliterated	Vesicular sound present in right upper lobe; diminished in right middle and lower lobes. Crackles present in right middle and lower lobes. Transmitted sounds absent.
Day 5 	Right pulmonary atelectasis. Mild pleural effusion of right lung. Right costophrenic angle obliterated ICD tube seen on right lung.	Vesicular sound present in right upper lobe; diminished in right middle and lower lobes. Crackles present in right middle and lower lobes only.
Day 10 	Right pulmonary atelectasis. Right Pleural effusion reversed. ICD tube seen on right side.	Vesicular sound present in right upper and middle lobe; diminished in right lower lobe. Crackles present in right lower lobe only.
Day 15 	Right lung field clear. Atelectasis reversed. ICD tube seen on right side.	Vesicular sound present in all over the lung field. Crackles absent.

*Length of hospital stay*

After comparing the radiological and auscultation findings of both case I and case II, we saw that Case I who received Unilateral guided chest expansion



**Fig. 3:** Showing the graph of length of hospital stay.

after decortications took only 5 days to reverse atelectasis completely whereas the Case II who did not received Unilateral guided chest expansion after decortications took 15 days to reverse atelectasis completely (Fig. 3).

On the other hand, we did a pilot study also. We selected a normal subject randomly from HIHT University, and his chest expansion measurements were taken with an inch tape at the level of nipples while performing incentive spirometer along with it. Then we applied unilateral guided chest expansion technique and again took the chest expansion measurements. Total three chest expansion measurements were taken- Bilateral chest expansion measurement without technique (Fig 4a), Unilateral chest expansion measurement without technique(Fig. 4b) and Unilateral chest expansion measurement with technique (Fig. 4c).

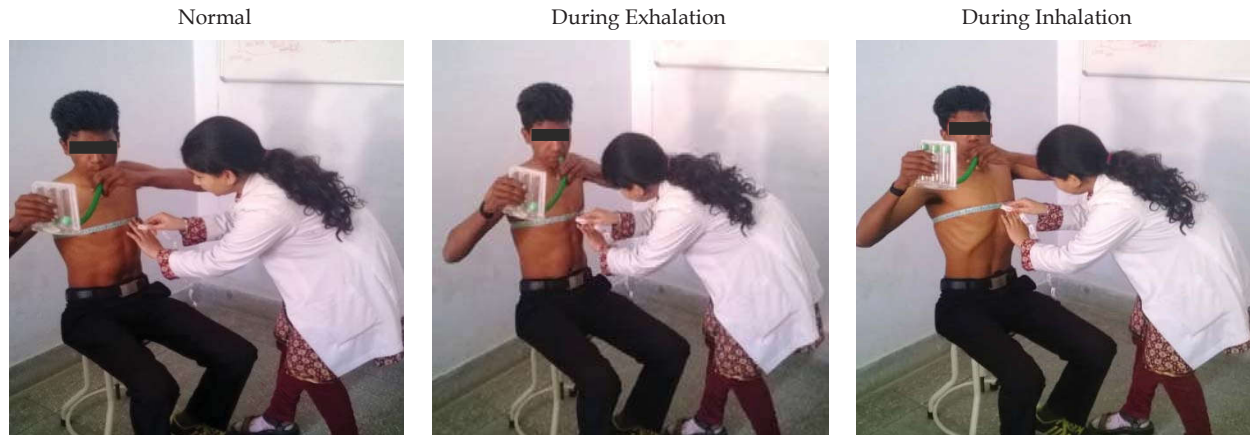

Fig. 4a: Showing Bilateral chest expansion measurement without technique.

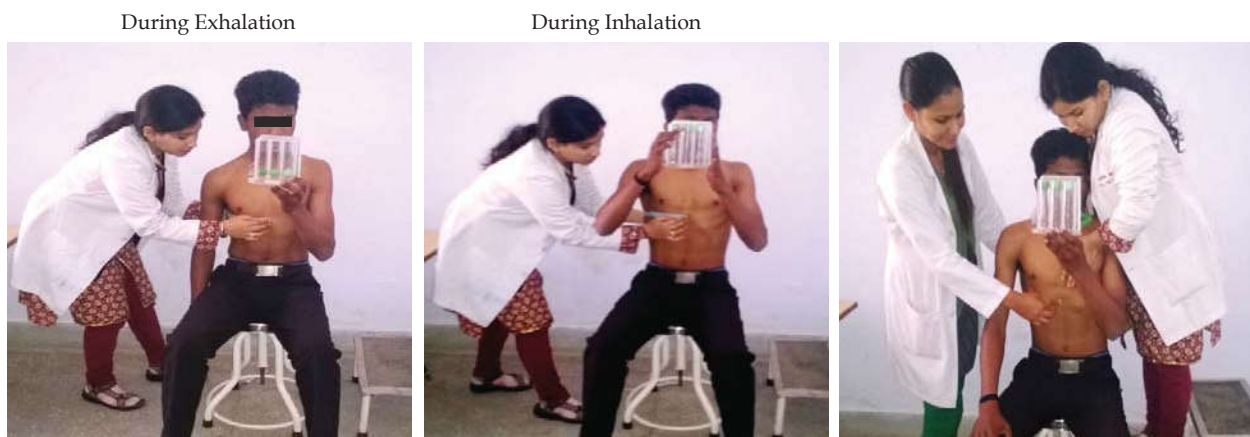


Fig. 4b: Showing Unilateral chest expansion measurement without technique.

Fig. 4c: Showing Unilateral chest expansion measurement with technique.

After collecting and comparing all the three results of chest measurements, we saw that there was a marked difference in the chest expansion before and after applying the unilateral guided chest expansion technique. Normally with bilateral chest expansion during exhalation and inhalation, the difference was of 5 cm only. With unilateral chest expansion without technique the difference was of 4 cm and with unilateral chest expansion with technique, the difference was of 6 cm. This 2 cm increase in the chest expansion after applying unilateral guided chest expansion technique shows that it has a significant effect in the inflation of collapsed alveoli and thus helps in reversing atelectasis. The results are as follows-

Table 3: Showing Chest expansion measurements in normal subject.

	Chest expansion measurements	During exhalation	During inhalation	Difference
1.	Bilateral without technique	69 cm	74 cm	5 cm
2.	Unilateral without technique	41 cm	45 cm	4 cm
3.	Unilateral with technique	41 cm	47 cm	6 cm

## Conclusion

This case study has shown that Case I who received Unilateral guided chest expansion after decortication has a significant effect in reversing atelectasis than Case II who did not received Unilateral guided chest expansion after decortication. Therefore this technique should be practiced in every unilateral atelectasis, especially after decortication.

### Limitation and Future study

This study is limited to small sample size and also there is lack of review of literatures related to unilateral guided chest expansion technique so this study can be extended in future by taking this technique to a large sample size and other possible surgeries and/or conditions causing unilateral lung atelectasis can be involved.

### Conflict of interest

There is no conflict reported amongst all the authors.

### Acknowledgement

I owe my greatest regards for the immense help and valuable guidance of my guide Dr. Ravinder Narwal, Lecturer at Physiotherapy Department, H.I.H.T. University, U.K., who helped and encouraged me throughout the period of my study and for all the time he spent on going through my study and making necessary corrections as and when required. I am also thankful to my parents, my juniors and seniors specially Dr. Shashi chouhan who provided their great support and encouragement in completion of this study.

### References

1. Lumb AB. Nunn's applied respiratory physiology. 6th ed. Oxford: Butterworth Heinemann; 2005.
2. Garcia-Miguel FJ, Serrano-Aguilar PG, Lopez-Bastida J. Preoperative assessment. *Lancet* 2003; 362:1749-59.
3. Schwartz SI, Shires GT, Spencer FC, et al: Principles of Surgery. New York, NY, McGraw-Hill, Inc. 1979, pp 495524.
4. Pasteur W: The Bradshaw lecture on massive collapse of the lung. *Lancet* 1351-1355, 1908.
5. Palmer KNV, Sellick BA: The prevention of post-operative pulmonary atelectasis. *Lancet* 1:164-168, 1953.
6. Brismar B, Hedenstierna G, Lundquist H. Pulmonary densities during anaesthesia with muscular relaxation—a proposal of atelectasis. *Anaesthesiology* 1985;62:422-8.
7. Froese AB, Bryan AC. Effects of anaesthesia in paralysis on diaphragmatic mechanics in man. *Anaesthesiology* 1974;41:242-54.
8. Klingstedt C, Hedenstierna G, Lundquist H, Strandberg A, Tokics L, Brismar B. The influence of body position in differential ventilation on lung dimensions in atelectasis formation in anesthetized man. *Acta Anaesthesiol Scand* 1990;34:315-22.
9. Rehder K, Sessler AD, Marsh HM: State of the art: General anesthesia and the lung. *Am Rev Respir Dis* 112:541-563, 1975.
10. Tisi GM: State of the art: Pre-operative evaluation of pulmonary function. *Am Rev Respir Dis* 119:293-310, 1979.
11. Nunn JF, Williams IP, Jones JG, et al: Detection and reversal of pulmonary absorption collapse. *BR J Anaesth* 50:91-99, 1978.
12. Zikria BA, Spencer JL, Kinner JM, Broell JR. Alterations in ventilator function in breathing patterns following surgical trauma. *Ann Surg* 1974;179:1-7.
13. Bakow ED. Sustained maximal inspiration—a rationale for its use. *Respir Care* 1977;22:379-82.
14. Bartlett RH, Gazzaniga AB, Geraghty TR. Respiratory manoeuvres to prevent postoperative pulmonary complications: a critical review. *JAMA* 1973;224:1017-21.
15. Wohl MEB: Atelectasis. *Phys Ther* 48(5):472-477, 1968.
16. Peters RM: The Mechanical Basis of Respiration: An Approach to Respiratory Pathophysiology. Boston, MA, Little, Brown & Co, 1969, pp 264-265.
17. Wiklander O, Norlin U: Effect of physiotherapy on postoperative pulmonary complications: A clinical and roentgenographs study of 200 cases. *Acta Chir Scand* 112:246-254, 1957.
18. Thoren L: Post-operative pulmonary complications: Observations on their prevention by means of physiotherapy. *Acta ChirScand* 107:193-205, 1954.
19. King DS: Post-operative pulmonary complications: A statistical study based on two years' personal observation. *Surg Gynecol Obstet* 56:43-50, 1933.
20. Browne DRG, Rochford J: The incidence of post-operative atelectasis in the dependent lung following thoracotomy: The value of added nitrogen. *Br J Anaesth* 42:340-346, 1970.