

Reattachment of Broken Crown Fragment: An Immediate Aesthetic Alternative; A Case Report

Neelam Mittal¹, Sakshi Gupta²

Author's Affiliation: ¹Professor, ²Junior III, Department of Conservative Dentistry and Endodontics, FODS, Banaras Hindu University, Varanasi 221005, Uttar Pradesh, India.

Corresponding Author: Sakshi Gupta, Junior III, Department of Conservative Dentistry and Endodontics, FODS, Banaras Hindu University, Varanasi 221005, Uttar Pradesh, India.

E-mail: sakshigupta250394gmail.com

How to cite this article:

Neelam Mittal, Sakshi Gupta/Reattachment of Broken Crown Fragment: An Immediate Aesthetic Alternative; A Case Report/*Indian J Dent Educ.* 2021;14(4): 119-121.

Abstract

Crown fractures of the anterior teeth are common in cases of trauma. In which 2-13% cases accounts for complicated Crown fractures. Severe pain is the main chief complaint in such patients because of the exposed pulpal tissue. Such patients require emergency care. Because of impaired aesthetics, pain and loss of function these patients are quite apprehensive amidst the treatment. The article here describes immediate management of a complicated horizontal crown fracture of maxillary right central incisor. Central incisor was treated with reattachment procedure using light transmitting fibre post. After 1 year follow-up, reattached fragment showed satisfactory healing, esthetics and function.

Keywords: Complicated crown Fracture; Reattachment; Dual cure resin cement.

Introduction

The Fracture of anterior teeth are very commonly seen in children and young adolescents. Most commonly results from falls and contact sports.^{1,2} The maxillary central incisors are most commonly injured because of their position in the arch.^{3,4} This leads to esthetic, functional, phonetic problems and disturb the social and psychological well being of a patient. It requires quick functional and esthetic repair. Treatment planning for a crown fracture depends on the level and position of tooth fracture, availability of tooth fragments type of occlusion and prognosis.

Traditionally a number of techniques have been applied for the treatment of fractured anterior teeth such as using the tooth fragment as a temporary or permanent crown, orthodontic and surgical extrusion or a crown lengthening followed by definitive crown, extraction followed

by implant, direct composite restorations and post core supported restorations.⁵ The Reattachment of tooth fragment using light transmitting fibre post, can be possible when the intact tooth fragment is available and this technique is a good alternative to conventional approach with minimal violation of biologic width.^{6,7} This article discusses the management of crown fracture of anterior tooth which was successfully treated using conservative manner by reattachment.

Case Report

A 28-years old male patient reported to the Department of Conservative Dentistry and Endodontics, faculty of Dental sciences, BHU, India with the chief complaint of crown fracture to the maxillary right central incisor. Intra oral examination revealed horizontal fracture line in the cervical margin of the tooth. (Fig. 1(a)). The

fractured fragment was attached to the crown but was grade II mobile. Radiographic examination revealed horizontal crown fracture of maxillary right central incisor with pulpal involvement (Fig. 2(a)). According to clinical and radiographic examination diagnosis of Ellis Class III fracture was confirmed, and treatment plan of reattachment of fractured segment using fiber post and dual cure resin was planned.

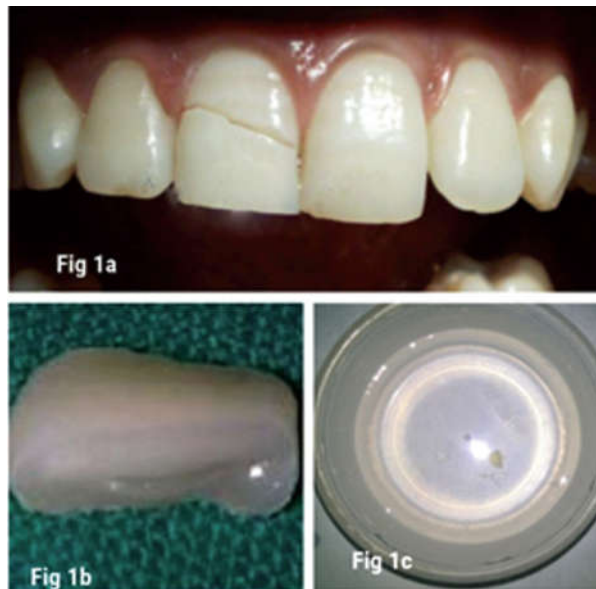

Fig. 1(a) Ellis class III # 11 Clinical picture, (b) Fractured fragment separated from tooth (c) Fractured segment stored in Normal Saline.

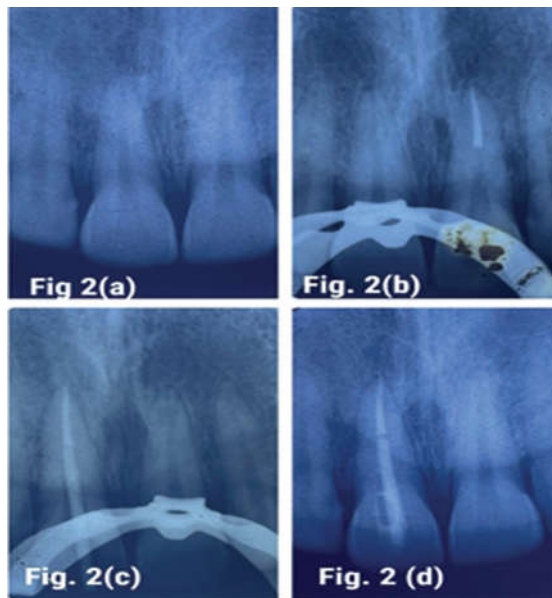


Fig. 2 (a) Preoperative IOPA showing Ellis Class III # 11, (b) Working length IOPA, (c) Segmental Obturation done in 11, (d) Fractured segment cemented using dual cure resin and light transmitting glass fiber post.

The fractured fragment of the maxillary right central incisor was attached to just 1 point, so it

was removed (Fig. 1(b)) and stored in normal saline (Fig. 1(c)) to be used at a later stage. Isolation was achieved using rubber dam, and saliva ejector placed in position. Root canal treatment was completed immediately using sectional technique, and the post space was prepared (Fig. 2(b)). A light-transmitting fiber post was tried in the canal and cut at the desired length (Fig. 2(c)). The fractured fragment was removed from the normal saline and tried on the cut end of the fiber post. Remnants of pulp tissue from the fractured fragment were removed during this step. Care was taken not to remove excess dentin, because it can alter the final esthetic appearance of the tooth. Once the desired fit was confirmed, it was stored in distilled water.

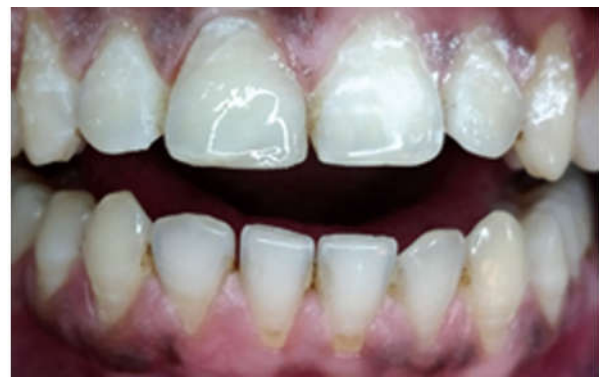

Fig. 3: Post operative clinical Photograph after cementation.

After acid etching of root canal with 37% phosphoric acid, dual-cure bonding agent was applied according to the manufacturer's instructions, and the post was cemented with the help of dual-cure resin cement. Any excess cement oozing out of canal was removed with cotton applicator tips. The post was then light cured for 40 s. Groove in the fractured fragment was filled with dual-cure resin cement, and the exposed fiber post was also luted with the same resin. The fragment was repositioned and cured for 40 s from palatal and labial surface. Labial fracture line was restored with Nanocomposite. Finishing and polishing was done using Shofu polishing system (Fig. 3). Patient was recalled after 3, 6, 9 and 12 months, which showed satisfactory healing, esthetics and function.

Discussion

Patients with fractured anterior teeth are apprehensive emotionally about their appearance.⁸ In such patients quick esthetic restoration to preserve function and esthetics in single appointment by preserving natural tooth structure may lead to positive impact on patient. The technique described in the present case report is simple, quick, and economic compared with other more invasive

procedures. Several case reports had explained the successful reattachment of uncomplicated tooth fracture cases.⁹ The present case report has shown that the fractured fragment can be used even if the fracture is complicated, but the margins are accessible. Isolation is the key to success in such cases, as in our case rubber dam was used.

Similarly, root fracture should also be treated as conservatively as possible, with every attempt made to restore vitality of tooth. According to Andreasen and Hjørting-Hansen¹⁰ there are 4 healing patterns, and preinjury and injury factors can affect the prognosis and tissue response to dental trauma.¹¹ The most desirable type of healing occurs when a calcified tissue callus forms around the fracture and the root is reunited.^{10,11}

Protection of mechanical, functional and esthetics is most important factors in restoring traumatized anterior teeth. If fractured fragment is available intact, the reattachment must be the most desired treatment.^{9,10} As it provides good esthetics and is very cost-effective treatment alternative rather than restoring it prosthetically. The medium of dental fragment conservation is important to maintain fragment hydration. It should be best stored in physiologic solution for short duration like normal saline.¹² Due to advancement in adhesive dentistry, the process of fragment reattachment has become easier and more reliable. This technique offers many advantages such as maintenance of original enamel and dentin, along with minimal chair time and no laboratory procedures. The wide range of materials available in the market today makes the choice of material difficult. Various materials such as flowable composite, dual cure or resin modified glass ionomers can be used.¹³

Luxa core Z (DMG; Chem-Pharm, Germany) was used in this case. It is a dual curing (chemical and light cure) resin. The advantage of this system is bond strength, aesthetics and complete curing.¹³ With all traumatic injuries, follow-up is of critical importance and the patient should be followed for 3, 6, and 12 months. At these follow-up visits esthetics, tooth mobility, and periodontal status were good both clinically and radiographically.

Conclusion

Reattachment of the intact fractured segment can be considered as an ultraconservative method for aesthetic rehabilitation. This procedure helps us to preserve maximal natural tooth structure. The superior quality adhesive materials make this procedure viable. The need of the day is to educate the population to preserve the fractured segment

and seek immediate dental treatment.

References

1. Patni P, Jain D, Goel G. A holistic approach to management of fractured teeth fragments: a case report. *Oral Surgery, Oral Medicine, Oral Pathology, Oral Radiology, and Endodontology*. 2010;109(5):e70-4.
2. Dietschi D, Jacoby T, Dietschi JM, Schatz JP. Treatment of traumatic injuries in the front teeth: restorative aspects in crown fractures. *Pract Periodontics Aesthet Dent*. 2000 Oct;12(8):751-8; quiz 760. 2.
3. Mojirade AD, Funmilayo A-SIM, Olaide GS. Reattachment of Fractured Anterior Tooth: A 2-Year Review of a Case. *International Journal of Prosthodontics and Restorative Dentistry*. 2011;1:123-7.
4. Andreasen JO, Andreasen FM. *Essentials of Traumatic Injuries to the Teeth: A Step-by-Step Treatment Guide*. John Wiley & Sons; 2010. 192 p.
5. Murchison DF, Burke FJT, Worthington RB. Restorative Dentistry: Incisal edge reattachment: indications for use and clinical technique. *Br Dent J*. 1999;186(12):614-9.
6. Aggarwal V, Logani A, Shah N. Complicated crown fractures â management and treatment options. *IntEndod J*. 2009;42(8):740-53.
7. Meiers JC, Kazemi RB. Chairside Replacement of Posterior Teeth Using a Prefabricated Fiber-Reinforced Resin Composite Framework Technique: A Case Report. *J EsthetRestor Dent*. 2005;17(6):335-42. 7.
8. Andreasen JO, Anderasen FM, Mejare I, Cvek M. Healing of 400 intra-alveolar root fractures. 1. Effect of pre-injury and injury factors such as sex, age, stage of root development, fracture type, location of fracture and severity of dislocation. *Dent Traumatol* 2004;20:192-202.
9. Reis A, Loguercio AD, Kraul A, Matson E. Reattachment of fractured teeth: a review of literature regarding techniques and materials. *Oper Dent* 2004;29:226-33.
10. Andreasen JO, Hjørting-Hansen E. Intra-alveolar root fractures: radiographic and histologic study of 50 cases. *J Oral Surg* 1967;25:414-26.
11. Andreasen JO, Anderasen FM, Mejare I, Cvek M. Healing of 400 intra-alveolar root fractures. 1. Effect of pre-injury and injury factors such as sex, age, stage of root development, fracture type, location of fracture and severity of dislocation. *Dent Traumatol* 2004;20:192-202.
12. Arhun N, Ungor M. Re-attachment of a fractured tooth: a case report. *Dent Traumatol* 2007;23:322-6.
13. Oz IA, Haytac MC, Toroglu MS. Multidisciplinary approach to the rehabilitation of a crown-root fracture with original fragment for immediate esthetics: a case report with 4-year followup. *Dent Traumatol* 2006;22:48-52.