

Posts in Primary Teeth-An Upright Pillar for Better Smile”

Mishra Neha Sanjeev¹, Harsimran Kaur², Rishika³, Ramakrishna Yeluri⁴

¹Post Graduate Student, Department of Pedodontics & Preventive Dentistry, Teerthanker Mahaveer Dental College & Research Centre, Delhi Road, Moradabad – 244001, Uttar Pradesh, INDIA.

²Professor, Department of Pedodontics & Preventive Dentistry, Teerthanker Mahaveer Dental College & Research Centre, Delhi Road, Moradabad – 244001, Uttar Pradesh, INDIA.

³Senior Lecturer, Department of Pedodontics & Preventive Dentistry, Teerthanker Mahaveer Dental College & Research Centre, Delhi Road, Moradabad – 244001, Uttar Pradesh, INDIA

⁴Professor and Head, Department of Pedodontics & Preventive Dentistry, Teerthanker Mahaveer Dental College & Research Centre, Delhi Road, Moradabad – 244001, Uttar Pradesh, INDIA.

How to cite this article: Mishra Neha Sanjeev Harsimran Kaur, Rishika et al. / Posts in Primary Teeth-An Upright Pillar for Better Smile” Indian Journal of Forensic Odontology. 2020;13(2):5 -11

Abstract

Dental caries is most common childhood disease which affects children in their very early stages of development. This also have deleterious effects like troubles in mastication, phonation and modifies esthetics. Post in decayed teeth can be effectively used to reestablish the lost form and function and it also helps in providing retention for coronal tooth structure.

Keywords: Early childhood caries; Post; Primary teeth.

Introduction

The healthy oral cavity is a primary requisite for beautiful looks. Dental caries is a predominant cause for tooth loss. Over the past decade, its occurrence has decreased in developed countries¹. Early childhood caries occurs initially in the cervical third of the maxillary incisors and it shows rapid development and progress which leads to the destruction of the crown entirely. Maxillary primary incisors are the first teeth in the oral cavity to get affected by ECC followed by rapid invasion of other primary teeth paving to early tooth loss, loss of vertical dimension, speech problems, malocclusion, reduced masticatory efficiency, tongue thrusting, space loss, and emotional problems. Pediatric dentist faces challenge to bring back esthetic of such severely decayed teeth².

In past few years, the different materials like strip crowns, polycarbonate crowns, veneered stainless steel crown etc. were presented which reestablish the carious teeth with adequate tooth structure. But

in cases of severely mutilated teeth, these materials fail to bear the occlusal forces³. Therefore, post and core methods became requisite for the fruitful accomplishment of endodontic treatment.

Ideal property of post⁴

- It must deliver ample retention and resistance.
- It should be well adapted to the internal dentinal wall.

Indications:^{4,5}

- To restore shape and form of a severely decayed or fractured maxillary anterior teeth crown with half of crown structure missing or at least 1mm of tooth structure remain supragingivally to provide support for final restoration.

Problems while placement of post in primary teeth: 6,7

- The morphology and histology of primary teeth present a less surface area for bonding, relatively large pulp chamber, and aprismatic enamel which is difficult to etch.
- Increase in the failure rate due to destruction of whole coronal structure.
- Extension of post in the primary root canal
- Inventions for short retentive posts are necessary in primary dentition due to the

Corresponding Author: Harsimran Kaur, Professor, Department of Pedodontics & Preventive Dentistry, Teerthanker Mahaveer Dental College & Research Centre, Delhi Road, Moradabad – 244001, Uttar Pradesh, India.
E: mail: simran2871@gmail.com

physiological resorption.

Classification of post used in primary teeth: (Table 1)⁴

Table 1: Classification of post in primary teeth

CLASSIFICATION OF POST USED IN PRIMARY TEETH				
Based on types of post space design	Based on material	Based on post design	Based on fabrication	Based on retention
<ul style="list-style-type: none"> Mushroom shaped Tapered shaped Onion shaped 	<p>Custom made</p> <p>Metallic</p> <ul style="list-style-type: none"> Alpha post Gamma post Omega post Half omega post Cast post <p>Non metallic</p> <ul style="list-style-type: none"> Composite post Mushroom post Biologic post <p>Prefabricated</p> <p>Metallic</p> <ul style="list-style-type: none"> metal post Reverse metal post <p>Non metallic</p> <ul style="list-style-type: none"> Fibre post Everstick post Polyethylene post Glass fibre post 	<ul style="list-style-type: none"> Threaded Non-threaded Alpha Half omega shaped Omega shaped Modified anchor shaped Gamma shaped 	<p>Direct method</p> <ul style="list-style-type: none"> Metallic post Fiber posts <p>Indirect method</p> <ul style="list-style-type: none"> Resin composite post Cast metal post 	<ul style="list-style-type: none"> Active Passive

Treatment procedure:

- Caries removal has to be done carefully being as conservative as possible, keeping intact hard dentin. Endodontic treatment of the retained root stumps has to be carried out using zinc oxide eugenol as the obturating material^{6,7}.
- After completion of the pulpectomy to appropriate depth, a 4 mm length of the coronal portion of the root filling should be removed.

The post-space has to be air dried & a 1 mm base of glass ionomer cement or zinc polycarboxylate cement should be placed to isolate the obturated material from the rest of post space. The rest 3 mm canal space is used for the placement of post⁵.

For each canal, trial fit of a post of corresponding size is done for proper fitting and length. The post has to be placed to a distance of 3 mm into the canal and 2 mm outside the canal. Any excessive length of the post is cut with a diamond bur under water coolant after taking an intraoral radiograph. This space should be rinsed and air dried with oil free compressed air. The ready post space should be then

cleaned with saline, air dried and acid etched with 37% phosphoric acid for 15 seconds. A light cured bonding agent should be brushed on the etched surface and uniformly dispersed by a compressed air blast. It has to then be light cured for 20 seconds. The flowable composites 2 to 3 mm below the CEJ are injected. The post is then introduced into the canal and light cured⁵.

Types of post used in primary dentition-

Omega post (Figure 1):⁸

In the year 2004 use of Omega loop was given by Mortada and King as intracanal retainer. Total of 5 mm long post is used in primary teeth.

Both 3mm long free ends of post is placed inside the canal. Remaining 2 mm of omega post provides retention to the coronal restoration. Omega post is made from 1.5cm length of 0.5mm round orthodontic stainless steel wire. Coronal extension provides retention to coronal restoration⁹. The bond amid Omega wire and dentinal wall is mechanical. Hence retention of Omega loop is less compared to GFRC (Glass Fibre Reinforced Composite).

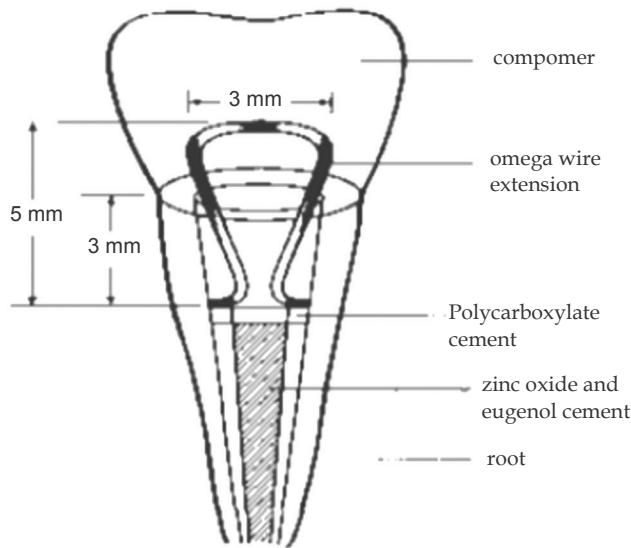


Fig. 1: omega loop extension

Half omega post (Figure 2):¹⁰ Stainless steel wire is bent to half omega shaped to make the post. A 0.7 mm stainless steel orthodontic wire has to bend into half omega shape to hold restorative material for core build.

Serrations should be prepared on the stainless steel wire to get enhanced mechanical retention. The incisal end of the loop of the wire should project 2 to 3 mm above the remaining root structure.

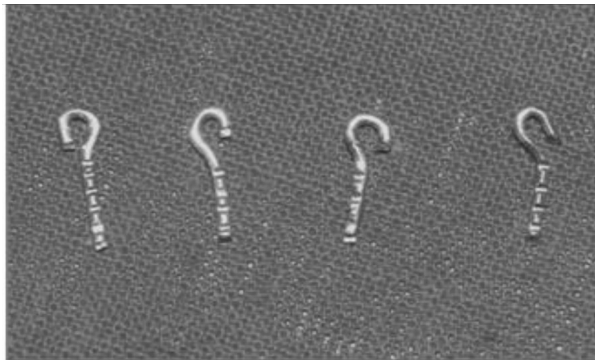


Fig. 2: Half Omega Post

It is direct adhesive restorative procedure which does not always have satisfactory result because of small surface of bonding and aprismatic nature of enamel that is difficult to etch.

Alpha post:¹¹ Stainless steel wire is bent into Alpha shaped and placed in the canal and extension should not be more than 3 mm.

Gamma post:¹² orthodontic wire of 0.6-mm is bent to form the Greek letter "y". The loop portion is placed inside the post space, and the 2 free ends

are placed toward the coronal portion and help to provide retention to coronal restoration.

Modified anchor shaped post (Figure 3):³ It was introduced to overcome the retentive difficulties of omega posts. For post fabrication one of the arms of 19-gauge wire is bent downwards and twisted it to the opposite side. Repeat the same procedure for the other arm. Bend the free end of the arms towards the curved end.

By squeezing the curved end, the free end opens up to adjust to the walls of the root thereby giving additional mechanical retention also mushroom shaped retention grooves placed for additional retention. Surplus compression is not advised as it may cause root fracture.




Fig. 3: modified anchor shaped post

Nickel chromium post with macroretentive element (Figure 4):⁵ Rodrigues Filho and co-workers (1995) detailed the use of nickel-chromium (Ni- Cr) cast posts. Such posts varied in thickness from 1.5 to 3.0 mm. The objective of this technique is to increase the resistance of the restored teeth to mechanical loading by bonding the intra canal retainer. This post with the round macroretentive elements gives enhanced resistance to masticatory forces. This post is used in enlarged canals.




Fig. 4: Nickel chromium post

Cast metal posts¹³ (Figure 5): They are fabricated using indirect method of fabrication. They have disadvantages includes higher cost and an extra laboratory step for preparation of post




Fig. 5: Cast metal post

*Reverse metal post (Figure 6):*¹⁴

Short prefabricated metal post is used as reverse metal post. The post is inserted upside down so that the 3-mm head hooked into the canal and the left behind 5 mm of the threaded unit is situated out of the canal as a core. Beveling should be done to reduce the pressure focused at the dentinal walls and then the head of the post is try-fitted with the coronal 3 mm of the canal. 3 mm of the coronal part of the canal is prepared for future replacement of post.

Canal is prepared nearly rectangular with semi-rounded line angles in order to match with the quadrangle core of a prefabricated metal post that is planned to be placed reversely into the prepared canal. Core length of prefabricated metal posts is 3mm.

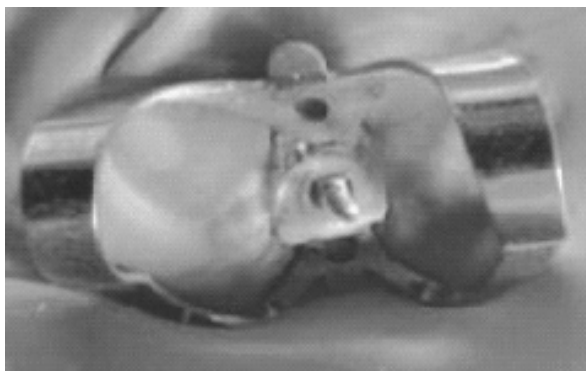


Fig. 6: Reverse metal post

*Glass ionomer short post:*¹⁵ In 1999 glass ionomer cement used directly as post in primary anterior teeth by Carranza F, Garcia GF to rise the retaining capacity of coronal restoration.

*Composite posts:*¹⁶ The composite resin short post and crown was established for the repair of severely decayed primary anterior teeth. The use of resin based composite post reinforced with metallic pins was suggested and a technique referred to as "short post" technique. Advantage of this post is that it provides satisfactory esthetics whereas polymerization contraction is the main disadvantage.

*Inverted mushroom shaped design post:*¹⁶ To create a 360° "inverted mushroom undercut" no. 6 round bur was utilized in the apical 2 mm to the gingival margin of the tooth. Light-cured composite resin in, 1.5 mm increments fabricated to the composite short post and then coronal structure cleaned and airdried and reconstructed with same composite.

*Indirect composite post:*¹⁷ A no. 4 carbide bur with a low speed rotary instrument is used to remove 1/3rd root fillings. Using preformed wooden sticks an impression of the canal is then made by using low-viscosity elastomeric impression material. According to the width of canals, post is selected and then thin coat of die isolation varnish is applied to selected post. To improve its adhesion to the composite resin, a silane primer layer is applied. After that composite build up done with embedded post. Then the post inserted into the canal and cured using adhesive resin.

Fibre based post:^{18,19}

Types:

Polyethylene fibre post (Ribbond)

Glass fibre post

Glass fibre reinforced composite resin Post (GFRP)

Carbon fibre post

*Polyethelene fibre(Ribbond) (Figure 7):*²⁰

Polyethylene fibre: These fibres increase the modulus of elasticity, impact strength and flexural strength of composite materials. They are nearly invisible in the resinous matrix with this property it is the best esthetic strengthners. In constructing the short posts, Ribbond was placed only in the cervical 1/3rd of the canals to avoid any disturbance to permanent teeth. This post is esthetically good and also simple to use.

Disadvantages include flexural strength which is fewer than GFRC post. These posts are expensive as well as technique sensitive.

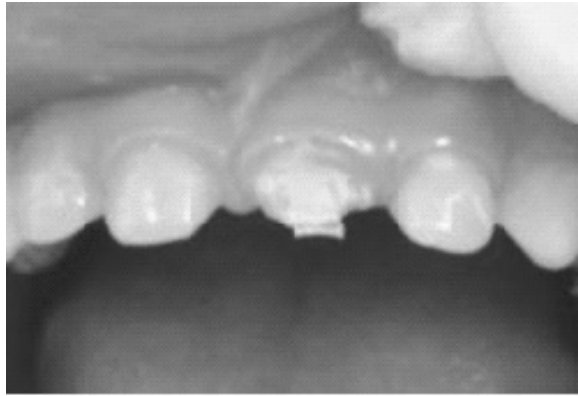


Fig. 7: Polyethylene fiber post

Glass fibre post:²¹ They are composed of unidirectional glass fibres rooted in resin matrix. They have advantage of stress distribution when there is broad surface area. The only disadvantage is to failure to stick to the resinous matrix which disturb esthetics and also interfere with resorption if placed beyond 3mm.

Glass fibre reinforced composite resin post (Figure 8):²² The properties of fibre- reinforced posts are dependent on matrix nature, fibres, interface strength and reinforcement geometry.




Fig. 8: Glass fibre reinforced composite post

This posts contain a high volume percentage of continuous reinforcing glass fibres embedded in a polymer matrix, which holds the fibres together. The matrix usually involves epoxy or acrylic polymers with or without filler materials. The fibres used in FRC posts may be classified according to fibre direction- unidirectional, bi-directional and pre-impregnated with unfilled resin or with filled resin.

Carbon fibre post:²³ It is non-metallic prefabricated and composite material post system, made of equally stretched and aligned continuous unidirectional carbon fibers, embedded in epoxy resin matrix and 8mm in diameter.

The carbon fiber post is a passive post, black coloured and available in different sizes i.e. 1 to 1.7 mm and shaped like parallel, serrated and smooth.

Ceramic post:²³ Zirconium oxide is used for fabrication of ceramic post with Yttrium oxide as a stabilizing agent. It has cylindro-conical design, where the post tapers in apical third to preserve tooth structure and for cementation.

Biologic post (Figure 9):

Santos and bianchi in 1991 described biological restoration. They used adhesive capabilities of materials in combination with strategic placement of section of extracted human teeth²⁴. Ramires-Romito et al (2000), also used teeth from human tooth bank as natural posts and crowns to fit into the roots and replace the crowns as well²⁵.

Tooth bank procedure⁴

Periodontal remnants are thoroughly scaled, polished and pulpal and periodontal remnants are removed followed by biological preparation. After that tooth are put into ultrasonic tank and sonicated for 30 minutes. And then teeth stored in HBSS at 4 degree Centigrade with donor identification.

Preparation of biological restoration:⁴ Teeth selected are reshaped as natural post using crown preparation kit. The roots that are made to function as posts are strengthened by flowable composite material.

Tooth for use as biological restoration are autoclaved at 121degree C and 15lbs pressure for 30 minutes before cementation. The trial and adjustments are done before cementation.

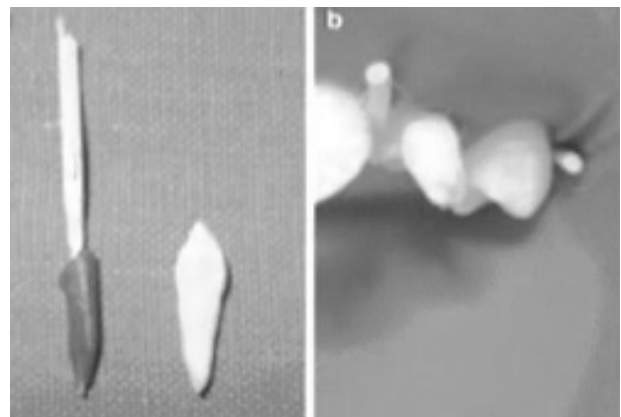


Fig. 9: Biologic post

Luting agents (Table 2):⁴ Many luting agents can be used for the cementation of post in primary canals. The selection of luting agents mainly depends on the type and material of the post being used.

Table no.2: Luting agents

Post	Luting agent	Suggested by
Ni-Cr post with macroretentive element	Dual cure resin	Wanderley MT (1999) ⁶
Gamma post		Kumar R Gajjar (2010) ¹³
Half omega post		Shrinivasan CH (2011) ¹¹
Glass Fibre Reinforced Composite post	Flowable composite	Yusuf K (2011)
Glass fibre post		Mehra M (2012) ²²
Omega (Metal post)	Glass ionomer cement	Ganesh R et al (2012)
Reverse metal post	Zinc phosphate cement	Eshghi A, Esfahan RK, Khoroushi M (2011, 2014) ¹⁵

Coronal restorations after post placement:⁴

Remaining coronal structure can be restored with direct or indirect technique or with single tooth prosthesis like strip crowns, stainless steel crowns, porcelain veneers, polycarbonate crowns, acrylic resin crowns

Conclusion

The judicious use of the above mentioned type of post and core methods can serve to prevent the loss of grossly carious primary teeth until their replacement by successor teeth.

References

1. Kumar R, Sinha A. Restoration of primary anterior teeth affected by early childhood caries using modified omega loops- A Case report. *Ann Dent Speciality*. 2014; 2(1):24-26.
2. Verma L, Passi S. Glass fibre reinforced composite post and core used in decayed primary anterior teeth: A Case Report. *Case Report Dent*. 2011:1-4.
3. Rajesh R, Baroudi K, Reddy BK, Praveen BH, Kumar SA. Modified Anchor shaped post core design for primary anterior teeth. *Case Report Dent*. 2014:1-4.
4. Swara S, Seema B, Anuradha KVR, Nikhil P. Posts in primary teeth-a sile for better smile. *journal of advanced medical and dental sciences research*. 2016; 4(1):58-64.
5. Wanderley MT, Ferreira SLM, Rodrigues CRMD, Filho LER. Pdmay Antedo. Tooth restoration using posts with macroretentive elements. *Quintessence*

Int. 1999; 30:432-436.

6. Guimaraes C, Ribeiro S, Biffi J, Mota. Comparative analysis of retention in prefabricated and fixed intracanal posts with different cement agents. *Rpg Rev Pos Grad*. 1999; 6:354-360.
7. Mortada A, King Nm. A simplified technique for the restoration of severely mutilated primary anterior teeth. *J Clin Pediatr Dent*. 2004;28:187-192.
8. Papathanasiou A, Curzon M, Fairpo C. The influence of restorative material on the survival rate of the restorations in primary molars. *Pediatr Dent*. 1994; 16: 282-288.
9. Kapur A, Chawla H, Goyal A, Gaube K. An esthetic point of view in very young Children. *J Clin Pediatr Dent*. 2005;30:99-103.
10. Srinivas N CH, Jayanthi M. Post endodontic restoration of severely decayed primary dentition: a challenge to pediatric dental surgeon. *World Journal of Dentistry*. 2011; 2(1):67- 69.
11. Pinheiro SL, Bönecker MJS, Duarte DA, Jmparato JCP, Oda M. Bond strength analysis of intracanal posts used in anterior primary teeth: an in vitro study. *J Clin Pediatr Dent*, 2006; 31(1): 32-34.
12. Kumar RG, Indushekar KR. Comparison of the retentive strength of 3 different posts in restoring badly broken primary maxillary incisors. *J Dent Child*. 2010; 77: 17- 24.
13. Motisuki C, Santos-Pinto L, Giro EM. Restoration of severely decayed primary incisors using indirect composite resin restoration technique. *Int J Paediatr Dent*. 2005; 15:282-286.
14. Eshghi A, Esfahan RK, Khoroushi M. A simple method for reconstruction of severely damaged primary anterior teeth. *Dental Research Journal*.

- 2011; 8(4): 221-225.
15. Carranza F, Garcia GF: Esthetic restoration of primary incisors. *Am J Dent.*1999;12: 55-58.
 16. Judd PL, Kenny DJ, Johnston DH, Yacobi R. Composite resin short-post technique for primary anterior teeth. *J Am Dent Assoc.* 1990; 120:553-555.
 17. Motisuki C, Santos-Pinto L, Giro EMA. Restoration of severely decayed primary incisors Restoration of severely decayed primary incisors using indirect composite resin restoration technique. *Int J Paediatr Dent.* 2005; 15: 282–286.
 18. Asmussen E, Peutzfeldt A, Heitmann T. Stiffness elastic limit and strength of newer types of endodontic posts. *J Dent.* 1999; 27: 275-278.
 19. Alessandro V, Simone G, Marco F. Comparison between two clinical procedures for bonding fiber posts into a root canal: A microscopic investigation. *J Endod.* 2002; 28: 355-360.
 20. Jain M, Singla S, Bhushan BAK, Kumar S, Bhushan A. Esthetic rehabilitation of anterior primary teeth using polyethylene fiber with two different approaches. *J Ind Soci Pedod Prev Dent.* 2011; 29(4): 327- 332.
 21. Mehra M, Grover R. Glassfibre post: An alternative for restoring grossly decayed primary tooth. *Int J clin Peadiat dent.* 2012; 5(2): 159-162.
 22. King A, Setchell D. An in vitro evaluation of a prototype CFRC prefabricated post developed for the restoration of pulpless teeth. *J Oral Rehabil.* 1990 17: 599-609.
 23. Abd El-Rahman AM, El-Kateb MA. Evaluation of a method for restoring severely decayed primary anterior teeth. *Al-Azhar Dent J.* 1992 7(4): 875-894.
 24. Santo J, Bianchi J. Restoration of severely damaged teeth with resin bonding systems. *Quintessence Int* 1991; 22: 611-615.
 25. Ramires RAC, Wanderley MT, Oliveria MD, Imparto JC, Pires Correa MS. Biological restoration of primary anterior teeth. *Quintessence Int* 2000; 35: 405-411.