

Original Research Article

Acute Eosinophilic Appendicitis: A Prospective Study

Megha H Kasture¹, Shivraj N Kanthikar², Sheela N Kulkarni³

¹Junior Resident, ²Associate Professor, ³Professor and Head, Department of Pathology, MIMSR Medical College, Vishwanathpuram, Latur, Maharashtra 413512, India.

Corresponding Author:

Shivraj N Kanthikar, Associate Professor, Department of Pathology, MIMSR Medical College, Vishwanathpuram, Latur, Maharashtra 413512, India.

E-mail: skanthikar@gmail.com

Received on 22.01.2020

Accepted on 15.02.2020

Abstract

Background: Acute Eosinophilic Appendicitis (AEA) is a rare entity characterised by eosinophilic infiltration of muscularis propria with accompanying edema separating the muscle fibres. It presents with similar symptoms as classical appendicitis. **Objective:** The present work aims to study the histomorphological features of AEA. **Methods:** Total 178 cases of appendicectomy were studied in the department of Pathology, MIMSR Medical college, Latur. Clinical features, gross and microscopic features were studied in detail. **Results:** Out of 178 cases of appendicectomy, 4 were diagnosed as Acute eosinophilic appendicitis. It included 1 male child, 2 adult males and 1 adult female. **Conclusion:** AEA cannot be diagnosed before surgery, hence Histopathology is the gold standard for diagnosis of AEA.

Keywords: Appendicitis; Eosinophilic; Histopathology.

How to cite this article:

Megha H Kasture, Shivraj N Kanthikar, Sheela N Kulkarni. Acute Eosinophilic Appendicitis: A Prospective Study. Indian J Pathol Res Pract. 2020;9(1 Part II):163-165.

Introduction

Acute eosinophilic appendicitis is an uncommon inflammatory condition of appendix.¹ It is a rare condition of unknown etiology having vague and unexplained symptoms.² The clinical presentation is similar to that of acute appendicitis and grossly shows inflamed appendix.¹ The histological hallmark of the entity is eosinophilic infiltration rather than neutrophilic, of the muscularis propria with accompanying edema, separating muscle fibres (Eosinophil - Edema Lesion).³ Histopathological examination is the gold standard for the diagnosis.²

Materials and Methods

A Prospective study was conducted from January 2018 to May 2019 for a period of 17 months in the

Department of Pathology, MIMSR Medical College, Latur. The appendicectomy specimens received, were fixed in 10% Formalin. The length and circumference at the point of maximum thickness were measured. Sections from base, middle and tip and from grossly abnormal areas were taken. Sections were processed routinely and stained in H & E.

Results

A total 178 appendicectomy specimens were received from January 2018 to May 2019. 4 out of 178 appendices, of patients aged 5 to 50 years showed Acute Eosinophilic Appendicitis (AEA). The patients of AEA comprised of 1 male child (25%), 2 adult males (50%) and 1 adult female (25%).

In our study, patients presented chiefly with pain in abdomen and few presented with nausea and vomiting. There was no history of allergy, no history of peripheral eosinophilia, no history of parasitic infestation.

Grossly, appendices were swollen, inflamed and externally congested. Microscopically, the AEA appendices showed intact hyperemic mucosa. The muscularis propria showed eosinophilic infiltrate accompanied by edema and muscle fibre separation (Fig. 1 & 2).

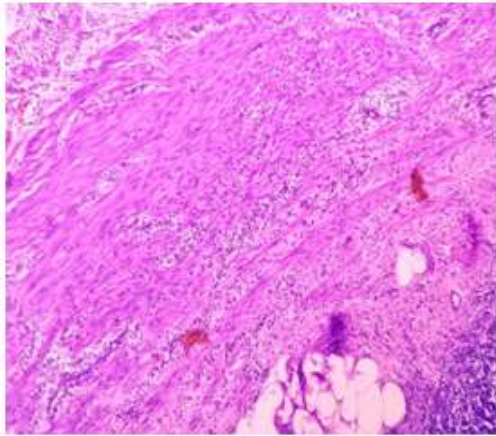


Fig. 1: Photomicrograph showing eosinophilic infiltration of all coats of appendix.

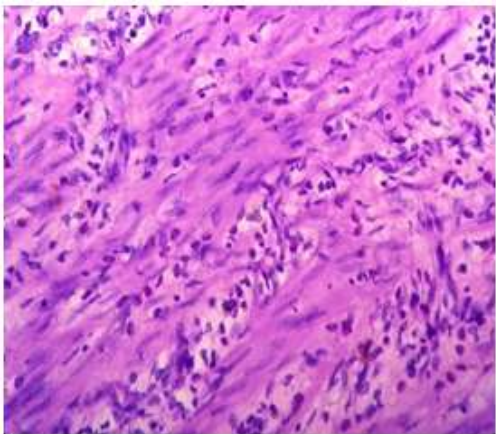


Fig. 2: Photomicrograph showing eosinophilic infiltration of muscularis propria separating the muscle fibres.

Discussion

AEA was first proposed by Aravindan in 1997 and defined by Aravindan et al.³ in 2010. Aravindan in a study of 120 appendicectomies found that mural eosinophilic infiltrate is sole and consistent finding in Acute appendicitis. He also suggested that eosinophilic infiltrate seen in acute appendicitis is an early event linked possibly to Type I

hypersensitivity. He hypothesized that AEA falls within the spectrum of acute appendicitis and the E-E Lesion is an early event in its evolution.

Carr NJ⁴ suggested that eosinophil count of more than 10/cmm (25/10 HPF) could be abnormal and labelled as eosinophilic appendicitis. In our study, this criterion was fulfilled. (>25 eosinophils/HPF).

Shivraj Kanthikar et al.² reported an unusual case of Eosinophilic obliterative appendicitis with unexplained symptoms. The study concluded that histopathology is the gold standard for diagnosis.

Rajeshwari K et al.⁵ studied 159 appendicectomy specimens, out of which 3 cases were found to be of AEA. Criteria to diagnose EA used were -

1. Transmural eosinophilic infiltrate in the wall of appendix,
2. More than 25 eosinophils/HPF in muscularis,
3. Absence of polymorphs or any other pathology in the wall.

In this study, incidence of 1.8% (3/159) with male preponderance was found.

Talley NJ et al.⁶ identified 3 main diagnostic criteria-presence of gastrointestinal symptoms, biopsies demonstrating eosinophilic infiltration of one or more areas of GIT, no evidence of parasite or extrinsic disease.

Tufan Egeli et al.⁷ reported a case of AEA that developed on an allergic background caused by amoebiasis. Histopathologic examination of surgical specimen revealed intense eosinophilic infiltration and edema in serosa and muscular layer of appendix. Direct stool examination was performed in post-operative period as patient was residing in endemic area for parasitic infestation. Stool examination revealed trophozoites of *E. histolytica* and AEA was considered to be associated with allergic reaction caused by this parasite. In our study, stool examination was negative for parasite.

Gayatri Deshpande et al.⁸ presented a case of Primary Acute eosinophilic Appendicitis. The clinical and radiological findings were suggestive of Acute appendicitis. Histopathological examination revealed an intense eosinophilic infiltration with edema extending up to serosa, suggesting AEA.

Sunil V.J. et al.⁹ reported a case of AEA, presented with mucocele. On light microscopy, all coats, especially muscularis propria showed dense and diffuse eosinophilic infiltrate (>25/HPF). Post-operative hematological examination was within normal limit. Stool examination was negative for parasite. Upper GI endoscopy and biopsy were

performed to rule out stomach involvement, which showed no eosinophilic infiltration.

Gaurav Jain et al.¹⁰ studied 268 appendicectomy cases, out of which 5 were diagnosed as Eosinophilic appendicitis. Incidence of 1.9% (5/268) with male preponderance was found. The study proposed that in cases of laparotomy done for various reasons, appendix should be observed carefully and if found congested, should be removed. Such practice can prevent further occurrence of acute appendicitis, and thus appendicectomy in the future. It also stated the need for detailed study of AEA for better patient management.

Dr. Vanita Kumar et al.¹ did a prospective study in 400 appendicectomy cases to find 10 patients with AEA. Incidence of 2.5% (10/400) was found with male preponderance. The study concluded that AEA is a rare event, less well-understood entity and an early marker of acute appendicitis.

In our study, out of 178 Appendicectomies, 4 were found to have AEA with incidence of 2.2% (4/178) and male preponderance. All the 4 cases showed eosinophilic infiltration in muscularis propria. All 4 cases were negative for peripheral eosinophilia. Stool examination for parasite was negative as well.

Conclusion

Acute Eosinophilic Appendicitis is a rare entity with vague symptoms. It requires to be studied in detail for better patient approach and management. Histopathology remains the mainstay for the diagnosis.

Acknowledgements: Nil.

References

1. Kumar V. Acute Eosinophilic Appendicitis: A prospective study in consecutive 400 appendicectomy cases. IOSR Journal of Dental and Medical Sciences (IOSR-JDMS) 2017;16(10):87-90.
2. Kanthikar SN, Nikumbh DB, Desale SS. Primary Eosinophilic Obliterative Appendicitis. Online J Health Allied Scs 2014;13(1):6.
3. Aravindan KP, Deepthy V, Marie TM. Acute Eosinophilic appendicitis and the significance of eosinophil-Edema lesion. Indian J PatholMicrobiol 2010;53:258-61.
4. Carr NJ. The pathology of acute appendicitis. Ann Diagn Pathol 2000;4:46-58.
5. Rajeshwari K, NV Dravid, Karibasappa GN, et al. Acute Eosinophilic Appendicitis: Case report of three cases with brief review of literature. Annals of Applied Bio-Sciences 2015;2(2).
6. NJ Talley, RG Shorter, SF Phillips, et al. Eosinophilic gastroenteritis: A clinicopathological study of patients with disease of the mucosa, muscle layer and the subserosal tissue. Gut 1990;31:54-58.
7. Tufan E, Murat O, Fatih T, et al. Acute Eosinophilic Appendicitis: An unusual variant of Appendix inflammation. Journal of diseases of the Colon and Rectum 2013;23:107-10.
8. GayatriDeshpande, Murtaza Akhtar, DivishSaxena, et al. Primary Acute Eosinophilic Appendicitis: A case report with literature review. International Journal of Current Research 2016;8(12):44274-276.
9. Sunil VJ, Dhiraj BN. Eosinophilic appendicitis presented as mucocele: A rare clinical entity. International Journal of Health Sciences and Research, May 2012;2(2):99-103.
10. Gaurav Jain, Sujata R Kanetkar. Eosinophilic appendicitis: Case report of five cases and review of literature. Journal of medical research and practice 2013;2(8):208-11.

