

A Comparative Study on Efficacy of Intravenous Fentanyl Vs Ultrasonography (USG) Guided Fascia Iliaca Compartment Block Prior to Subarachnoid Block in Patients Undergoing Fracture Femur Surgeries

Mahamad Javeedulla Baig¹, Harsha Prakash BG², Puneet Rate SP³, Satish Kumar MN⁴,
Sudheesh K⁵, Ramachandraiah R⁶

^{1,2,4}Assistant Professor, ³Post Graduate, ⁵Professor, ⁶Professor and Head, Department of Anaesthesiology, Bangalore Medical College and Research Institute, Bengaluru, Karnataka 560002, India.

Abstract

Background: Pain arising from fracture of femur is of severe nature, and any degree of movement can worsen the pain. Surgery for fixation of femoral fractures may be done under spinal anesthesia. Fascia Iliaca Compartment Block (FICB) produces a simultaneous block of the femoral and of the lateral femoral cutaneous nerves, provides good pain relief for patients with fracture femur and even intravenous fentanyl can also be used to relieve the pain. *Aims:* We conducted this study to compare the analgesic efficacy of Intravenous Fentanyl (IVF) and Ultrasonography (USG) Fascia Iliaca Compartment Block (FICB) for preoperative pain relief and while positioning for subarachnoid block and also to assess the duration and quality of postoperative analgesia in the first 12 hrs. *Materials and Methods:* Sixty patients aged 18 to 65 years, with American Society of Anesthesiologists status I to II, undergoing surgery for femur fracture were chosen for the study and randomized into 2 groups. Group A ($n = 30$) received 1 mcg/kg fentanyl Intravenously and Group B ($n = 30$) underwent ultrasonography (USG) guided FICB with 0.5% Bupivacaine of 20 ml volume, 20 minutes prior to positioning for subarachnoid block. Preprocedural and postprocedural parameters such as hemodynamic parameters, visual analog scale (VAS) scores for 12 hours and quality of positioning and request of first rescue analgesia were recorded. *Results:* Preprocedural VAS scores were similar in both groups. Postprocedure VAS score in Group B was significantly less compared to Group A. Patients in Group B had better quality of positioning for subarachnoid block. Requirement of first rescue analgesia was prolonged in Group B compared to Group A. *Conclusion:* FICB group patients had better quality of positioning subarachnoid block and prolonged postoperative analgesia. This suggests USG guided FICB is an effective way to reduce patient discomfort during positioning for subarachnoid block in femoral fractures and prolong postoperative analgesia.

Keywords: Fascia iliac compartment block; Intravenous fentanyl; Subarachnoid block; Femoral fractures.

How to cite this article:

Mahamad Javeedulla Baig, Harsha Prakash BG, Puneet Rate SP, et al. A Comparative Study on Efficacy of Intravenous Fentanyl Vs Ultrasonography (USG) Guided Fascia Iliaca Compartment Block Prior to Subarachnoid Block in Patients Undergoing Fracture Femur Surgeries. Indian J Anesth Analg. 2020;7(2):506–510.

Corresponding Author: Harsha Prakash BG, Assistant Professor, Department of Anaesthesiology, Bangalore Medical College and Research Institute, Bengaluru, Karnataka 560002, India.

E-mail: harshaprakashbg@gmail.com

Received on 23.01.2020, **Accepted on** 12.02.2020

Introduction

Fracture femur, a common injury, is associated with significant pain and is generally treated with internal fixation with an implant.¹ These surgeries are usually conducted under central neuraxial blocks, but patients experience pain on attempted flexion at hip joint during positioning for neuraxial blockade² and need analgesia.

A Fascia Iliaca Compartment Block (FICB), which produces a simultaneous block of the femoral and of the lateral femoral cutaneous nerves,³ provides good pain relief for patients with femoral shaft fracture.⁴ Patients experience pain in the postoperative period and analgesics are required in frequent doses causing undesirable side-effects, i.e. Opioids cause respiratory depression, hypotension, confusion and impractical for ward administration, instead, a single local anesthetic dose as peripheral nerve block provides adequate and prolonged analgesia.⁵ Amongst the procedures, ultrasound guided FICB is superior in terms of efficacy, safety and easy administration⁶ providing unilateral analgesia, reducing side-effects, without motor blockade and fewer neurological complications.^{7,8}

Materials and Methods

Institutional Ethical Committee approval and informed consent from the patient were taken prior to study. Patients of both sexes posted for elective fracture femur surgeries who were unable to sit due to pain, age between 18 and 65 years, American Society of Anesthesiologists (ASA) physical status Grade 1 & 2, were included in the study. Patients who refused to give consent, who could sit comfortably and contraindication for spinal anesthesia were excluded from study.

The sample size was computed based on previous studies, keeping reduction in Visual analog scale scores by 15% after Fascia iliac compartment block as the primary outcome variable. Power - 80% and confidence interval of 95%, required sample size in each group was 28, approximated to 30.

Patients were divided into two groups 30 in each: IV Fentanyl (Group A) and USG guided FICB (Group B). Group A ($n = 30$) - received 1 mcg/kg Fentanyl IV Group B ($n = 30$) - underwent USG guided FICB with 0.5% Bupivacaine of 20 ml volume. All patients were subjected to preanesthetic evaluation one day before surgery and advised tablet alprazolam 0.5 mg night before surgery. In the preoperative waiting room, patients was connected to standard

monitoring like noninvasive blood pressure, pulse oximetry, electrocardiogram and baseline readings noted. Baseline Visual Analog Scale (VAS) score was noted.

Patients were randomized in a 1:1 allocation ratio by simple randomization using randomization.com, a web based tool, into two groups of 30 each, i.e. Group A and Group B. Patients were in Group A will receive 1 mcg/kg Fentanyl IV 20 minutes prior to surgery and patient will be shifted into the operating room. While positioning for Subarachnoid block, additional 0.5 mcg/kg dose will be added if VAS score > 4.

Patients who were in Group B will underwent Ultrasound guided Fascia Iliaca Compartment Block 20 min prior to shifting into OT. Under aseptic precautions, Sonosite ultrasound machine with linear probe was placed transversely, just inferior to the inguinal ligament, one-thirds of the distance from Anterior Superior Iliac Spine to Pubic Tubercle. Fascia Lata and Fascia Iliaca was visualized as 2 hyperechoic lines. A short beveled, 23G Quincke's spinal needle was introduced through the skin in a lateral to medial orientation and directed in plane to the probe to allow visualization of the full needle throughout the procedure. Needle tip was visualized penetrating the Fascia Lata and Fascia Iliaca. After puncturing Fascia Iliaca and negative aspiration, 20 ml of 0.5% Bupivacaine was injected in 10 ml aliquots over 2-3 minutes.

An expanding anechoic collection just below fascia iliaca was the visual confirmation of correct placement of drug. 20 minutes after administering the block, patient was shifted into the operating room. Patient was placed in sitting position and subarachnoid block was done using Inj. Bupivacaine 0.5% (H) 3 ml.

All vital parameters, VAS score (0 = no pain and 10 = worst pain), patient positioning (satisfactory or nonsatisfactory) and time taken to perform subarachnoid block was noted. Post operatively we monitored time for first rescue analgesia and VAS score on every 3 hours upto 12 hrs.

Statistical Analysis

Results obtained will be analyzed using descriptive statistics. Parametric variables will be analyzed using paired "t" test, unpaired "t" test and ANOVA. Parameter variables described as mean \pm SD; qualitative variables were described as numbers (percentage) and as median and range. p - value of < 0.05 was considered as significant.

Results

Demographic parameters were not significantly different between the groups, (Table 1). Baseline values for Heart Rate (HR), systolic blood pressure,

diastolic blood pressure, SpO₂ and respiratory rate were comparable in both the groups and not significant. It was noted that HR was significantly reduced in both groups $p = 0.05$ (before and after procedure), (Table 2).

Table 1: Demographic data

Parameters	FICB (n = 30)	IV Fentanyl (n = 30)	p-value
Age (mean ± SD)	42.03 ± 14.37	38.66 ± 14.79	0.377
Weight (mean ± SD)	58.1 ± 8.2	57.93 ± 8.6	0.96
Male	19	22	0.577
Female	11	8	
ASA 1	10	17	0.11
ASA 2	20	13	

Table 2: Vital clinical parameters before and after procedure

FICB	Before FICB (mean ± SD)	20 min After (mean ± SD)	p-value
PR (b/min)	78.2 ± 8.26	70.23 ± 7.07	< 0.05
SBP (mm Hg)	129.33 ± 12.39	123.66 ± 14.17	0.32
DBP (mm Hg)	81.33 ± 6.41	83.96 ± 6.39	0.48
SpO ₂ (%)	99.16 ± 0.87	99.3 ± 0.95	0.88
RR (min)	20.43 ± 2.98	18.36 ± 2.45	0.12
IV Fentanyl	Before IV Fentanyl (mean ± SD)	20 min After (mean ± SD)	p-value
PR (b/min)	78.6 ± 9.21	71.28 ± 8.8	< 0.05
SBP (mm Hg)	131.14 ± 28.5	127.16 ± 12.07	0.41
DBP (mm Hg)	83.77 ± 6.05	84.36 ± 5.62	0.24
SpO ₂ (%)	99.22 ± 0.78	99.14 ± 0.96	0.52
RR (min)	19.78 ± 2.8	19.66 ± 2.38	0.72

VAS score after 20 mins of procedure was reduced in both groups, however, Group B (FICB) patients had lower VAS score compared to Group

A (IVF) and it was statistically significant $p = 0.05$, (Fig. 1).

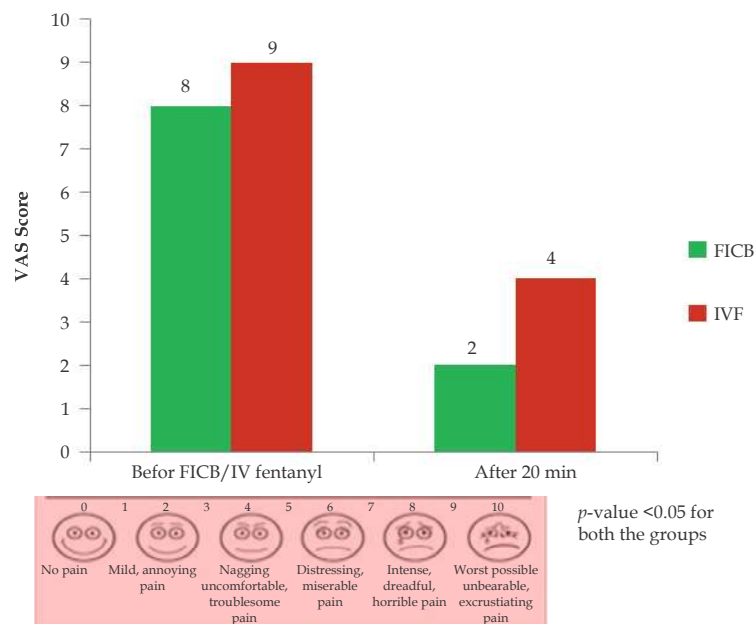


Fig. 1: VAS Score before and after procedure.

Quality of patient positioning for spinal anesthesia was most satisfactory in Group B (FICB) compared to group A (IVF) and it was statistically significant $p = 0.05$, (Table 4). This was further

assessed by time taken to perform subarachnoid block which was lesser in FICB group compared to IVF Group, (Table 3 and 4).

Table 3: Patient positioning for Subarachnoid block

Parameters	FICB (n = 30)	IV Fentanyl (n = 30)
Satisfactory	26	11
Not-satisfactory	4	19

* p - value < 0.05.

Table 4: Time to perform subarachnoid block

Parameters	FICB (n = 30)	IV Fentanyl (n = 30)
Time (min)	6.9 ± 2.5	10.8 ± 5.4

Postoperative assessment showed time for first rescue analgesia was higher in Group B (FICB) i.e. 7.46 ± 1.64 when compared to Group A (IVF) i.e. 3.86 ± 1.59 and significant p

= 0.05, (Table 5). Postoperative VAS score was significantly less in Group B compared to Group A, (Fig. 2).

Table 5: Rescue analgesic requirement

Parameters	FICB (mean ± SD)	IV Fentanyl (mean ± SD)
Time to 1 st rescue therapy	7.46 ± 1.64	3.86 ± 1.59*

* p - value < 0.05.

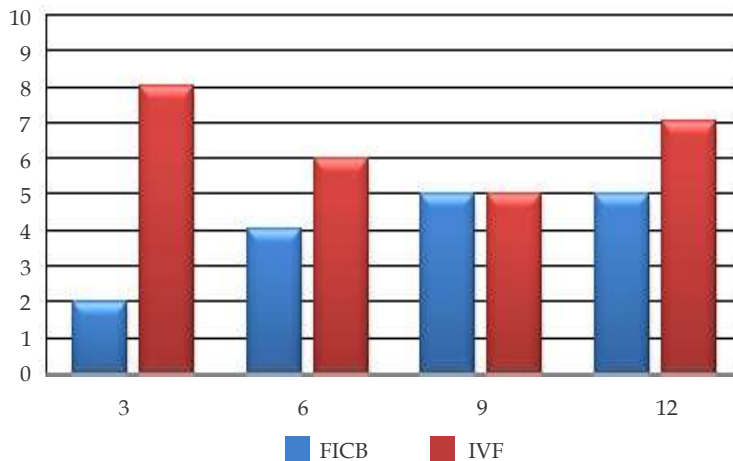


Fig. 2: Postoperative VAS Score.

Discussion

In present era of trauma, the number of patients encountered with fracture femur is routinely observed. It has noted such patients suffer from severe pain and anxiety. Any degree of movement can increase the pain and causes more discomfort to the patients. Spinal anesthesia is universally accepted and preferred technique of anesthesia

for surgical repair of fracture femur. This is due to many advantages of spinal anesthesia over general anesthesia like better analgesia, early mobility, less deep vein thrombosis and less of postop pulmonary complications in elderly patients.

For the technique of spinal anesthesia proper positioning of the patient is at most important. Pain itself can lead to improper position and difficulty in performing subarachnoid block

and more so, very distressing for patients and stressful situation for performing anesthetist. So, to reduce the pain for proper position during subarachnoid block, various agents like midazolam, ketamine, fentanyl, alfentanyl etc. are used which have their own limitations because of their adverse effects. To overcome this, nerve block are frequently used. Ultrasound guided FICB which block femoral nerve and lateral cutaneous nerve of thigh provides better analgesia and aids in satisfactory positioning of patients during subarachnoid block.

In our study, both USG guided FICB and IV fentanyl provided reduction in VAS scores. However, in contrast, FICB was found to provide superior analgesia over IV fentanyl Madabushi R et al.³, Mosaffa et al.⁴ showed similar results.

Although we followed attainment of VAS score of < 4 before attempting patient positioning, patients invariably reported a higher VAS at the end of positioning from the time of initiation of sitting in IV fentanyl group. A study by Ranjit S et al.⁵ and Yun et al.² found similar results that the FICB offers better hip flexion and ability to sit upright. In IV fentanyl group, 3 hour after surgery VAS score was significantly higher compared to FICB group and requires early rescue therapy compared to FICB group. Study done by Madabushi R et al., used ropivacaine 0.3%³ and Mosaffa et al., used lignocaine 1%⁴ have shown FICB superior over IV fentanyl but there was an early requirement of rescue therapy in FICB group compared to our study. This may be because of use of bupivacaine which is long acting local anesthetic drug.

Conclusion

FICB offers superior analgesia, satisfactory positioning for central neuraxial block than IV fentanyl in patients undergoing surgery for fracture femur and reduces rescue analgesic requirement by providing prolonged postoperative analgesia.

Limitation: We have not measured sitting angle.

Conflict of Interest: None.

References

1. Zywiell MG, Prabhu A, Perruccio AV, et al. The influence of anesthesia and pain management on cognitive dysfunction after joint arthroplasty. *Clin Orthop Relat Res* 2014;472:1453-66.
2. Yun MJ, Kim YH, Han MK, et al. Analgesia before a spinal block for femoral neck fracture: Fascia iliaca compartment block. *Acta Anesthesiol Scand* 2009;53(10):1282-87.
3. Madabushi R, Rajappa GC, Thammanna PP, et al. Fascia iliaca block vs intravenous fentanyl as an analgesic technique before positioning for spinal anesthesia in patients undergoing surgery for femur fractures: A randomized trial. *J Clin Anes* 2016;35:398-403.
4. Mosaffa F, Esmaelijah A, Khoshnevis H. Analgesia before performing a spinal block in the lateral decubitus position in patients with femoral neck fracture: A comparison between fascia iliaca block and IV fentanyl. *Reg Anesth Pain Med* 2005;30(Suppl. 1):61.
5. Ranjit S, Pradhan BB. Ultrasound guided femoral nerve block to provide analgesia for positioning patients with femur fracture before subarachnoid block: Comparison with intravenous fentanyl. *Kathmandu Univ Med J (KUMJ)* 2016 Apr-Jun;14(54):125-29.
6. Lopez S, Gros T, Bernard N. Fascia iliaca compartment block for femoral bone fractures in prehospital care. *Reg Anesth Pain Med* 2003;28:203-207.
7. Foss N, Kristensen B, Bundgaard M, et al. Fascia iliaca compartment blockade for acute pain control in hip fracture patients. *Anesthesiology* 2007;106(4):773-78.
8. Terese T Horlocker, Sandra L Kopp, Denise J Wedel. Peripheral nerve blocks in Ronald D Miller, Neal H Cohen. *Miller's Anesthesia*, 8th edition. Vol 2. Philadelphia: Elsevier; 2015. pp.3179-80.