

## Case Report

## Castleman Disease: Unusual Presentation of Solitary Neck Mass

Lena Abdul Baset Labania<sup>1</sup>, Maryam Nasir Hussain<sup>2</sup>, Sunil Kumar Bylappa<sup>3</sup>

<sup>1,2</sup>Postgraduate Intern, <sup>3</sup>Anatomic Pathology Specialist and Lecturer, Thumbay Labs, Gulf Medical University, Ajman, United Arab Emirates.

**Corresponding Author:**

**Maryam Nasir Hussain**, Postgraduate Intern, Thumbay Labs, Gulf Medical University, Ajman, United Arab Emirates.

**E-mail:** maryam.nasir89@yahoo.com

**How to cite this article:**

Lena Abdul Baset Labania, Maryam Nasir Hussain, Sunil Kumar Bylappa. Castleman Disease: Unusual Presentation of Solitary Neck Mass. Indian J Pathol Res Pract 2020;9(2 Part I):121-124.

**Abstract**

**Introduction:** Castleman disease (CD) is a rare lymphoproliferative disorder characterized by enlargement of lymph nodes. The aim of the study was to present an unusual presentation of the disease. Due to very limited number of cases the exact statistical data is not available. CD is classified into two clinical entities; unicentric presentation with the disease confined to a single lymph node and a multicentric presentation characterized by generalized lymphadenopathy and a more aggressive clinical course. It is also classified based on the Histological appearance of the lymph node mainly, hyaline vascular type and plasma cell type.

**Case Report:** A case report of a 30-year old male presenting with swelling in the right side of the neck, gradually increasing in size, associated with on and off mild pain for more than a year. Physical examination, coagulation tests, infectious disease screening (HIV, HCV and HBsAg), ESR test and chest X-ray were all normal. Both computed tomography (CT) and Ultrasonography (USG) findings showed a well-defined solid enhancing mass lesion in the inferior part of the right posterior triangle, extending in the supraclavicular fossa, with a displacement of the right jugular vein. Reactive lymphadenopathy features were seen in FNAC. Microscopic examination of Biopsy showed a well-encapsulated lymphnode tissue with an expanded mantle zone (paler areas), regressed follicles with radially penetrating sclerotic blood vessels (lollipop-like appearance), indicating a Unicentric Castleman disease, hyaline-vascular type.

**Conclusion:** Unicentric Castleman disease is a rare benign condition, surgical resection is curative. Histopathological examination rules out lymphoma and concluded that it is Unicentric Castleman disease, hyaline-vascular type case.

**Keywords:** Castleman Disease; Lymphadenopathy; Hyaline-vascular; Cervical; Lymph node; HIV.

**Introduction**

Castleman disease is a rare lymphoproliferative disorder characterized by enlargement of lymph node due to abnormal overgrowth of cells of the lymphatic system. It is also known as angiofollicular lymph node hyperplasia or giant lymph node hyperplasia.<sup>1</sup> Castleman disease was first described by Dr. Benjamin Castleman in 1954.<sup>2</sup> Due to its

rarity and limited cases the exact statistical data are missing. Clinically, Castleman disease is classified into twotypes:

- *Unicentric (Localized) Castleman disease (UCD):* This is the most common type of Castleman disease which only affect a single region of lymph nodes. Mostly lymph nodes in chest or abdomen are affected. The patient is mostly asymptomatic with a single site lymph node enlargement.

- *Multicentric Castleman disease (MCD):* This form is more serious than UCD that affects multiple regions of lymph nodes and is characterized by generalized lymphadenopathy. Symptoms of MCD are often non specific and may include serious infections, fever, fatigue, excessive sweating, weight loss, skin rash and more aggressive clinical course. Elevated interleukin 6 (IL-6) production can be seen in MCD patients. *Multicentric is further classified into two categories:* HHV-8 positive Multicentric Castleman disease which often occurs in immunocompromised individuals, such as those with human immunodeficiency virus (HIV) infection and idiopathic Multicentric Castleman disease which is negative for HHV-8 and HIV.<sup>3,4</sup>

Castleman disease is also classified based on the microscopic appearance of the lymph node. Histologically types are:

- *The hyaline vascular type:* Characterized by lymphoid follicular proliferation at different levels of maturity, often forming a layered or 'onion skin' pattern surrounding a hyalinized vessel at the center of the follicle. Most seen in UCD(90%).
- *The plasma cell type:* Characterized by Interfollicular plasmacytosis with hyperplastic germinal centers and has significantly less vascularity. Mostly seen in multicentric Castleman disease type.
- *The mixed cell type:* Shows both characteristics of hyaline vascular and plasma cell type.<sup>3,4</sup>

Castleman disease (CD) is difficult to diagnose for it is both a rare disease and an imitator of many other diseases as patients have the same symptoms as some cancers and autoimmune diseases. Thus, it is often necessary to rule out many other diseases before CD is suspected. The disease is diagnosed based on the symptoms present, blood test results, imaging studies, and biopsy results of the lymph nodes. As in MCD patient elevated level of Interleukin-6 (IL-6) could be helpful in ruling out other autoimmune conditions with similar signs and symptoms. Also, CT scan and Ultrasound can be helpful in identifying enlarged lymph nodes. Furthermore, to confirm the diagnosis a biopsy of affected tissues is usually recommended in order to differentiate Castleman disease from other types of lymphatic tissue disorders, such as lymphoma. This case was presented due to its rarity and unusual

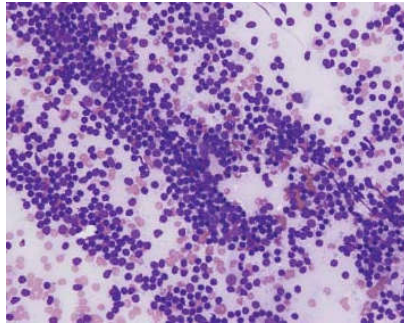
presentation of the disease in form of age, gender and site of presentation.

### Case Report

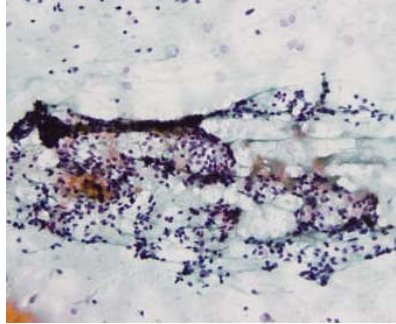
A 30-year-old male with no previous medical, family or psychosocial history, presented with swelling in the right side of the neck, gradually increasing in size, associated with on and off mild pain for more than a year.

Physical examination, coagulation tests, infectious disease screening (HIV, HCV and HBsAg), ESR test and chest X-ray were all normal. Clinical chemistry test showed increased levels of both AST and ALT and a slightly increased RBC count was found in the Complete Blood Count test. Both computed tomography (CT) and ultrasonography (USG) findings showed a well-defined solid enhancing mass lesion in the inferior part of the right posterior triangle, extending in the supraclavicular fossa, with a displacement of the right jugular vein, measuring 6.4 (transverse) x 3 (craniocaudal) x 4 (anteroposterior) cm. Additionally, USG showed few enlarged lymph nodes in the bilateral upper deep cervical location, having preserved fatty hilum and smooth margins. The largest of these lymph nodes measures 2.5 x 0.9 cm on the right. The perinodal planes were smooth and well preserved. No evidence of any intranodal necrosis, perinodal fluid collection or any abscess formation were seen. CT showed no other significant lymphadenopathy. Radiologist suggested a differential of lymphoma or a neurogenic mass, and asked for histopathological confirmation.

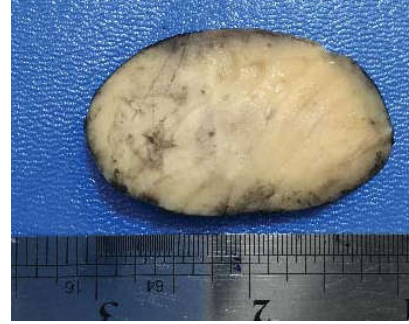A subsequent fine needle aspiration (FNAC) showed a mixed population of lymphoid cells, predominantly small lymphocytes (Fig. 1 and Fig. 2). Centrocytes, centroblasts, few macrophages and lymphohistiocytic aggregates were also seen. The background showed RBCs. The patient underwent an excision biopsy under general anaesthesia. The mass was dissected and excised completely and was sent for histopathological examination. Grossly the lymph node was enlarged with cut section showing homogenous gray white color (Fig. 3). Microscopic examination showed a well-encapsulated lymph node tissue with an expanded mantle zone (paler areas), regressed follicles with radially penetrating sclerotic blood vessels (lollipop-like appearance) (Fig. 4 and Fig. 5), indicating a Unicentric Castleman disease, hyaline-vascular type. Postoperative phase was uneventful. There was no recurrent swelling two months post-operative.



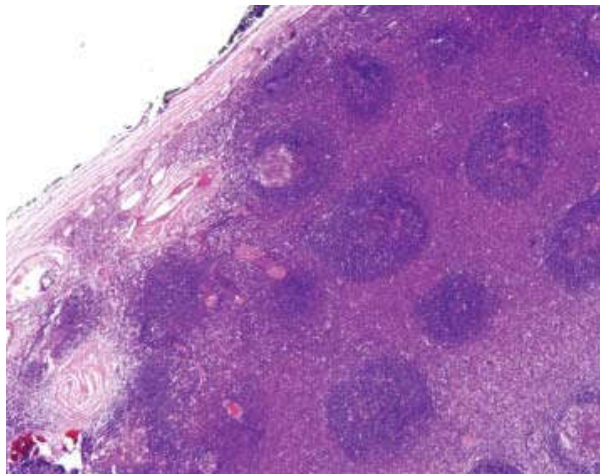
**Fig. 1:** Heterogenous lymphocyte population. (Romanowsky stain, x200).



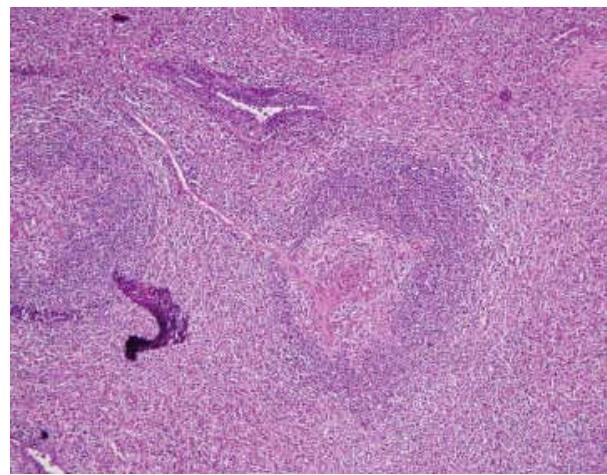
**Fig. 2:** Small round lymphocytes and dendritic cells. (Papanicolaou stain, x400).



**Fig. 3:** Enlarged lymph node: well circumscribed, solid gray cut surface.



**Fig. 4:** Enlarged lymph node with numerous follicles. (Hematoxylin and eosin stain, x100).



**Fig. 5:** Hyaline-vascular "lollipop" lesion. Broad mantle zone. (Hematoxylin and eosin stain, x400).

## Discussion

Castleman disease is an uncommon, lymphoproliferative disorder the prevalence of which is still unknown due to insufficient data, however it is estimated that approximately 1 in 100,000 population is diagnosed with CD every year in USA.<sup>2</sup> The etiology of the disease is still unclear. Theories such as lymphoma, inflammatory origin, or autoimmune disease have been proposed. CD is a heterogeneous group of non-neoplastic lymphoproliferative disorders that can be clinically classified into localized or unicentric and disseminated or multicentric. It can also be classified as hyaline vascular (HV) type which comprises up to 90% of cases in UCD, plasma cell (PC) type or mixed type on histological basis.<sup>5,6,7</sup>

Unicentric accounts for most of CD cases and found predominantly in women (1.4:1). The median age at presentation for UCD is 30-34 years.<sup>8</sup> Although unicentric CD is considered a benign condition, surgical resection is always recommended because of the possibility of mass affecting adjacent structures.<sup>7</sup> Unicentric form of CD is usually asymptomatic that involves a single

region of lymph nodes; mainly in intra-abdominal, axillary, mediastinal, cervical or inguinal nodes.<sup>4</sup> The usual signs and symptoms of the unicentric form include fullness in the chest or abdomen, fever, anemia, fatigue, weight loss, sweating, and skin rashes.<sup>9</sup> However, in this case, the patient showed an enlarged lymph node in the right supra-clavicle region associated with a mild pain which is a rare presentation. Further laboratory investigations showed increased levels of AST and ALT which is not related to the Castleman disease. CT scan and USG findings showed a well-encapsulated solid mass with no significant cervical lymphadenopathy suggesting lymphoma. There are various unusual sites of presentation like peripancreatic<sup>10</sup> and retroperitoneal<sup>11</sup>, mesocolon<sup>12</sup> and infraclavicular region.<sup>9</sup> This site of supraclavicular area is probably the first case report to be presented.

As in any neck mass, radiological investigations were done. Both lymphoma and neurogenic tumor were considered because they are common in this site. A reactive lymphadenopathy was seen in FNAC slides. There was no evidence of lymphoma in FNAC. However FNAC cannot reliably distinguished Castleman disease from other lymphadenopathies such as HIV-

associated lymphadenopathy, Dermatopathy lymphadenopathy, and progressively transformed germinal center. Thus, histopathological examination was required to confirm the diagnosis of Castleman Disease. Grossly, CD in our case appeared as encapsulated homogenous mass with a grey-white color.<sup>10</sup> Histopathological examination showed a well-encapsulated lymph node tissue with an expanded mantle zone (paler areas), regressed follicles with radially penetrating sclerotic blood vessels (lollipop-like appearance). Moreover, In cases of HV variant Castleman disease like changes can be seen in non-Hodgkin lymphoma and Hodgkin lymphoma. However there were no morphological evidence for Hodgkin lymphoma, non-Hodgkin lymphoma especially Mantle cell lymphoma and follicular lymphoma; as our case morphologically did not have high mitotic rate or any diffuse or nodular pattern of growth for suspicion for mantle cell lymphoma.<sup>5,13</sup> HHV 8 association is generally for MCD. Histopathological examination ruled out lymphoma and concluded that it is a Unicentric Castleman disease, hyaline-vascular type case. There were no atypical proliferation of dendritic cells. Negative strength for this case report was that no Immunohistochemistry (IHC) was performed. Furthermore, the other lymph nodes were not clinically significant, and there was no recurrent swelling at six month follow up and the patient was fine.

### Conclusion

Castleman disease is a rare and poorly understood disease due to its low incidence. Although it involves and represented in various lymph node regions, the supraclavicular region is one of the least common region for UCD. Literature review showed no case reports or studies in UAE. The unusual presentation of this case in form of age, gender and site of presentation warrants further studies with large data as and when it arises for this geographic region. As FNAC would be one of the first line of investigation, Pathologist interpreting the FNAC in such case scenarios should not be biased by the clinical and radiological differentials and interpret as per the cytomorphology. Histopathological examination will be confirmatory and avoids further unnecessary investigations burdening the health system. This case report highlights the fact that Castleman's Disease can be in unusual sites including the supraclavicular fossa which should be included in the clinical differential diagnosis of neck mass.

*Acknowledgement:* We thank Dr. Mohamed Sobhy at Thumbay Hospital for assistance in evaluation of this patient. Patient consent was obtained for publication of this report.

*Conflict of Interest:* None

### References

1. Chronowski GM, Ha CS, Wilder RB, Cabanillas F, Manning J, Cox JD. Treatment of unicentric and multicentric Castleman disease and the role of radiotherapy. *Cancer*. 2001;92(3):670-6.
2. Reddy R, Singhania A, George A, Kumar R, Kumar S. Castleman's Disease, a Case report. *Iran J Otorhinolaryngol*. 2011;23(65):157-160.
3. Iyer S, Bhatti MI, Halliday M. Castleman's disease-A case report. *Int J Surg Case Rep*. 2010;1(3):25-6.
4. Radhakrishnan N, Besa EC. Castleman Disease. *Medscape*. 2018 Feb 1.
5. Sevilla-Lizcano DB, Frias-Soria CL, Ortiz-Hidalgo C. Castleman disease. Histopathological and immunohistochemical analysis of 39 cases. *Gac Med Mex*. 2017;153(5):550-558.
6. Ren N, Ding L, Jia E, Xue J. Recurrence in unicentric castleman's disease postoperatively: a case report and literature review. *BMC Surg*. 2018 Jan 4;18(1):1.
7. Garcia KM, Rodriguez Rivera AM. Unicentric Castleman's Disease: Case Report and Literature Review. *Cancer therapy & Oncology International Journal*. 2018 Mar 23;9(5):555775.
8. Juárez Salcedo LM, Dalia S. Castleman's disease. *Atlas Genet Cytogenet Oncol Haematol*. 2018;22(3):101-103.
9. Salooja MS, Mukherjee KC, Khetrpal H, et al. Castleman's disease: A rare case report of unicentric type in a young female. *Saudi Surgical Journal*. 2016 Feb 1;3(2):39-42.
10. Abdessayed N, Bdioui A, Ammar H, Gupta R, Mhamdi N, Guerfela M, Mokni M. Retroperitoneal unicentric Castleman's disease: A case report. *Int J Surg Case Rep*. 2017;31:54-57.
11. Murata M, Nagano O, Hasegawa G, et al. Unicentric Castleman's disease located between the aorta and inferior vena cava: A case report. *SAGE Open Med Cas Rep*. 2019 Apr 3;7.
12. Boovalli MM, Raju K, Venkataramappa SM. Castleman's disease of the mesocolon: a rare case report. *Biomedical Research and Therapy*. 2014;1:1-5.
13. Swerdlow SH, Campo E, Harris NL, Jaffe ES, Pileri SA, Stein H, et al. *Who Classification of Tumours of Haematopoietic and Lymphoid Tissues*. Revised 4th edition. France: International Agency for Research on Cancer (IARC); 2017.

