

# Clinicopathological Profile of Salivary Gland Tumors in A Tertiary Care Center: A Long-term Experience

Krishna Sumanth Thota<sup>1</sup>, Dinesh BV<sup>2</sup>

**Author's Affiliation:** <sup>1</sup>Assistant Professor, Department of Urology, NRI Medical College, Chinakakani, Guntur, Andhra Pradesh 522503, India. <sup>2</sup>Associate Professor and Unit Chief, Department of General Surgery, Kasturba Medical College, Manipal, Karnataka 576104, India.

## How to cite this article:

Krishna Sumanth Thota, Dinesh BV. Clinicopathological Profile of Salivary Gland Tumors in A Tertiary Care Center: A Long-term Experience. *New Indian J Surg.* 2020;11(1):9–16.

## Abstract

The most common benign neoplasm of the salivary glands is pleomorphic adenoma originating from the parotid gland. Surgical excision is usually all that is required to provide both definitive diagnosis and adequate treatment. Despite this relatively simple algorithm, management of salivary neoplasms is challenging because of their relative infrequency, inconsistent classification, and variable biologic behavior. Although many studies regarding the incidence of salivary gland tumors have been reported, the epidemiology of these neoplasms is not well established because these studies are frequently restricted to a specific population, anatomical location, or a specific tumor type.

There are numerous studies on the incidence and histological types of salivary gland tumors from countries in the western world and African countries. However, there is little available information about the pattern of their presentation from Asian countries. The aim of this study was to analyze the incidence and distribution of all types of salivary gland tumors in an Indian series, and to provide data for comparison with other epidemiological studies from different geographical sites and races. Demographic data from these studies should help us

to a better understanding of the biological and clinical characteristics of the disease.

**Keywords:** Salivary gland; Parotid gland; Pleomorphic adenoma; Warthin's tumor; Submandibular sublingual salivary gland; Minor salivary gland.

## Introduction

Salivary glands stand out as the tissue with probably the most diverse pathology in human body. Salivary gland tumors consist of a group of heterogeneous lesions with complex clinicopathological characteristics and distinct biological behavior. The WHO salivary gland tumor classification lists at least 34 subtypes of epithelial tumors alone, as well as several stromal types. Regardless of this, Salivary gland neoplasms are rare and constitute 3% to 4% of head and neck neoplasms. According to the World Health Organization (WHO), the global annual incidence, when all SGTs are considered, varies from 0.4 to 13.5 cases per 1,00,000 inhabitants.

Better understanding of the histogenesis of neoplasms of the salivary glands has allowed a more consistent and rational classification of these tumors. Recent advances in molecular biology and tumor genomics have shed some light on the genetic basis of certain types of tumors of the salivary glands. The role of fine-needle aspiration biopsy and high-resolution imaging in the management of patients with salivary neoplasms continues to evolve. Spiro<sup>1</sup> reviewed the Memorial Sloan-Kettering experience

---

**Corresponding Author:** Dinesh BV, Associate Professor and Unit Chief, Department of General Surgery, Kasturba Medical College, Manipal, Karnataka 576104, India.

E-mail: [dinims2005@rediffmail.com](mailto:dinims2005@rediffmail.com)

Received on 26.12.2019, Accepted on 09.01.2020

with salivary neoplasms over a 35-year period. Out of 2807 patients included in study benign neoplasms constituted 54% (1529 patients) of all tumors. Pleomorphic adenoma (1280 patients) constituted 84% of benign tumors and 45% of all salivary gland neoplasms. Warthin's tumor was the second most benign tumor and comprised 12% (183 patients) of all benign tumors. Among malignant tumors 34% were mucoepidermoid carcinoma, the next most common type was adenoid cystic carcinoma (22%).

Two theories of tumorigenesis have been proposed for salivary gland neoplasms.<sup>2</sup> (e.g. multicellular theory and Bicellular reserve cell theory). In the Multicellular theory, each type of neoplasm is thought to originate from a distinctive cell type within the salivary gland unit. According to this theory, Warthin's and oncocytic tumors are thought to arise from striated ductal cells, acinic cell tumors from acinar cells, and mixed tumors from intercalated duct and myoepithelial cells.<sup>3</sup>

The Bicellular reserve cell theory, assumes that the origin of the various types of salivary neoplasms can be traced to the basal cells of either the excretory or the intercalated duct. Hence despite the seeming heterogeneity of salivary tumors, all of them are thought to arise from one of two pluripotential cell populations. In this model, adenomatoid tumors including pleomorphic adenoma and oncocytic tumors are derived from the reserve cell of the intercalated duct, whereas epidermoid tumors, such as squamous cell carcinoma and mucoepidermoid carcinomas, are derived from the reserve cell of the excretory duct. Malignant neoplasms of the major and minor salivary glands are rare, comprising approximately 3% of all head and neck malignancies.<sup>1</sup> Of all salivary neoplasms (benign and malignant), the vast majority occurs in the parotid gland and the fewest in the sublingual gland. In a review of 2410 cases of salivary gland tumors<sup>4</sup> 73% occurred in the parotid, and of those, only 15% were malignant. On the other hand, minor salivary gland tumors constituted only 14% of the total number of cases but 46% were malignant. Likewise, submandibular gland neoplasms constituted 11% of the cases with 37% being malignant; sublingual gland neoplasms constituted only 0.3% with 86% being malignant.

Tumor grade has been associated with prognosis for certain histologic types. When referring to histologic grade, high-grade malignant tumors are considered to include squamous cell carcinoma, undifferentiated carcinoma, high-grade mucoepidermoid carcinoma, and carcinoma ex-pleomorphic adenoma.<sup>5</sup> Low-

grade malignancies include acinic cell carcinoma, low-grade mucoepidermoid carcinoma, low-grade adenocarcinoma (including basal cell and mucinous adenocarcinoma), and papillary cystadenocarcinoma. Intermediate grade malignancies include adenoid cystic carcinoma and epithelial-myoeplithelial carcinoma.

## Materials and Methods

Ours is an observational, prospective and retrospective cohort study conducted at a single center. It is a study of clinicopathological profile of salivary gland tumors, done over a period of 7 years between January 2012 and December 2018 at Kasturba hospital, Manipal, Karnataka, India, a tertiary care teaching hospital. The sample size was 135 cases. Hospital is located in the southern part of India, which is completely ethnically Indian. The study sample is therefore thought to be representative of the Indian population as a whole with a minimal bias. Salivary gland neoplasms which were histopathologically proven by either definitive surgery or biopsy were included in this study. Patients who underwent only FNAC and no further histopathological diagnosis were excluded.

## Statistical Analysis

Study was analyzed using SPSS statistics software.<sup>21</sup>

## Results

Out of 135 cases 96 were benign and 39 were malignant. The peak age of incidence was in the 5<sup>th</sup> decade in both males and females and also for both benign and malignant tumors.

Benign tumors were most commonly seen in 3<sup>rd</sup>, 4<sup>th</sup> and 5<sup>th</sup> decades. Malignant tumors were most commonly seen in 5<sup>th</sup>, 6<sup>th</sup> and 7<sup>th</sup> decades.

Youngest was 11-year-old. Oldest was 80 years. Mean age of benign tumors was 44.40 years and malignant tumors was 48.43 years. Males were affected relatively at an older age than females in both benign and malignant disease. Among 135 cases 77 (57.04%) were male patients and 58 (42.96%) were female patients. Among 96 benign cases 55 (57.29%) were males and 41 (42.71%) were females. Among 39 malignant cases 22 (56.41%) were males and 17 (43.59%) were females. Males were more commonly affected in both benign and malignant tumors. Among 31 cases of malignant parotid tumors 6 (19.35%) cases presented with facial

nerve palsy. No case of benign tumor presented with facial nerve palsy. Total 13 cases presented with recurrent disease. 9 (9.4%) cases were benign tumors out of which 8 were pleomorphic adenoma and 1 Warthin's tumor. Remaining 4 (10.2%) were malignant tumors.

Various incidence and distribution of benign and malignant tumors in all salivary glands are shown in Table 1. Among 39 of the malignant cases, 2 cases had synchronous tumors involving parotid and submandibular glands and 1 case had synchronous tumor involving parotid and minor salivary gland. Among 110 cases of parotid involvement, only 3 (2.7%) cases showed tumor confined to deep lobe out of which 2 were benign and 1 malignant neoplasm. 4 (3.7%) cases showed tumor involving both lobes, 2 in each group of benign and malignant tumors. Benign were more common in parotid glands which constituted 71.8% when compared to 28.2% of malignant. 66.7% were benign and 33.3% were malignant in submandibular gland tumors. The incidence of malignant tumors was proportionately higher in submandibular gland than in parotid gland. Only one tumor was found in sublingual gland which was malignant. Among minor salivary glands, palate was the most common site of involvement. Benign tumors constituted 58.3% of minor salivary glands and 41.7% are malignant.

Out of 12 minor salivary gland tumors, 8 were seen in palate, 2 in buccal mucosa, 1 in lateral border of tongue and 1 in nasopharynx.

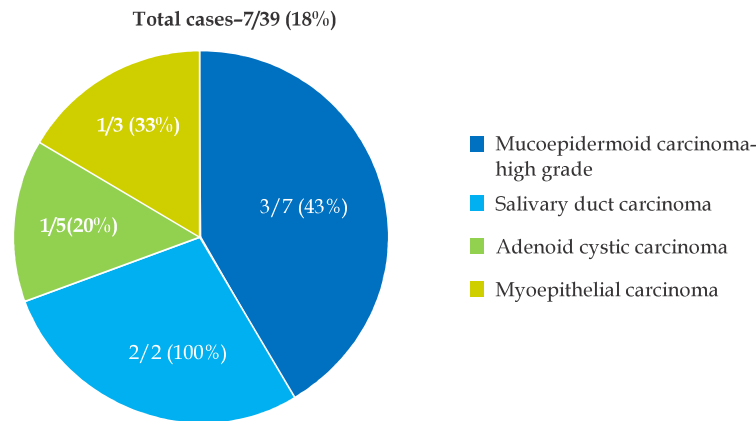
**Table 1:** Distribution of benign and malignant tumors among salivary glands

	Benign n (%)	Malignant n (%)	Total n (%)
Parotid gland	79 (71.8)	31 (28.2)	110 (79.7)
Submandibular gland	10 (66.7)	5 (33.3)	15 (10.9)
Sublingual gland	0	1 (100)	1 (0.7)
Minor salivary gland	7 (58.3)	5 (41.7)	12 (8.7)

Nine out of 39 cases of malignancies presented with lymph node metastasis.

Two (100%) out of 2 cases of salivary duct carcinoma, 4 (57%) out of 7 cases of high-grade mucoepidermoid carcinoma, 1(33%) out of 3 cases of intermediate grade mucoepidermoid carcinoma, 1 (33%) out of 3 cases of carcinoma ex-pleomorphic adenoma and 1 (20%) out of 5 cases of Adenoid cystic carcinoma presented with lymph node metastasis.

Seven out of 39 cases of malignancy presented with distant metastasis (Fig. 1).



**Fig. 1:** Showing incidence of distant metastasis.

Two (100%) out of 2 cases of salivary duct carcinoma, 3 (43%) out of 7 cases of high-grade mucoepidermoid carcinoma, 1 (33%) out of 3 cases of myoepithelial carcinoma and 1 (20%) out of 5 cases of Adenoid cystic carcinoma presented with distant metastasis. Most common site for metastasis was skeletal followed by lungs and liver. 3 cases had metastasis to bone, 1 case to lungs, 1 case to pleura, 1 case to liver and 1 case had metastasis to both liver and bone.

**FNAC**

Out of 135 cases 110 cases underwent FNAC. 7 were inadequate for opinion.

Total 103 cases were taken into account shown in Table 2. Among these FNAC correlated with final histopathology report in 91 patients. Out of 80 cases of benign tumors who underwent FNAC 5 were misdiagnosed and among 23 cases of malignant tumors 7 were misdiagnosed.

**Table 2:** Percentage of FNAC that correlated with final biopsy

	True positive	False negative	FNAC don
Benign	75 (93.7%)	5 (6.3%)	80
Malignant	16 (70%)	7 (30%)	23
<b>Total</b>	<b>91 (88.3%)</b>	<b>12 (11.7%)</b>	<b>103</b>

Among 5 misdiagnosed cases of benign tumors, 3 cases were Warthin's tumors and 2 cases were basal cell adenomas. Among malignant tumors 7 cases were misdiagnosed as either benign tumors or no evidence of malignancy. All 3 cases of carcinoma ex-pleomorphic adenoma were misdiagnosed as pleomorphic adenoma.

FNAC: malignant tumors

- Sensitivity 69.5%
- Specificity 93.7% in diagnosing malignant tumors
- Positive predictive value – 76.2%
- Negative predictive value – 91.5%

Twenty-five cases didn't undergo FNAC. Of these 6 cases underwent excision biopsy, 2 cases underwent incision biopsy, 1 case underwent trucut biopsy, 1 case underwent lymph node biopsy. 3 cases were recurrent cases and FNAC was not done, all of them were benign neoplasms. 6 cases were operated outside and no FNAC report was available, all of them were malignant. 6 cases were operated without tissue diagnosis, 4 were benign and 2 were malignant neoplasms.

### *Surgery*

Patients with parotid gland tumors underwent 5 types of surgeries

- Superficial parotidectomy
- Partial parotidectomy
- Total parotidectomy
- Radical parotidectomy
- Extended parotidectomy

Patients with benign tumors in tail of parotid underwent partial parotidectomy. Out of 110 cases of parotid tumors, 109 were operated and 1 patient underwent biopsy followed by radiotherapy. Total 6 cases had involvement of facial nerve during surgery of which 4 underwent radical parotidectomy and 2 underwent extended parotidectomy. Patients with benign submandibular tumors underwent excision of the gland and those with malignancy spreading outside the gland underwent wide local excision.

Patient with sublingual adenoid cystic carcinoma underwent hemimandibulectomy because of infiltration in to mandible, along with wide local excision and Supraomohyoid neck dissection (SOHND). Similarly patients with minor salivary gland tumors underwent excision of tumor with a rim of normal tissue in benign cases and wide local excision in malignant cases. Among parotid malignancies 5 underwent SOHND and 7 underwent modified radical neck dissection (MRND). In submandibular malignancy one each underwent SOHND and MRND.

### *Postoperative Complications*

Immediate postop exploration for hematoma clearance was done in 2 (2.4%) cases of superficial parotidectomy. Both were cases of pleomorphic adenoma. Facial paresis was seen in 21 (25.6%) out of 82 superficial parotidectomies and 5 (45.45%) out of 11 total conservative parotidectomies. Permanent postop facial paralysis developed in 1 (9%) patient who underwent total parotidectomy. He underwent gold weigh implantation.

In 6 patients facial nerve was sacrificed intraop because of tumor involvement. Four of them had lateral tarsorrhaphy done followed by physiotherapy. Two patients underwent gold weight implants. Postop seroma collection which required aspiration was seen in 8 (9.75%) cases who underwent superficial parotidectomy. Cutaneous fistula formation was noticed in 3 cases who underwent superficial parotidectomy, 2 of which were done for recurrent pleomorphic adenomas. They were managed with regular pressure dressings and wound care and they finally healed. 5 (6.09%) cases who underwent superficial parotidectomy had Frey syndrome. They were treated with local application of antiperspirants.

### *Histopathological Type*

The incidence of benign tumors was higher than malignant tumors with 71.1% and 28.9% respectively. Pleomorphic adenoma constituted 58.5% of all tumors, Warthin's tumor 8.9% and mucoepidermoid carcinoma 14.8%. Only 1 tumor was identified in sublingual gland which was malignant tumor. Distribution of benign and malignant tumors were shown in Tables 3 and 4 respectively. Mucoepidermoid carcinoma was the most common malignant neoplasm accounting for 51.3% followed by adenoid cystic carcinoma (12.8%). Mucoepidermoid carcinoma was the commonest malignant tumor in both major and minor salivary

**Table 3:** Distribution of benign tumors in different salivary glands

	Parotid gland (n)	Submandibular gland (n)	Minor salivary gland (n)	Total (n)
Pleomorphic adenoma	62 (78.5%)	10 (100%)	7 (100%)	79 (82.3%)
Warthin's tumor	12 (15%)	0	0	12 (12.5%)
Basal cell adenoma	5 (6.5%)	0	0	5 (5.2%)

glands. Adenoid cystic carcinoma is the second most common tumor. In minor salivary glands only mucoepidermoid carcinoma and adenoid cystic

carcinoma were encountered. Only one tumor was identified in sublingual gland which was adenoid cystic carcinoma.

**Table 4:** Distribution of malignancies among different salivary glands

Malignant tumors	Parotid	Submandibular	Sublingual	Minor salivary	Total cases
Mucoepidermoid Ca	16	2	0	4	20 (51.3%)
Adenoid cystic Ca	2	1	1	1	5 (12.8%)
Acinic cell Ca	3	0	0	0	3 (7.7%)
Ca ex-pleomorphic	2	1	0	0	3 (7.7%)
Myoepithelial Ca	3	1	0	0	3 (7.7%)
Salivary duct Ca	2	0	0	0	2 (5.1%)
Basal cell adeno Ca	1	0	0	0	1 (2.6%)
Oncocytic Ca	1	0	0	0	1 (2.6%)
Secondaries	1	0	0	0	1 (2.6%)

### *Synchronous Malignant Tumors*

There were 3 synchronous malignant tumors.

1. Synchronous mucoepidermoid carcinoma of left parotid and submandibular glands.
2. Synchronous mucoepidermoid carcinoma of left parotid and right lateral border of tongue.
3. Synchronous myoepithelial carcinoma of right parotid and submandibular glands.

There was one case of secondaries in parotid with primary from oncocytic meningioma. This patient presented with secondaries after 4 years of surgery to primary site. He underwent superficial parotidectomy, but he did not follow-up later.

### *Radiotherapy*

Out of 39 cases of malignancies, 28 cases received radiotherapy. Radiotherapy was given in a dose of 60Gy in 30 fractions over a period of 6 weeks. 66Gy in 33 fractions was given in salivary duct carcinomas and in high-grade mucoepidermoid carcinomas. Postop radiotherapy was indicated for all cases of malignant tumors except low-grade mucoepidermoid carcinomas. Close follow-up was advised for patients with low-grade mucoepidermoid carcinomas, except 2 cases who received radiotherapy in view of extraglandular spread. Two cases of high-grade mucoepidermoid carcinoma and 1 case of acinic cell carcinoma didn't come for follow-up.

### *Chemotherapy*

Cisplatin was given in weekly doses over 6 weeks in 6 out of 39 cases. Three cases who came with distant metastases, 1 case of high-grade mucoepidermoid carcinoma in tongue and 2 cases of salivary ductal carcinoma received chemotherapy.

### *Follow-up*

Out of 96 cases of benign tumors, 57 cases didn't come for follow-up. 39 cases were followed up for a period of 1 or more months. Average period of followup was 5 months. There were no recurrences noted. Out of 39 cases of malignant tumors, 36 cases returned for follow-up for 1 or more months. Average period of follow-up was 14 months. 4 cases had local recurrence. Six cases presented with distant metastases. One case presented with both local recurrence and distant metastases. Two patients died during hospital stay because of pulmonary complications following secondaries of lung.

### *Discussion*

Salivary gland tumors are a large and diverse group of lesions, characterized by morphologic heterogeneity. There are numerous epidemiologic studies of salivary gland tumors in different countries, with varied results likely representing differences in the origin of study, divergences in

the histologic classification, restriction to a specific population, anatomical location, or tumor type. Most commonly involved salivary gland was parotid for both benign and malignant tumors. Parotid glands accounted for 79.7% of all cases which was similar with study published by Patrick J Bradley<sup>6</sup> in UK in 2012. Submandibular gland tumors accounted for 15% which was similar to study by Subhashraj K in India. Sublingual glands were involved in 0.7% of cases similar to other studies.<sup>6-8</sup> Minor salivary gland tumors were involved in 8.7% of cases similar to other studies.<sup>6,9</sup> Among minor salivary glands palate was the most common site of involvement for both benign and malignant tumors which was similar to other studies.<sup>1,4</sup> In parotid glands 71.8% were benign tumors and 28.2% were malignant, in submandibular glands 66.7% were benign and 33.3% were malignant, in sublingual glands only one tumor was identified which was malignant and in minor salivary glands 58.3% were benign and 41.7% were malignant.

Among parotid gland tumors, superficial lobe was most commonly affected and tumors involving only deep lobe were rare. Among 110 cases of parotid involvement, only 3 cases showed tumor confined to deep lobe, 4 cases showed tumor involving both lobes. Out of 12 minor salivary gland tumors, 8 were seen in palate, 2 in buccal mucosa, 1 in lateral border of tongue and 1 in nasopharynx. Lymph node metastasis was most commonly seen in salivary duct carcinoma (100%), followed by high-grade mucoepidermoid carcinoma (57%). Lymph node metastasis was not seen in low-grade mucoepidermoid carcinoma, acinic cell carcinoma, myoepithelial carcinoma.

High-grade nature of salivary duct carcinoma was shown in one study<sup>10</sup> which stated, salivary duct carcinoma is the most aggressive salivary gland carcinoma with 30% to 40% of patients developing local recurrence and between 50% and 75% developing distant metastases and dying of their disease, most within 4 years of diagnosis. Less incidence of lymph node metastasis in low-grade mucoepidermoid carcinoma and acinic cell carcinoma was shown in other studies.<sup>11,12</sup> Distant metastasis also showed the same trend of lymph node metastasis which was most commonly seen in salivary duct carcinoma (100%), followed by high-grade mucoepidermoid carcinoma (43%). Distant metastasis was not seen in low and intermediate grades of mucoepidermoid carcinoma and acinic cell carcinoma. This was similar to other studies.<sup>10,12</sup> The most common site for metastasis in this study was skeletal followed by lungs and liver.

In our study the accuracy of FNAC in detecting benign tumors was 93.7% and that of malignant tumors was 70%. The overall accuracy was 88.34%. The accuracy of detecting salivary gland tumors was high in benign tumors when compared to malignant tumors.

Positive predictive value and negative predictive value of detecting malignant tumors were 76.2% and 91.5% respectively. This was comparable with study by Singh Nanda and colleagues.<sup>13</sup> All 3 (100%) cases of carcinoma ex-pleomorphic adenoma were misdiagnosed as benign on FNAC. 3 (20%) cases of Warthin's tumors were misdiagnosed as chronic sialadenitis. Total 7 (6.36%) samples were reported as inadequate for opinion.

Pleomorphic adenoma constituted 58.5% of all tumors and 82.3% of all benign tumors. Pleomorphic adenoma was the most common benign tumor among both major and minor salivary glands.<sup>1</sup> Warthin's tumor was the second most common benign salivary gland tumor<sup>4,6,8</sup> accounting for 8.9% of all tumors and 12.5% of benign tumors.

Among malignancies mucoepidermoid carcinoma was the most common tumor<sup>1</sup> constituting 14.8% of all tumors and 51% of malignancies. Mucoepidermoid carcinoma was graded in to low, intermediate and high-grades. 50% of cases were low-grade and remaining were intermediate and high-grade. 57% of high-grade mucoepidermoid carcinomas were associated with lymph node metastasis and 43% with distant metastasis.

Second common malignancy was adenoid cystic carcinoma<sup>6,7,9</sup> with 12.8% followed by carcinoma ex-pleomorphic adenoma (7.7%), acinic cell carcinoma (7.7%), myoepithelial carcinoma (7.7%), salivary duct carcinoma (5.1%), basal cell adenocarcinoma (2.6%), oncocytic carcinoma (2.6%), secondaries to parotid (2.6%). In minor salivary glands only mucoepidermoid carcinoma and adenoid cystic carcinoma were encountered. Only one tumor was identified in sublingual gland which was adenoid cystic carcinoma. Two cases of salivary duct carcinoma were identified both of which had lymph nodal and distant metastasis. Both the cases had local recurrence following surgery and radiotherapy. One patient died during hospital stay because of lung metastasis. It is the most aggressive salivary gland carcinoma with high chances of developing local recurrence and distant metastases and dying of their disease, mostly within 4 years of diagnosis.<sup>14</sup>

Facial paresis was seen in 25.6% cases of superficial parotidectomies and 45.45% of total conservative parotidectomies. Permanent postop facial paralysis developed in 1 (9%) patient who underwent total parotidectomy. In a study of 256 consecutive patients who underwent parotid surgery at the Cleveland Clinic over a period of 15 years, immediate postoperative facial nerve dysfunction was frequently encountered (46%), but permanent dysfunction was uncommon (4%).<sup>15</sup> These statistics were similar to our study.

All cases of salivary duct carcinoma, adenoid cystic carcinoma, myoepithelial carcinoma, carcinoma ex-pleomorphic adenoma, high and intermediate grade carcinoma received radiotherapy. In a recent multivariate analysis of 140 patients with Adenoid cystic carcinoma, Chen and colleagues<sup>16</sup> observed that the omission of postoperative radiation therapy was an independent predictor of local recurrence with a hazard ratio of 5.82. A retrospective multivariate analysis of 103 parotid gland carcinoma patients by Renehan and colleagues<sup>17</sup> found that the addition of postoperative radiation significantly reduced locoregional recurrence (15%) compared with surgery alone (43%) at 10 years and that this improved survival was seen mainly in patients with high-grade tumors. Chemotherapy was given to cases who came with recurrent local or distant disease and in cases who had salivary duct carcinoma.

## Conclusion

The peak age of incidence of both benign and malignant salivary gland tumors was 5<sup>th</sup> decade of life. Males were more frequently affected than females in both benign and malignant tumors. Twenty percent of cases with malignancy presented with facial nerve palsy. Pleomorphic adenoma was the most common benign tumor followed by Warthin's tumor. Warthin's tumor was confined to parotid glands and showed bilateral disease and multicentricity. Mucoepidermoid carcinoma was the most common malignant tumor followed by adenoid cystic carcinoma in both major and minor salivary gland tumors. Among minor salivary glands, palate was the most common site of involvement for both benign and malignant tumors. A correct diagnosis was obtained using FNAC in 93.7% benign tumors and in 70% malignant tumors. Facial nerve paresis was the most common complication following parotid surgery followed by salivary fistula and Frey's syndrome. Patients who underwent partial parotidectomy had least incidence of complications.

Radiotherapy was indicated in all cases of malignancy except low-grade mucoepidermoid carcinomas which were closely followed up.

## Ethical Clearance

Ethical clearance taken from the Institutional ethics committee.

## References

1. Spiro RH. Salivary neoplasms: Overview of a 35-year experience with 2,807 patients. *Head Neck Surg* 1986 Jan-Feb;8(3):177-84.
2. Levin RJ, Bradley MK. Neuroectodermal antigens persist in benign and malignant salivary gland tumor cultures. *Arch Otolaryngol Head Neck Surg* 1996 May;122(5):551-57.
3. Dardick I. Mounting evidence against current histogenetic concepts for salivary gland tumorigenesis. *Eur J Morphol* 1998 Aug;36 Suppl:257-61.
4. Eveson JW, Cawson RA. Salivary gland tumors. A review of 2410 cases with particular reference to histological types, site, age and sex distribution. *J Pathol* 1985 May;146(1):51-58.
5. Spiro RH, Armstrong J, Harrison L, et al. Carcinoma of major salivary glands. Recent trends. *Arch Otolaryngol Head Neck Surg* 1989;115:316-21.
6. Patrick J, Bradley, Mark Mc Gurk. Incidence of salivary gland neoplasms in a defined UK population. *Br J Oral Maxillofac Surg* 2013;51(5):399-03.
7. Subhashraj K. Salivary gland tumors: A single institution experience in India. *Br J Oral Maxillofac Surg* 2008;46(8):635-38.
8. Luksic I, Virag M, Manoilovic S, Macan D. Salivary gland tumors: 25 years of experience from a single institution in Croatia. *J Craniomaxillofac Surg* 2012 Apr;40(3):e75-81.
9. Ansari MH. Salivary gland tumors in an Iranian population: a retrospective study of 130 cases. *J Oral Maxillofac Surg* 2007 Nov;65(11):2187-94.
10. Lewis JE, McKinney BC, Weiland LH, et al. Salivary duct carcinoma. Clinicopathologic and immunohistochemical review of 26 cases. *Cancer* 1996 Jan 15;77(2):223-30.
11. Brandwein MS, Ivanov K, Wallace DI, et al. Mucoepidermoid carcinoma: a clinicopathologic study of 80 patients with special reference to histological grading. *Am J Surg Pathol* 2001 Jul;25(7):835-45.
12. Lewis JE, Olsen KD, Weiland LH. Acinic cell carcinoma. Clinicopathologic review. *Cancer* 1991 Jan 1;67(1):172-179.

13. Singh Nanda KD, Mehta A, Nanda J. FNAC in salivary gland tumors. *J Oral PatholMed* 2012;41(1):106-12.
14. Jaehne M, Roeser K, Jaekel T, et al. Clinical and immunohistologic typing of salivary duct carcinoma: a report of 50 cases. *Cancer* 2005 Jun 15;103(12):2526-33.
15. Mehle ME, Kraus DH, Wood BG, et al. Facial nerve morbidity following parotid surgery for benign disease: The Cleveland Clinic Foundation experience. *Laryngoscope* 1993 Apr;103(4 Pt 1):386-88.
16. Chen AM, Bucci MK, Weinberg V, et al. Adenoid cystic carcinoma of the head and neck treated by surgery with or without postoperative radiation therapy: Prognostic features of recurrence. *Int J Radiat Oncol Biol Phys* 2006 Sep 1;66(1):152-59.
17. Renehan AG, Gleave EN, Slevin NJ, et al. Clinicopathological and treatment-related factors influencing survival in parotid cancer. *Logo of Brjcancer. Br J Cancer* 1999 Jun; 80(8): 1296-1300.

