

Comparative Study of Ultrasound Guided PENG [Pericapsular Nerve Group] Block and FIB [Fascia Iliaca Block] for Positioning and Postoperative Analgesia Prior to Spinal Anaesthesia for Hip Surgeries: Prospective Randomized Comparative Clinical Study

K Shankar¹, Srinivasan Rangalakshmi², AB Ashwin³, Usha Nandini⁴, Mahesh Chandra⁵, Deepak Vijaykumar Kadlimatti⁶

^{1,5,6}Assistant Professor, ²Professor, ^{3,4}Post graduate, Dept. of Anaesthesiology, RajaRajeswari Medical College and Hospital, Bengaluru, Karnataka 560074, India.

Abstract

Introduction: Extreme pain in hip fractures does not allow ideal positioning for spinal anesthesia. Adequate pain relief before spinal anesthesia will enhance patient's cooperation. We evaluated the analgesic efficacy of ultrasound guided PENG block and FIB for positioning and post operative pain relief in hip surgeries. **Methods:** This was a prospective, randomized, double blind study that included 60 patients aged 18-80 years of either sex belonging to ASA I to III undergoing hip surgeries. Group P [n=30] [USG guided Peng Block] - 25ml of 0.25% Ropivacaine Group F [n=30] [USG guided Fascia Iliaca Block] - 25ml of 0.25% Ropivacaine. Pain scores after the block, during positioning and post-operative period, opioid consumption and side effects if any were recorded. Statistical analysis done using student t test, chi-square test. Pvalue of < 0.05 was considered significant. **Results:** In Group P, mean VAS before block was 7.8 ± 0.47 which reduced to 0.6 ± 0.4 during positioning which is statistically significant ($P < 0.001$), whereas in Group F, mean VAS before block was 7.6 ± 0.4 which reduced to 2.6 ± 1.2 during positioning. Duration of postoperative analgesia was comparable between the two groups. (490.4 ± 40.8 minutes in group P and 470 ± 40.48 minutes in group F) **Conclusion:** In Hip fractures, PENG block produces more effective analgesia for positioning and postoperative pain than Fascia iliaca block without any significant side effects.

Key words: Ultrasound, Pericapsular nerve group block, Fascia iliaca block, Hip surgeries

How to cite this article:

K Shankar, Srinivasan Rangalakshmi, AB Ashwin, et al. Comparative Study of Ultrasound Guided PENG [Pericapsular Nerve Group] Block and FIB [Fascia Iliaca Block] for Positioning and Postoperative Analgesia Prior to Spinal Anaesthesia for Hip Surgeries: Prospective Randomized Comparative Clinical Study. Indian J Anesth Analg. 2020;7(3):798-803.

Introduction:

Hip fractures are common orthopaedic problem especially in elderly population which is associated with significant morbidity and mortality¹. Early surgical reduction and fixation is the preferred treatment in most patients². Spinal anaesthesia is the most common mode of anaesthesia used to fix these fractures³. Extreme pain due to fracture does

not allow ideal positioning for these procedures⁴ and hence a problem to access the subarachnoid space. Inadequate postoperative analgesia can restrict the limb mobility thereby delaying recovery along with increased consumption of opioids. Effective perioperative analgesia that reduces the requirement of opioids and its adverse effects is essential in this population⁵. Lower extremity

Corresponding Author: Srinivasan Rangalakshmi, Professoor, Dept. of Anaesthesiology, RajaRajeswari Medical College and Hospital, Bengaluru, Karnataka 560074, India.

E-mail: : rangbharat@gmail.com

Received on 31.01.2020, **Accepted on** 29.02.2020

peripheral nerve blocks like femoral nerve (FN) block, fascia iliaca block (FIB), and 3-in-1 FN block are popular analgesic techniques mainly due to their opioid-sparing effects and reduction in opioid-related adverse effects⁶⁻⁸. Analgesia from these blocks is only moderate⁹, and literature suggests that the articular branches of these nerves are inconsistently blocked^{10,11}. The anterior hip capsule is innervated by articular branches of femoral nerve, obturator nerve and accessory obturator nerve (AON) as reported by previous anatomic studies, suggesting that these nerves should be the main targets for hip analgesia, which can be blocked by Peri-capsular nerve group (PENG) block¹²⁻¹⁷. Using this information, we conducted this study to evaluate the efficacy of Ultrasound guided PENG block for positioning & post-operative analgesia for hip surgeries in comparison with Ultrasound guided Fascia iliaca block.

Material and Methods

After conducting a pilot study, effect size (d) of 1.5 in VAS was obtained. Considering standard deviation of 2, power as 80%, alpha error of 0.05, 27 patients per group was obtained. To avoid study errors, attrition, sample size of 60 with 30 patients in each group was considered. Prospective randomized double blind comparative study was conducted after obtaining institutional ethical committee approval and informed written consent of the patients. 60 patients of either sex aged between 18-80 years with American Society of Anaesthesiologists (ASA) physical status I-III posted for elective surgery for hip fracture under spinal anaesthesia but unable to sit due to pain were included in the study. Patients who could sit comfortably, refusing to participate in the study, local anaesthetic allergy, coagulopathy, infection at the site of block, neurological deficits, on other analgesics upto 8 hrs before performing nerve block, neuropsychiatric disorders were excluded. Emergency resuscitation equipment and drugs, preparation for general anaesthesia and ultrasound equipment for the nerve block were kept ready. On arrival to the operation theatre an intravenous line was secured. Pain assessment was done using visual analog scale (0 = no pain, 10 = maximum pain). VAS score before performing the block was noted both at rest and during dynamic hip movement (Elevating the affected limb 15° above the table). The anaesthetist performing the block was not blinded to the procedure, the patient and assessor of visual analog scale were blinded to group allocation. Patients were randomly divided into two groups of 30 each using sealed opaque envelope method. Regional block was performed

with the patient in supine position. The site to be blocked was painted with 5% povidone iodine followed by 70% ethyl alcohol and draped. Linear high-frequency ultrasound probe (7 -15 mhz) was initially placed in a transverse plane over the anterior superior iliac spine (ASIS) and then aligned to identify the following landmarks:

Group P [Peng Block]- received Ropivacaine 0.25% 25ml. Landmarks included Anterior inferior iliac spine, ilio-pubic eminence, iliopsoas muscle and tendon, the femoral artery, and Pectineus muscle. Point of injection was musculofascial plane between the psoas tendon and ilio-pubic eminence.

Group F [Fascia Iliaca Block] - received Ropivacaine 0.25% 25ml. Landmarks included Internal oblique muscle, sartorius muscle, iliacus muscle and bone, fascia lata, fascia iliaca. Point of injection was between fascia iliaca and iliacus muscle.

VAS score before and 30 minutes after the block both at rest and during dynamic hip movement along with vital parameters-heart rate (HR), mean arterial pressure (MAP) by non-invasive blood pressure and oxygen saturation (SpO₂) were monitored. Because most patients with hip fracture are elderly, difficult spinal anaesthesia was anticipated, so after the block, all patients were positioned in sitting position for spinal anaesthesia and VAS score was noted at the time of positioning. If any patient of either group reported pain score of ≥ 4 during positioning, IV fentanyl 0.5microgram/kg was given every 5minute until the pain score is <4 or maximum dose of 3microgram/kg was given (whichever was earlier); patients who could not achieve pain score < 4 were excluded from the study. Quality of patient positioning was assessed by the anaesthetist giving spinal anaesthesia (0 = not satisfactory, 1 = satisfactory, 2 = good, 3 = optimal). Patient acceptance (yes/no) about positioning was noted. Spinal anaesthesia was given in sitting position in either midline/paramedian approach at the L3/4 or L4/5 level, with bupivacaine 0.5 % heavy 3ml (15mg) using 25G Quincke needle. Vital parameters was noted at regular intervals. Patient was shifted to post anaesthesia care unit (PACU) after the surgery. VAS scores were recorded at 0, 30min, 1hr, 4hr, 12 and 24 hrs along with vital parameters. Time of mobility was noted. Duration of analgesia was calculated from the time of giving the block till VAS score was ≥ 4 . Tramadol 1mg/kg IV was given as rescue analgesic if VAS ≥ 4 in postoperative period. Total consumption of tramadol in first 24 hrs was noted. Complications if any were documented and appropriately treated.

Statistical Methods

Student T test was used to compare nominal data. Chisquare test was used to compare categorical data. p value of ≤ 0.05 was considered significant. All the statistical analysis was done using SPSS software V 22.0.

Results

60 patients were included in the current study. The demographic data of both the groups are presented in Table 1. There was no statistically significant difference in both groups with respect to demographic characteristics

VAS score for pain before nerve block between Group P (7.8 ± 0.47) and Group F (7.6 ± 0.4) was comparable ($p = 0.9356$) (Table 2, Graph 1). VAS score 30minutes after performing the block at rest and during dynamic hip movement as well as during positioning before spinal anaesthesia

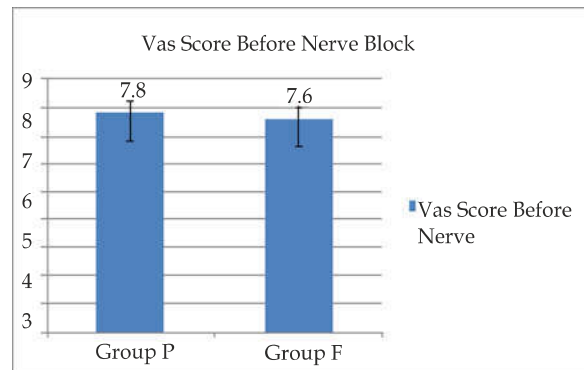
Table 1: Demographic characteristics

	Group P (n=30)	Group F (n=30)	p Value
Age(years)	53.58±19.95	49.54±21.61	0.4549
Weight(kg)	60.8±13.7	62.7±10.4	0.5475
Male	20	21	0.2344
Female	10	19	
ASA I	6	7	0.7399
II	19	20	
III	5	3	0.4458
Fracture neck of femur	11	7	
Inter trochanteric fracture	14	15	
Proximal femur fracture	5	8	0.4458

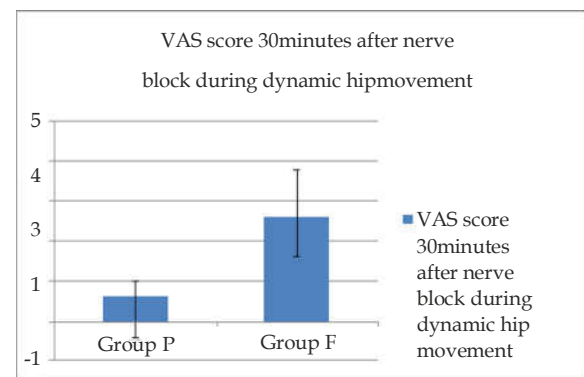
Table 2: VAS scores, mean reduction in pain

	Group P	Group F	p Value
VAS score before nerve block	7.8 ± 0.47	7.6 ± 0.4	0.9356
VAS score 30minutes after nerve block at rest	0.6 ± 0.4	2.6 ± 1.2	<0.001***
VAS score 30minutes after nerve block during dynamic hip movement	0.6 ± 0.4	2.6 ± 1.2	<0.001***
VAS score 30minutes after nerve block during positioning	0.6 ± 0.4	2.6 ± 1.2	<0.001***
Mean reduction in pain	7.2 ± 0.7	5 ± 0.8	<0.001***

was significantly less in Group P (0.6 ± 0.4) when compared to Group F (2.6 ± 1.2) (Table 2, Graph 2). Quality of patient positioning for spinal anaesthesia was higher in group P (2.348 ± 0.504) versus group F (1.754 ± 0.95) ($p = 0.003$) (Table 3). Patient acceptance was better in group P (27/3 versus 14/16) [Table 3]. No patient required additional doses of fentanyl in both the groups (Table 3).



Graph 1: VAS score before nerve block



Graph 2: VAS score 30minutes after block placement

Table 3: Quality of patient positioning, patient acceptance, additional fentanyl doses required

	Group P	Group F	p value
Quality of patient positioning	2.348 ± 0.504	1.754 ± 0.95	0.003***
Patient acceptance (yes/no)	27/3	14/16	
Additional fentanyl requirement	Nil	nil	

Haemodynamic variables i.e., heart rate, mean arterial pressure, SpO_2 were compared in both groups which is shown in Table 4.

Table 4: Vital parameters before nerve block and during positioning

Vital parameters	Group P	Group F	p value
Heart rate	76.88 ± 9.6	78.68 ± 9.5	0.4683
Baseline	76.08 ± 8.6	78.48 ± 8.4	0.2787
At positioning			
Mean arterial pressure	88.26 ± 5.5	85.8 ± 9.7	0.2318
Baseline	88.13 ± 5.9	84.5 ± 9.1	0.072
At positioning			
SpO2	97.21 ± 0.93	97.17 ± 1.17	0.892
Baseline	97.4 ± 0.4	97.1 ± 0.4	0.4750
At positioning			

Table 5: VAS score in postoperative period

Parameter	0min	30min	1hr	4hr	12hr	24hr
Group P	0.06 ± 0.24	1.45 ± 0.6	1.55 ± 0.69	2.46 ± 1.07	6.14 ± 0.95	6.3 ± 0.8
Group F	0.8 ± 0.27	1.7 ± 0.47	1.8 ± 0.41	2.16 ± 0.91	6.4 ± 1.01	6.5 ± 0.9
p value	0.4	0.52	0.572	0.23	0.18	0.25

Table 6: Duration of postoperative analgesia

Parameter	Group P	Group F	p value
Duration of postoperative analgesia	490 ± 40.8	470.8 ± 40.48	0.072

Table 7. Total analgesic in 1st 24 hrs, time to mobility, complications

Parameters	Group P	Group F	p value
Total analgesic required in 1 st 24hrs	0.8 +/- 0.38	0.9 +/- 0.35	0.2935
Time of mobility	Within 6hrs	Within 6hrs	
Complications	Nil	Nil	

There was no significant difference in VAS scores in postoperative period (Table 5).

There was no significant difference in duration of postoperative analgesia (Table 6). Total analgesic consumption in 1st 24hrs between group P and group F (Table 7).

All patients were mobilised within 6hrs after the surgery and no complications were noted in both the groups.

Discussion

Hip fractures are common orthopaedic problem following trauma in elderly patients¹. Early fixation of these fractures is essential to prevent fat embolism and other complications of hip fracture. Central neuraxial block such as spinal anaesthesia is commonly used for providing anaesthesia to repair these fractures³. This technique has many advantages over general anaesthesia like good pain relief, early mobility, decreased chances of deep vein thrombosis, reduced morbidity

and mortality¹⁸. Ideal positioning is one of the prerequisite for successful spinal anaesthesia. Severe pain associated with hip fractures can interfere with positioning for spinal anaesthesia and reduce the chances of successful subarachnoid block. Extreme pain following surgery can interfere with patient mobility with subsequent increase in consumption of intravenous analgesics and its related side effects. Moreover, patients with hip fractures usually are elderly and have multiple comorbidities, which precludes the use of systemic analgesics. Regional analgesic techniques like femoral nerve (FN) block, fascia iliaca block (FIB), and 3-in-1 FN block, are commonly used to reduce pain, increase patient comfort and increase success rate for performing subarachnoid block⁶⁻⁸. However, analgesia from these blocks is only moderate⁹, and literature suggests that the articular branches of these nerves are inconsistently blocked¹³⁻¹⁵. The anterior hip capsule is innervated by articular branches of femoral nerve, obturator nerve and

accessory obturator nerve (AON) as reported by previous anatomic studies which can be blocked by Peri-capsular nerve group (PENG) block.

Ropivacaine, a long acting local anaesthetic has reduced central nervous system and cardiac toxicity along with less propensity for motor blockade compared to bupivacaine, which enhances early mobilisation and prevents complications of immobility like atelectasis, pneumonia, deep vein thrombosis etc. This has made ropivacaine one of the commonly used local anaesthetic in peripheral nerve blockade¹⁹.

In 2018, Girón-Arango L et al., performed PENG block on 5 patients having hip fracture. Study showed that there was reduced pain scores without quadriceps weakness in all patients¹⁹. In 2018, Ueshima et al., documented their successful clinical experience using the PENG technique in four patients for perioperative pain management in hip replacement surgery²⁰. Our study aimed to compare PENG block with FIB using Ultrasound as this technique was unexplored and no prospective randomized trial was done before.

In our study, we observed that both the groups were haemodynamically stable without any significant difference in heart rate, blood pressure and oxygen saturation. Hence, PENG block and FIB does not alter the haemodynamic profile of the patients

We observed that PENG block provides superior analgesia than FIB during positioning (sitting) for spinal anaesthesia in cases of hip fracture.

We observed that both PENG block group and FIB group had prolonged duration of analgesia 490 ± 40.8 mins in group P and 470 ± 40.48 mins in group F. Mean doses of analgesic [tramadol 1mg/kg] required per patient in group P were 1.8 ± 0.68 in 1st 24 h in postoperative period compared to 1.9 ± 0.65 in group F. Thus, the overall opioid consumption in postoperative period was reduced without any inter-group differences. All patients were mobilised within 6 hours after surgery with improved functional recovery. No complications were noted in any patient.

Based on our findings in this study of 30 patients of each group, we recommend more widespread use of USG guided PENG block for perioperative analgesia in patients with hip fractures as it provides satisfactory analgesia and patient comfort.

As this is a novel study and no previous randomized trials have been done, further studies are required to compare the efficacy of this new technique with that of already established techniques for hip analgesia.

One of the limitation of our study was assessment of VAS score which is subjective and can vary with the level of understanding between patient and anaesthesiologist. Duration of hospital stay was not recorded.

Conclusion

PENG block provides better analgesia for optimal positioning with better patient satisfaction than Fascia iliaca block for central neuraxial block in patients undergoing surgery for hip fractures. It also provides comparable duration of postoperative analgesia with FIB with a good safety profile.

Conflict of Interest: nil

Financial assistance: nil

References

1. Brauer CA, Coca-Perraillon M, Cutler DM, Rosen AB. Incidence and mortality of hip fractures in the United States. *JAMA* 2009 Oct 14;302(14):1573-9.
2. National Clinical Guideline Centre (UK). The Management of Hip Fracture in Adults [Internet]. London: Royal College of Physicians(UK); 2011. (NICE Clinical Guidelines, No. 124) 10, Surgical procedures.
3. Sandby Thomas M, Sullivan G, Hall JE. A national survey into the perioperative anaesthetic management of patients presenting for surgical correction of a fractured neck of femur. *Anaesthesia* 2008;63:2508.
4. Jadon A, Kedia SK, Dixit S, et al. Comparative evaluation of femoral nerve block and intravenous fentanyl for positioning during spinal anaesthesia in surgery of femur fracture. *Indian J Anaesth* 2014 Nov-Dec;58(6):705-708.
5. Morrison RS, Magaziner J, Gilbert M, et al. Relationship between pain and opioid analgesics on the development of delirium following hip fracture. *J Gerontol A Biol Sci Med Sci* 2003;58:76-81.
6. Haines L, Dickman E, Ayvazyan S, Pearl M, Wu S, Rosenblum D, et al. Ultrasound-guided fascia iliaca compartment block for hip fractures in the emergency department. *J Emerg Med* 2012;43:692-697. 6.
7. Unneby A, Svensson O, Gustafson Y, Olofsson B. Femoral nerve block in a representative sample of elderly people with hip fracture: a randomised controlled trial. *Injury* 2017;48:1542-1549.
8. Beaudoin FL, Haran JP, Liebmann O. A comparison of ultrasound-guided three-in-one femoral nerve block versus parenteral opioids alone for analgesia in emergency department patients with hip fractures: a randomized controlled trial. *Acad Emerg Med* 2013;20: 584-591.
9. Guay J, Parker MJ, Griffiths R, Kopp S. Peripheral nerve blocks for hip fractures. *Cochrane Database Syst Rev* 2017;5:CD001159.

10. Marhofer P, Nased C, Sitzwohl C, Kapral S. Magnetic resonance imaging of the distribution of local anesthetic during the three-in-one block. *Anesth Analg* 2000;90:119-124.
11. Swenson JD, Davis JJ, Stream JO, Crim JR, Burks RT, Greis PE. Local anesthetic injection deep to the fascia iliaca at the level of the inguinal ligament: the pattern of distribution and effects on the obturator nerve. *J Clin Anesth* 2015;27:652-657.
12. Wertheimer LG. The sensory nerves of hip joint. *J Bone Joint Surg Am* 1952;34-A:477-487.
13. Birnbaum K, Prescher A, Hessler S, Heller KD. The sensory innervation of the hip joint – an anatomical study. *SurgRadiol Anat.* 1997;19:371-375. 13.
14. Gardner E. The innervation of the hip joint. *Anat Rec.* 1948;101:353-371.
15. Gerhardt M, Johnson K, Atkinson R, et al. Characterisation and classification of the neural anatomy in the human hip joint. *Hip Int* 2012; 22:75-81
16. Short AJ, Barnett JJG, Gofeld M, et al. Anatomic study of innervation of the anterior hip capsule: implication for image-guided intervention. *Reg Anesth Pain Med* 2018;43:186-192.
17. Bhatia A, Hoydonckx Y, Peng P, Cohen SP. Radiofrequency procedures to relieve chronic hip pain. An evidence-based narrative review. *Reg Anesth Pain Med* 2018;43:72-83.
18. Urwin SC, Parker MJ, Griffiths R. General versus regional anaesthesia for hip fracture surgery: A meta-analysis of randomized trials. *Br J Anaesth* 2000;84:450-5.
19. Girón-Arango L, Peng PW, Chin KJ, Brull R, Perlas A. Pericapsular nerve group (PENG) block for hip fracture. *Reg Anesth Pain Med* 2018 Nov 1;43(8):859-63
20. Ueshima H, Otake H. Clinical experiences of pericapsular nerve group (PENG) block for hip surgeries. *J Clin Anesth* 2018;51:60-1
21. Stoelting RK, Flood P, Rathmell JP, Shafer S. *Stoelting's Pharmacology and Physiology in Anesthetic Practice*. 5th ed. Philadelphia: Lippincott Williams and Wilkins; 2015. pp.282-313.
22. Sia S, Pelusio F, Barbagli R, Rivituso C. Analgesia before performing a spinal block in the sitting position in patients with femoral shaft fracture: A comparison between femoral nerve block and intravenous fentanyl. *Anesth Analg* 2004;99:1221-4.
23. Mosaffa F, Esmaelijah A, Khoshnevis H. Analgesia before performing a spinal block in the lateral decubitus position in patients with femoral neck fracture: A comparison between fascia iliaca block and IV fentanyl. *Reg Anesth Pain Med.* 2005;30(Suppl 1):61.
24. Iamaroon A, Raksakietisak M, Halilamien P, et al. Femoral nerve block versus fentanyl: Analgesia for positioning patients with fractured femur. *Local Reg Anesth* 2010;3:21-6.

