

## Spectrum of Histomorphological Changes in Ovarian Specimens A Rural Based Tertiary Care Center Study

K Sathiyamurthy<sup>1</sup>, S Waheeda<sup>2</sup>, N Sangeetha<sup>3</sup>

**Author Affiliation:** <sup>1</sup>Associate Professor, Department of Pathology, <sup>2</sup>Assistant Professor, Department of Physiology, Vinayaka Mission's KirupanandaVariyar Medical College and Hospital, Vinayaka Mission's Research Foundation (Deemed to be university) Salem, Tamil Nadu 636308, India. <sup>3</sup>Assistant Professor, Department of Pathology, Tagore Medical college and Hospital, Rathinamangalam, Melakottaiyur, Chennai, Tamil Nadu 600127, India.

### Corresponding Author:

**K Sathiyamurthy**, Associate Professor, Department of Pathology, Vinayaka Mission's KirupanandaVariyar Medical College and Hospital, Vinayaka Mission's Research Foundation (Deemed to be university) Salem, Tamil Nadu 636308, India.

**Email:** drksathiyamurthy111@gmail.com

### Abstract

**Background:** Ovarian lesions form a frequent cause of hospitalization among females with different ages. Although most cases are physiological with no need for therapy, considerable number come as complicated cases and require surgical intervention. Clinical spectrum, associated findings and the diverse histomorphological patterns of ovarian lesions, thus offers a specific diagnosis which is of paramount clinical significance for both pathologist and gynaecologist for better understanding of the disease and planning proper management of the patients.

**Aim of the study:** To study various histomorphological patterns of ovarian lesions.

**Materials and methods:** Retrospective study was done in the department of Pathology at Vinayaka Mission's KirupanandaVariyar Medical College and Hospital, Salem for duration of 02 years ie, from April 2019 to March 2021 on 110 ovarian specimens.

**Results:** In our study Non neoplastic ovarian lesions were more commonly reported which constituted about 96.3% and Neoplastic lesions constituted only 3.6%. Corpus luteal cyst was most commonly reported (50.9%). Next common was Follicular cyst 16.9%.

**Conclusion:** Non-neoplastic ovarian lesions were more commonly seen. Among non neoplastic lesions, corpus luteal cyst was more common.

**Keywords:** Corpus luteal cyst; Follicular cyst.

### How to cite this article:

K Sathiyamurthy, S Waheeda, N Sangeetha/Spectrum of Histomorphological Changes in Ovarian Specimens A Rural Based Tertiary Care Center Study/Indian J Pathol Res Pract. 2021;10(3):115-119.

## Introduction

Ovarian lesions are unusual because of their diverse morphology and association with relatively mild symptoms. Ovarian enlargements (lesions), cystic or solid, may occur at any age.<sup>1</sup> These enlargements may be Non-neoplastic or Neoplastic in nature. Non-Neoplastic Enlargements include Simple Follicular Cysts, Corpus Leuteal Cysts, Chocolate Cysts due to Endometriosis, Twisted Hemorrhagic Cysts, Polycystic Ovarian Disease (PCOD), Various Inflammatory Lesions, etc. To define a functional non-neoplastic cyst, its size or diameter must be at least 3 cm, but not more than 7 cm.<sup>1</sup> Non-Neoplastic Enlargements develop almost exclusively during the childbearing years. They may be asymptomatic or produce local discomfort, menstrual disturbances, infertility, or in rare cases cause acute symptoms due to complications like haemorrhage, rupture or torsion.<sup>1</sup>

Neoplastic disorders can arise from (1) mullerian epithelium, (2) germ cells or (3) sex cord stromal cells.<sup>2</sup> Typically, ovarian masses consist of functional and pathological lesions.<sup>2</sup> The ovary has three main histologic compartments i.e. the surface Mullerian epithelium, the germ cells and the sex-cord stromal cells. Each compartment gives rise to distinct non-neoplastic and neoplastic lesions.<sup>3,4</sup> Such lesions can be found from neonatal to postmenopausal ages and it accounts for around 30% of all female genital Cancers.<sup>5</sup>

Ovarian tumors are regarded as one of the most complex tumour of women in terms of histogenesis, clinical behaviour and malignant potentiality. It represents the sixth most common female cancer and the fourth leading cause of death due to cancers in women.<sup>6,7</sup> Histomorphological classification of ovarian tumours forms an integral part of the evaluation of the neoplasms.<sup>8</sup> Determination of various histological patterns of ovarian tumors is very important in the diagnosis, prognosis as well as treatment of ovarian tumors.

Ovarian tumour and non-neoplastic lesions present a great challenge to gynaecological oncologist. Certain non-neoplastic lesions of the ovary frequently form a pelvic mass and potentially mimic an ovarian neoplasm. Their proper recognition and classification is therefore important to allow appropriate therapy.<sup>9</sup>

## Aim of the Study

The aim of the study is to know various histomorphological patterns of ovarian lesions.

## Materials and Methods

Ethical institutional permission was taken. Retrospective study was done in the department of Pathology at Vinayaka Mission's KirupanandaVariyar Medical College and Hospital, Salem Tamil Nadu for duration of 02 years ie, from April 2019 to March 2021 on 110 ovarian specimens.

*Inclusion criteria:* All ovarian specimens received in the Pathology department in the form of resected ovarian masses/ cystectomy specimens, all forms of cyst, Hysterectomy specimens with tubes and ovaries, Endometrial changes secondary to ovarian cause.

*Exclusion criteria:* Cervical lesion, Myometrial lesions and endometrial lesions not due to ovarian cause.

## Methodology

110 ovarian specimens were included in the study and with due permission We collected relevant clinical data, list of investigations, the radiologic findings from biopsy records are noted in each patient. All the ovarian samples were received from the department of Obstetrics and Gynaecology for histopathological examination. All ovarian specimens were obtained in fixative (10% formalin). Type of specimen was identified. Gross examination was done which included size, colour, and consistency and cut surface. Sections were taken from solid, cystic areas and papillary projections and growth. Sections were taken of size 1.5x 1 cm. Tissue processing was done. The section was dehydrated in alcohol, cleared in xylol and embedded in paraffin wax. The corresponding blocks were prepared and 3 to 5-micron thick section were cut from each paraffin block and stained with hematoxylin and eosin stain. Histopathological examination was done on all slides. Sections were taken according to the guidelines given in Rosai(10). Sections were processed and stained with H&E, Histomorphological patterns were noted. The histological characterization was done according to the WHO classification of 2020.<sup>11</sup>

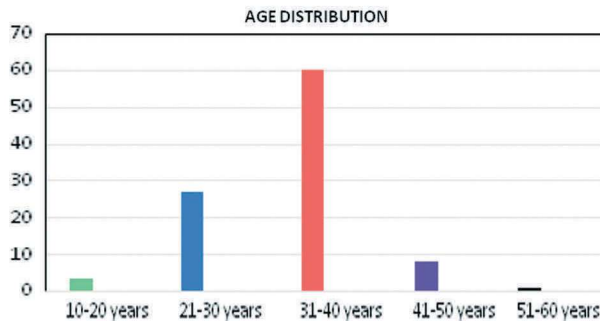
Hematoxylin and Eosin (H&E) stain slides were examined under microscopy and the lesions were then studied and classified as per the W.H.O. classification of ovarian tumours.

## Statistical analysis

Data entered in Microsoft Excel sheet and analysed using SPSS version 20.0 statistical software. Data are depicted in the form of tables, graph's, percentage and proportion.

**Results and Observations**

In our study age distribution range from 10-60 years with majority of cases included among 31-40 years which constituted about 60% (66/110). Next common age group was among 21-30 years constituting 27.2% (30/110). The youngest patient of our study was a girl of 12 years with mature cystic teratoma and the oldest patient was 52 years, a case of mucinous cystadenocarcinoma ovary.



Graph 1: showing age distribution of ovarian lesions.

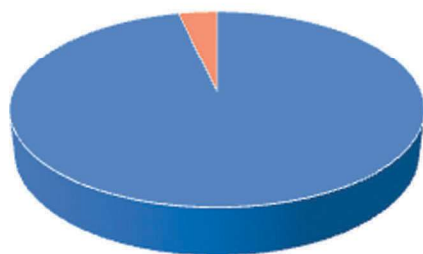
Table 1: Presenting Complaints and Clinical Features.

Clinical Features	No. of Cases	%
Abdominal Pain	60	54.5
Dysmenorrhea	36	32.7
Urinary Symptoms	08	7.2
Abdominal Distention	02	1.8
Mass Per Abdomen	02	1.8
Menorrhagia	02	1.8
Total	110	99%

In our study majority of patients presented with abdominal pain 54.5% (60/110) and dysmenorrhea 32.7% (36/110) menorrhagia, mass per abdomen and abdominal distension constituted 1.8% (02/110) each.

Table 2: Distribution of Ovarian lesions.

Ovarian Lesions	No. of Cases	%
Non neoplastic lesions	106	96.3
Neoplastic lesions	04	3.6
Total	110	99.9



Graph 2: Showing distribution of ovarian lesions on microscopy.

In our study Non neoplastic ovarian lesions were more commonly reported which constituted about 96.3% (106/110) and Neoplastic lesions constituted only 3.6% (04/110).

On Gross examination majority were cystic 98.1% (108/110), Both cystic and solid areas and only solid areas were seen in 1.8% (02/110) cases each. Based on site of involvement majority of the tumors were unilateral about 98.1% (108/110) with right side predominance, Malignant tumor and metastatic tumor were bilateral about 1.8% (02/110).

Table 3: Non neoplastic ovarian lesions.

Non neoplastic lesions (106/110)	No. of Cases	%
Non Specific Oophoritis	10	9.43
Follicular Cyst	18	16.9
Simple Serous Cyst	09	8.4
Corpus Luteal Cyst	54	50.9
Hemorrhagic Cyst	15	14.1
Total	106	99.7%

Among Non neoplastic ovarian lesions, corpus luteal cyst reported in 50.9% (54/106) cases. Next common was Follicular cyst 16.9% (18/106), Hemorrhagic Cyst constituted 14.1% (15/106), Non Specific Oophoritis in 9.4% (10/106) cases, and Simple Serous Cyst in 8.4% (09/106) cases.

Table 4: Histomorphological Patterns of ovarian Neoplastic lesions.

Ovarian Tumors (04/110)	No. of cases	%
Serous Cystadenoma	01	25
Mature Cystic Teratoma	01	25
Mucinous Cystadenocarcinoma	01	25
Krukenbergstumor	01	25
Total	04	100%

In our study out of 04 ovarian tumors, One case of Benign serous cystadenomas diagnosed in 26 year old female.

One case of Mature Cystic Teratoma was reported in a 12 year old girl. One malignancy was reported in our study and diagnosed as Mucinous Cystadenocarcinoma in a 55 year old female. 37 year old female was reported as metastatic lesion and it was bilateral (Krukenbergstumor) primary probably from Breast carcinoma.

**Discussion**

Comparative studies related to age distribution In our study majority of the cases were among 31-

40 years which constituted about 60% with mean age of 38 years. Next common age group was 21-30 years constituting 27.2%. Our findings were compared with Abdulkareem Younissuleiman et al<sup>12</sup> study where he observed mean age of 32 years and ovarian cysts were more commonly seen in the age group 20-29 years (27.9%). In Akina Prakash A et al study<sup>13</sup> patients in the age group of 20-39 years constituted the majority of patients (53.4%).

#### Comparative studies related to Clinical features

In our study majority of patients presented with abdominal pain 54.5% and Dysmenorrhea 32.7%. In Ashok Panchonia et al study<sup>14</sup> Abdominal pain (38.7%) was most common presenting symptom followed by abdominal distension (34.1%), menorrhagia (18.2%), dysmenorrhea, polymenorrhea, weight loss, sterility, urinary symptoms and mass per vagina.

#### Comparative studies related to site of presentation of ovarian lesions

Based on site of involvement majority of the lesions were unilateral (98.1%) in our study with right side predominance, Malignant tumor and metastatic tumor were bilateral occupying about 1.8%. In Akina Prakash A et al study<sup>13</sup> 208 masses were unilateral (90.8%) and 21 were bilateral (9.2%). In Ashok Panchonia et al study<sup>14</sup> Among 133 non neoplastic lesions, right sided cases found in 64 (48%), and left sided in 45 cases (34%) while 24 cases (18%) are bilateral. neoplastic lesions are also found more common on right side (52%) than left(37%), while bilaterality in 11% of the cases.

**Table 5:** Comparative studies :Distribution of Ovarian lesions.

Comparative studies	Non neoplastic lesions	Neoplastic lesions
Ashok Panchonia et al study <sup>14</sup>	133(62.2%)	81(37.8%)
Gaikwad SL et al study <sup>15</sup>	101(54.6%)	84(45.4%)
Akina Prakash et al <sup>13</sup>	101(44.1%)	128(55.8%)
Present study	106(96.3%)	04(3.6%)

Our study, Ashok Panchonia et al study<sup>14</sup> and Gaikwad SL et al study<sup>15</sup> observed Non neoplastic ovarian lesions are more common where as Akina Prakash et al<sup>13</sup> noted neoplastic lesions as majority (55.8%).

In the Present study Among Non neoplastic ovarian lesions, corpus luteal cyst reported in 50.9% (54/106) cases. Next common was Follicular cyst 16.9%(18/106), Hemorrhagic Cyst constituted 14.1% (15/106), Non Specific Oophoritis in

9.4%(10/106) cases, and Simple Serous Cyst in 8.4% (09/106) cases. Similar findings were observed in study conducted by Gaikwad SL et al<sup>15</sup> where most common non-neoplastic lesion observed was corpus luteal cyst (28; 27.7%) followed by simple ovarian cyst (25; 24.7%) and follicular cyst (22; 21.8%).

**Table 6:** Comparative studies of distribution of Non neoplastic ovarian lesions.

Non neoplastic lesions	Gaikwad SL et al <sup>15</sup>	Ashok Panchonia et al study <sup>14</sup>	Akina Prakash A et al study <sup>13</sup>	Present study
Non Specific Oophoritis	2(2%)	10(7.5%)	-	10(9.4%)
Follicular Cyst	22(21.8%)	14(10.5%)	46(45.5%)	18(16.9%)
Simple Serous Cyst	25(24.7%)	48(36.0%)	-	09(8.4%)
Corpus luteal cyst	28(27.7%)	33(25%)	25(25%)	54(50.9%)
Hemorrhagic Cyst	20(19.8%)	18(13.5%)	-	15(14.1%)
Others	4(4%)	10(13.6%)	18	-
Total	101	133	101	106(99.7%)

The haemorrhagic cyst was observed in 19.8% cases, others cystic lesion in 4% cases and chronic oophoritis in 2% cases. In Abdulkareem Younissuleiman et al<sup>12</sup> corpus luteal cyst was commonly reported accounting 26% and Follicular cysts were 6.8%.

Hence our study findings were in collaboration with other respective studies.

**Table 7:** Comparative studies of distribution of Neoplastic ovarian lesions.

Neoplastic ovarian lesions	Abdulkareem Younissuleiman et al study <sup>12</sup>	Gaikwad SL et al <sup>15</sup>	Ashok et al study <sup>14</sup>	Present study
Surface epithelial tumors	61	60	55	02
Germ cell tumors	37	18	20	01
Sex cord stromal tumors	04	06	05	-
Metastases /other tumors	01	-	01	01
Total	103	84	81	04

In our study out of among surface epithelial tumors one case was Benign serous cystadenoma and other was reported as malignancy (Mucinous Cystadenocarcinoma).

Among Germ cell tumours one case (0.9%) diagnosed as Mature Cystic Teratoma.



One case of metastatic lesion was diagnosed as bilateral Krukenbergstumor primary probably from Breast carcinoma.

In Abdulkareem Younissuleiman et al study<sup>12</sup> Histologically, functional cysts formed (32.8%) of cases followed by mature cystic teratoma (22.9%), then serous cystadenoma (19.8%). Malignant tumors were demonstrated in 9 cases, 8 primary, and 1 metastatic Krukenbergstumor. In AkinaPrakashA et al study<sup>13</sup> Serous cystadenomas were the most common lesion diagnosed (62.5%), Mucinous cystadenomas were the second most common(24.2%). Only four malignant lesions were diagnosed. In Gaikwad SL et al<sup>15</sup> Out of 84 cases of ovarian tumours, amongst surface epithelial tumour, serous cystadenoma constituted 47.6% cases followed by mucinous cystadenoma (38.1%).

## Conclusion

Non-neoplastic ovarian lesions were more commonly seen in the present study. Among non neoplastic lesions, corpus luteal cyst was more common. Surface epithelial tumours were the most common histologic type reported in our study. Both non-neoplastic and neoplastic ovarian lesions often present with similar clinical and radiological characteristics. Histopathological research is therefore important for the diagnosis and prediction of ovarian lesions.

## References

1. Padubidri VG, DaftarySN,Howkins& Bourne. Disorders of ovary,Shaw's Textbook of Gynaecology, 16th edition. India. Reed ReedElsevier; 2015:429-34.
2. Modi D, Rathod GB, Delwadia KN, Goswami HM. Histopathological pattern of neoplastic ovarian lesions. IAIM. 2016;3(1):51-7.
3. Forae GD, Aligbe JU. A histopathological overview of ovarian lesions in Benin City, Nigeria: How common is the functional cyst? Int J Med Public Health. 2014;4:265-8.
4. Prat J, D'Angelo E, Espinosa I. Ovarian carcinomas- at least five different diseases with distinct histological features and molecular genetics. Human Pathol. 2018;80:11-27. doi: [Article:https://doi.org/10.1016/j.humpath.2018.06.018][Crossref].
5. Supriya BR, Patel R, Patel M. Histopathological evaluation of Non-Neoplastic and Neoplastic Lesions of Uterine Cervix at tertiary care centre. Trop J Path Micro. 2019;5(3):177-182. Available from: [Article:https://pathology.medresearch.in/index.php/jopm/article/view/245][Crossref]
6. Scully RE, Young RH, Clement PB. Tumors of the ovary, maldeveloped gonads, fallopian tube, and broad ligament. AmerRegPathol. 1998. [Crossref]
7. Tortolero L, Mictchell FM, Rhodes HE. Epidemiology and screening of ovarian cancer. ObstetGynecolClin North Am. 1994;21:63-75.
8. Sheikh S, Humaira Bashir, Summyia Farooq, ArshiBeigh, FarzanaManzoor, et al. Histopathological spectrum of ovarian tumours from a referral hospital in Kashmir valley, Jammu and Kashmir, India.Int J Res Med Sci. 2017 May;5(5):2110-2114.
9. Gupta N, Bisht D, Agarwal AK, Sharma VK. Retrospective and prospective study of ovarian tumours and tumour-like lesions. Indian J PatholMicrobiol. 2007;50(3):525-27.
10. Goldblum RJ, Lamps LW, McKenney JK. Ovary. Rosai and Ackerman's Surgical Pathology. Eleventh Edition. Philadelphia: Elsevier;2018.
11. WHO Histological Classification of Ovarian tumors. Geneva: WHO; 2020.
12. Abdulkareem Younis SULEIMAN, Intisar Salim PITY, Mohammed R MOHAMMED, Bashir Abduljabar HASSAWI. Histopathological patterns of ovarian lesions: A study of 161 cases BIOCELL 2019 43(3): 175-181.
13. Akina Prakash, Sravan Chinthakindi, Ramanan Duraiswami, Indira V Original Research Article Histopathological study of ovarian lesions in a tertiary care center in Hyderabad, India: a retrospective five-year study International Journal of Advances in Medicine Int J Adv Med. 2017 Jun;4(3):745-749.Int J Adv Med. 2017 Jun;4(3):745-749 http://www.ijmedicine.com pISSN 2349-3925 | eISSN 2349-3933.
14. Dr Ashok Panchonia1, Dr Aksharaditya Shukla, Prof. Dr C.V. Kulkarni, Dr HarshulPatidar. Original Article Histopathological spectrum of ovarian lesions in tertiary care institute of central India. JMSCR 2018;6(1)32575-32581.
15. Gaikwad SL., Badlani KS., Birare SD. Histopathological study of ovarian lesions at a tertiary rural hospital. Tropical Journal of Pathology and Microbiology 2020;6(3)244-250.



**STATEMENT ABOUT OWNERSHIP AND OTHER PARTICULARS**

**Indian Journal of Pathology: Research and Practice" (See Rule 8)**

- |   |   |  |
|---|---|--|
| 1. Place of Publication   | : | Delhi  |
| 2. Periodicity of Publication   | : | Quarterly  |
| 3. Printer's Name   | : | <b>Dinesh Kumar Kashyap</b>  |
| Nationality   | : | Indian   |
| Address   | : | 3/259, Trilokpuri, Delhi-91  |
| 4. Publisher's Name   | : | <b>Dinesh Kumar Kashyap</b>  |
| Nationality   | : | Indian   |
| Address   | : | 3/259, Trilokpuri, Delhi-91  |
| 5. Editor's Name  | : | <b>Dinesh Kumar Kashyap</b>  |
| Nationality   | : | Indian   |
| Address   | : | 3/259, Trilokpuri, Delhi-91  |
| 6. Name & Address of Individuals<br>who own the newspaper and particulars of<br>shareholders holding more than one per cent<br>of the total capital | : | <b>Red Flower Publication Pvt. Ltd.</b><br>41/48, DSIDC, Pocket-II<br>Mayur Vihar, Phase-1, Delhi-91 |

I, **Dinesh Kumar Kashyap**, hereby declare that the particulars given above are true to the best of my knowledge and belief.

Sd/-

**(Dinesh Kumar Kashyap)**