

Role of Low Level Laser Therapy in Scar Management

Gopikrishna Mohanraj¹, Ravi Kumar Chittoria², Jacob Antony Chakiath³

How to cite this article:

Gopikrishna Mohanraj, Ravi Kumar Chittoria, Jacob Antony Chakiath / Role of Low Level Laser Therapy in Scar Management / Journal of Plastic Surgery and Transplantation. 2022;3(1):13-16.

Author Affiliation: ¹Junior Resident, Department of General Surgery, ²Professor, Department of Plastic Surgery & Telemedicine, ³Senior Resident, Department of Plastic Surgery, Jawaharlal Institute of Postgraduate Medical Education and Research Institute, Pondicherry 605006, India.

Corresponding Author: Ravi Kumar Chittoria, Professor, Department of Plastic Surgery, Jawaharlal Institute of Postgraduate Medical Education and Research, Pondicherry 605006, India.

E-mail: drchittoria@yahoo.com

Received on : 27.04.2022

Accepted on : 31.05.2022

Abstract

It is well known that low level laser therapy (LLLT) has a role in the wound bed preparation of ulcers, wound healing process, joint stiffness and nerve regeneration, but the role of LLLT in the scar management is doubtful and has scanty data. In this case report we are sharing our experience in treating a scar with LLLT which showed enhanced response.

Keywords: Scar, Low level laser, Vancouver Scar Scale.

Introduction

Adult wound healing comprises following phases before forming a scar Inflammatory phase, proliferative phase and remodeling phase. Any factors that hinder the wound healing process will worsen the wound healing and will make a bad scar. Bad scar will make cosmetic problems and functional impairment of parts involved. The low-level laser therapy decreases fibrous tissue formation which makes up scar tissue. It softens the fibrotic nodules of the scar tissue and restores

normal circulation, allowing nerves to regenerate. Its main aim is to restore the skins normal appearance following trauma, may it be via a burn, cut or surgery. Low level laser therapy (LLLT) is characterized by its ability to induce a non-thermic process (bio stimulation), and it is monochromatic, coherent, and polarized. This can be transmitted, reflected, refracted, and absorbed. The differences between the various types of laser beams produced are determined using wave lengths, power, irradiance, energy density, pulse duration, pulse repetition rate, area, and beam mode.⁶ Considering

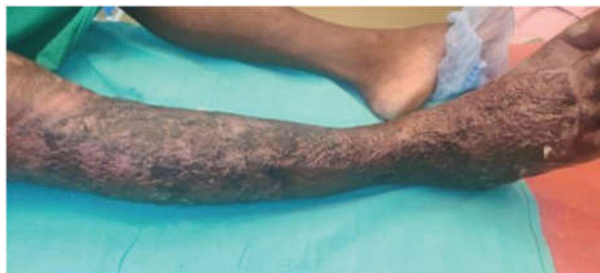

Fig. 1: Scar at the time of presentation

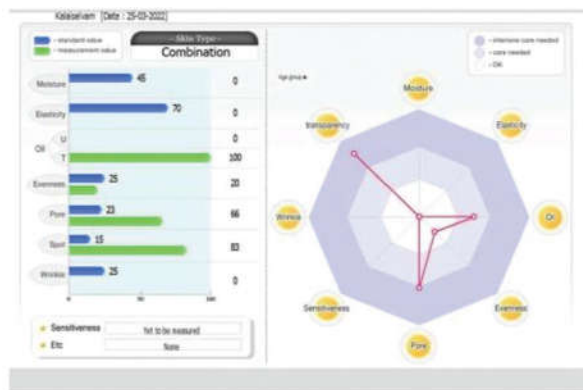
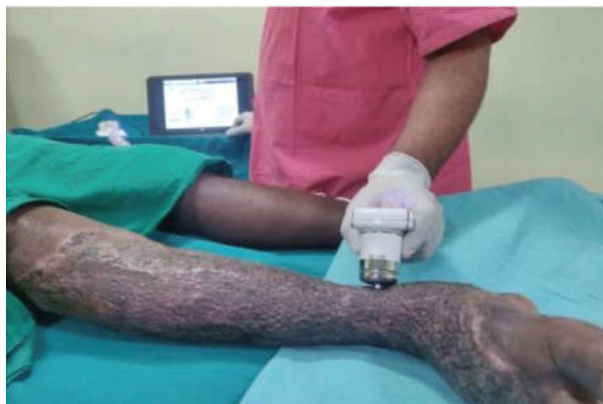

Fig. 2: Videodermatoscopy assessment of scar

that the scars have a functional and emotional impact on people, they should not be considered as an afterthought, but as a change that must be addressed. In this sense, LLLT therapy should be applied, since there were observed effects and results in wound healing.¹⁴ The purpose of this case report was to analyze the effectiveness of LLLT on scar tissue, evaluating its effects in vascularity, pliability, pigmentation and height of the scar as per Vancouver Scar Scale (VSS).

Methods and Materials

The study was conducted in tertiary care level plastic surgery department after getting consent from the patient. The details of the patient as follows: 40 year old male with known diabetic for 10 years on treatment presented with post soft tissue infection raw area. Wound healed with bad scar (Fig. 1). Video dermatoscopy (Fig. 2) and Vancouver scar scale (VSS) used to asses the scar scale. Score was calculated to know extent of scar. LLLT was given to the scar in four sessions once a week for a total of four session. (Fig. 3) Wound inspection and dressing done after each session. Low level laser source we used was Gallium Arsenide (gas) diode red laser of wavelength 650 nm, frequency 10 KHZ and output power 100 mw, which was a continuous beam laser with an energy density of 4 J/cm2. Machine delivers laser in scanning mode (non-

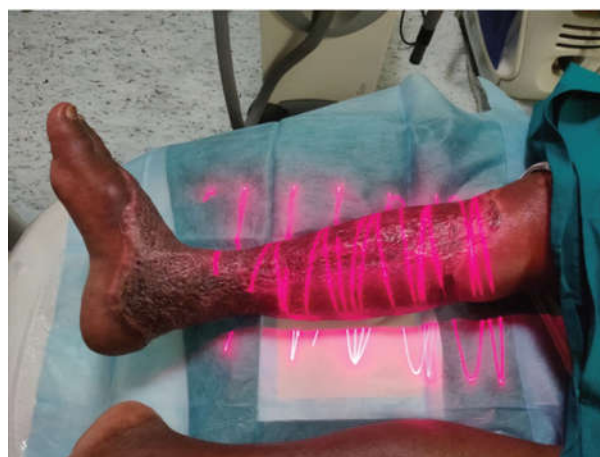

Fig. 3: Application of low level laser therapy on scar site

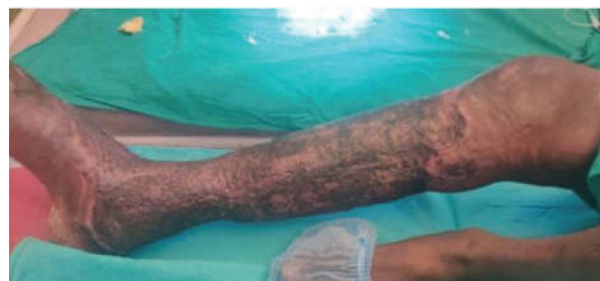

Fig. 4: Scar area at the time discharge. Scar improved well. VSS score at the time of discharge is 7/13 and video dermatoscopy shows improvement of scar.

contact delivery) with 60 cm distance between laser source and the scar. Scar received laser therapy for duration of 125 second every time for 15 minutes for 4 sessions, 1 week apart and Vancouver Scar Scale composed of vascularity, pliability, pigmentation and height of the scar was calculated. Total score of VSS 13 which was suggestive of bad scar. In our case, initial VSS score was 13/13.

Results

Low-level laser therapy has been found to be useful in improving scar vascularity, pliability, pigmentation and height. No side effects were observed during the study. The pre-procedural and post-procedural Vancouver scar scale (VSS) parameters are comparisons showed that there was a significant difference after laser application. The pre-procedural VSS score was 13/13. The post-procedural VSS score was 7/13. Post therapy clinical photograph also showed improvement. (Fig. 4)

Discussion

According to Huang colleagues (2009), an energy density between 3 and 5 J/cm² has a best positive results in scar management in vivo⁵, supporting the use of 4 J/cm² in the present investigation. Energy density appears to be the only treatment parameter with predictable dose dependent treatment effect according to Woodruff and colleagues (2004). These authors have no doubt that LLLT is an effective modality for treating scars. But they also found that the result may be dependent on wave length, pulse duration, irradiance, pulse repetition rate, treatment time, treatment repetition rate, or a combination of all these factors.⁶⁻⁹

Laser application did not change scars' length and width¹⁰. However, Hopkins and colleagues (2004) in a randomized controlled trial, in the first two phases of wound healing, found significant improvement in the scars when comparing the groups, but only in superficial scars (abrasions).¹¹

Despite the lack of evidence on using VSS as standard one, the researcher chose to use them independently in order to observe differences in specific aspects¹² Scar's elasticity and color (as VSS items) improved significantly in echography with an improvement in pigmentation.¹³ Height item VSS results suggested a ceiling effect. Brusselaers and colleagues (2010), in a systematic review of different scars' questioned scales as they are subjective to evaluate scars, depending on who applies them¹⁴⁻¹⁶. This aspect was partially controlled as evaluations were done by the same researcher.

Despite beneficial effects of LLLT, we cannot use LLLT in the pregnant female, irradiation of the neck region in hyperthyroidism; epilepsy; exposure of the retina. The contraindications that are doubtful under certain conditions are as follows: fever and infectious diseases; certain blood diseases; heavy blood losses; neuropathies; and irradiation in the region of gonads. The other contraindications

reported in the literature are considered to be incorrect.⁷

Time of exposure and duration of treatment has to be standardized. We were given 4 session of LLLT each 1 week apart. In a case of Gaida K et al, he given twice week session for 8 weeks.²

The intervention with LLLT appears to have a positive effect on the macroscopic scars' appearance, and on old scars' thickness, in the studied sample. Their outcome didn't fulfill entire criteria of VSS¹⁰ Based on above facts we managed our patient with low level lasertherapy as mentioned in the methodology part, we got a significant outcome as VSS score improved from 13 /13 to 7/13.

Conclusion

Based on the available facts we managed post infective wound scar with low level laser therapy and scar was improved from VSS score 13/13 to 7/13. Videodermatoscopy shows improvement of scar. The limitation of the study it was done on a single subject. Hence the authors suggest that a study including multiple subjects with a control group and multiple centre with randomization to validate the exact result.

Conflicts of interest: None.

Financial support and sponsorship: None.

References

1. Hopkins JT, McLoda TA, Seegmiller JG, David Baxter G. Low-Level Laser Therapy Facilitates superficial wound healing in humans: a triple-blind, sham-controlled study. *J Athl Train.* 2004;39:223-229.
2. Gaida K, Koller R, Isler C, Aytakin O, Al-Awami M, Meissl G, Frey M. Low level laser therapy—a conservative approach to the Burns. 2004;30:362-367.
3. Gupta AK, Filonenko N, Salansky N, Sauder DN. The use of low energy photon therapy (LEPT) in venous leg ulcers: a double-blind, placebo-controlled study. *Dermatol Surg.* 1998;24:1383-1386.
4. Widgerow AD, Chait LA, Stals R, Stals PJ. New innovations in scar management. *Aesthetic Plast Surg.* 2000;24:227-234.
5. van den Helder CJ, Hage JJ. Sense and nonsense of scar creams and gels. *Aesthetic Plast Surg.* 1994;18:307-313.
6. Nouri K, Vidulich K, Rivas MP. Lasers for scars: a review. *J CosmetDermatol.* 2006;5:14-22.
7. English RS, Shenefelt PD. Keloids and hypertrophic

- scars. *Dermatol Surg.* 1999;25:631-638.
8. Kitchen SS, Partridge CJ. A Review of low level laser therapy. *Physiotherapy.* 1991;77:161-168.
 9. Lucas C, Stanborough R.W, Freeman CL, De Haan RJ. Efficacy of low-level laser therapy on wound healing in human subjects: a systematic review. *Lasers Med Sci.* 2000;15: 84-93.
 10. Woodruff LD, Bounkeo JM, Brannon WM, Dawes KS, Barham CD, Waddell DL, Enwemeka CS. The efficacy of laser therapy in wound repair: a meta-analysis of the literature. *Photomed Laser Surg.* 2004;22:241-247.
 11. Huang YY, Chen AC, Carroll JD, Hamblin MR. Biphasic dose response in low level light therapy. *Dose Response.* 2009;7:358-383.
 12. Hawkins D, Abrahamse H. Changes in cell viability of wounded fibroblasts following laser irradiation in broad-spectrum or infrared light. *Laser Chem.* 2007;2007:1-11.
 13. Navratil L, Kymplova J. Contraindications in noninvasive laser therapy: truth and fiction. *J Clin Laser Med Surg.* 2002;20:341-343.
 14. Baryza MJ, Baryza GA. The Vancouver Scar Scale: an administration tool and its interrater reliability. *J Burn Care Rehabil.* 1995;16:535-538.
 15. Brusselaers N, Pirayesh A, Hoeksema H, Verbelen J, Blot S, Monstrey S. Burn scar assessment: a systematic review of different scar scales. *J Surg Res.* 2010;164:e115-e123.
 16. Brusselaers N, Pirayesh A, Hoeksema H, Verbelen J, Blot S, Monstrey S. Burn scar assessment: A systematic review of objective scar assessment tools. *Burns.* 2010;36:1157-1164.

