

Role of Autologous Platelet Rich Plasma in take of Split Thickness Skin Graft in Post Burn Contracture Neck with Raw Area

Naresh Kumar Codandabany¹, Ravi Kumar Chittoria², Barath Kumar Singh P³,
Neljo Thomas⁴

How to cite this article:

Naresh Kumar Codandabany, Ravi Kumar Chittoria, Barath Kumar Singh. P, et. al./Role of Autologous Platelet Rich Plasma in take of Split Thickness Skin Graft in Post Burn Contracture Neck with Raw Area/RFP Journal of Plastic Surgery and Transplantation. 2022;3(2):53-56.

Abstract

All deeper burns i.e. second degree deep dermal and full thickness heals by scarring that causes restrictions in the movements and aesthetics issues for patients. Burn reconstructive surgery requires that the defects after release should be replaced with donor tissues which have matching texture and colour like autologous skin grafting or flap surgeries. Autologous platelet rich plasma contains concentrated platelets after graded centrifugation, which has various applications like alopecia, acne, reproductive techniques etc. Here we are using this method to look for role in take of Split Thickness Skin graft in post burn contracture neck. The main complication of this procedure is risk of graft failure. Autologous platelet rich plasma (APRP) as the name suggests is concentration of the patient's own platelets in a small amount of plasma. It is enriched by growth factors and it acts as a fibrin sealant and has various properties. Its important application is in skin grafting where it aids as a fibrin sealant and also aids in the take of the graft by enriching it with growth factors and promoting angiogenesis. The purpose of this case report is using autologous platelet rich plasma as an adjuvant method for accelerating take of Split Thickness Skin Graft (STSG) in post burn contracture of neck with better prognosis.

Keywords: Autologous platelet rich plasma; Split thickness skin graft; Post burn contracture neck.

Author Affiliation: ¹Visiting Resident, Department of Plastic Surgery, ²Professor & Head of IT Wing and Telemedicine, Department of Plastic Surgery & Telemedicine, ^{3,4}Senior Resident, Department of Plastic Surgery, Jawaharlal Institute of Postgraduate Medical Education and Research, Pondicherry 605006, India.

Corresponding Author: Ravi Kumar Chittoria, Professor & Head of IT Wing and Telemedicine, Department of Plastic Surgery & Telemedicine, Jawaharlal Institute of Postgraduate Medical Education and Research, Pondicherry 605006, India.

E-mail: drchittoria@yahoo.com

Received on: 31-08-2022

Accepted on: 19.09.2022

INTRODUCTION

Burn trauma constitutes the second most common cause of trauma-related deaths after vehicular accidents, in both developing and developed country. An extensive burn is the most devastating injury that human being had to suffer. After immediate concern for survival in victim, restoration to pre-injury status, and return to daily activities becomes important for victim and treating team.¹ A healed burn patient may be left with contractures and scars with varying degrees

of functional issues and cause social stigma among victims.

Platelet Rich Plasma (PRP) is defined as a portion of the plasma having a higher concentration of platelet. It consists of platelets with clotting and growth factors. Platelet derived growth factor (PGF), transforming growth factor (TGF), vascular endothelial growth factor (VEGF), epidermal growth factor (EDF) and fibroblast growth factor (FGF) are also present in APRP and in concentration multiple times higher than normal plasma. Because of properties of enhancing tissue regeneration and healing, APRP may be used as an adjunct therapy.²

PRP functions as a tissue sealant and drug delivery system, with the platelets initiating wound repair by releasing locally acting growth factors via α -granules degranulation. The application of APRP to STSG application sites has been recently described to provide immediate skin graft anchorage as well as inosculation of the STSG with nutrient-rich blood media.³

MATERIALS AND METHODS

This study was conducted in the Department of Plastic Surgery in a tertiary care institute. Informed consent was obtained from the patient under study. Department scientific committee approval was obtained. It is a single center, non-randomized, non-controlled study. The patient under study was a 27 year-old female, with no other known comorbidities presented with Post burn contracture in neck and right shoulder with Raw area at time of presentation (Fig. 1). She had restricted movement and difficulty in daily activities. X-ray of neck anteroposterior and lateral view done ruling out cervical vertebral dislocation (Fig. 2). Antibiotic treatment based on culture sensitivity and she underwent Debridement with Split Thickness Skin Graft (STSG) (Fig. 3) and Autologous Platelet Rich Plasma Injection (APRP). Post Operative Day 4 Graft assessment done with APRP injection (Fig. 3). After

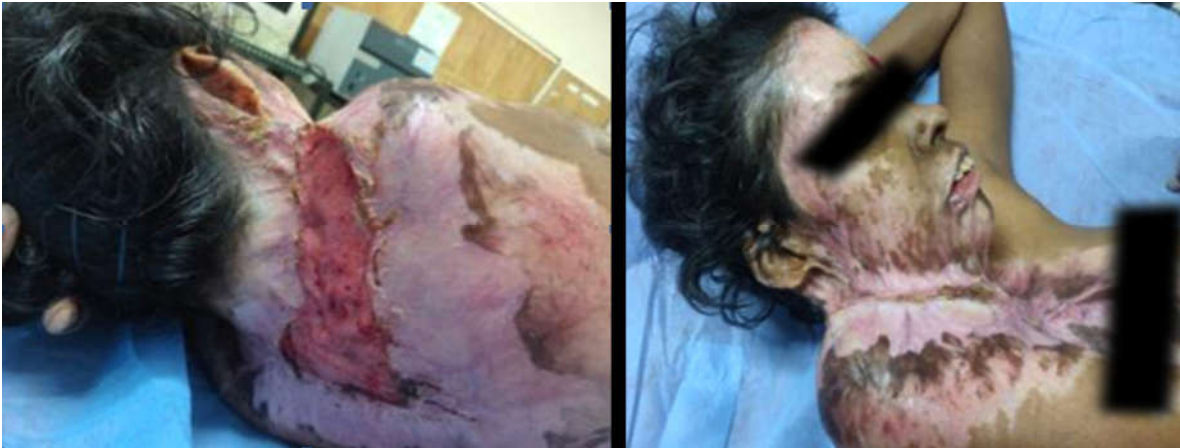

Fig. 1: At time of admission

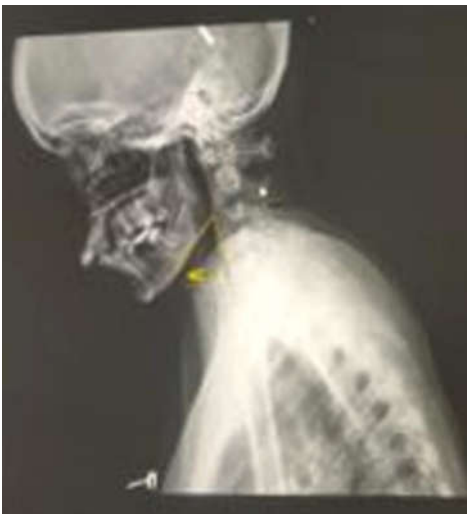

Fig. 2: Cervicomenal angle 46 at the time of presentation

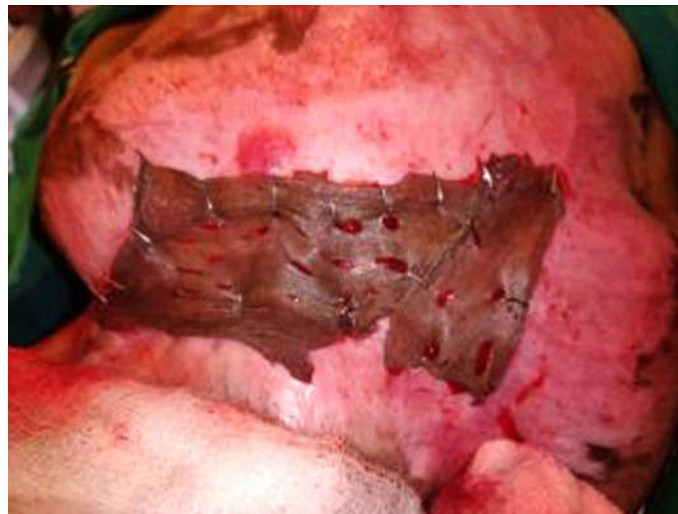


Fig. 3: Split Skin Grafting

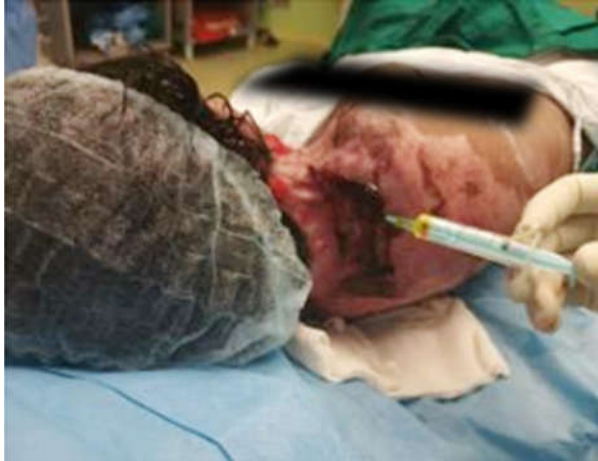

Fig. 4: Autologous Platelet Rich

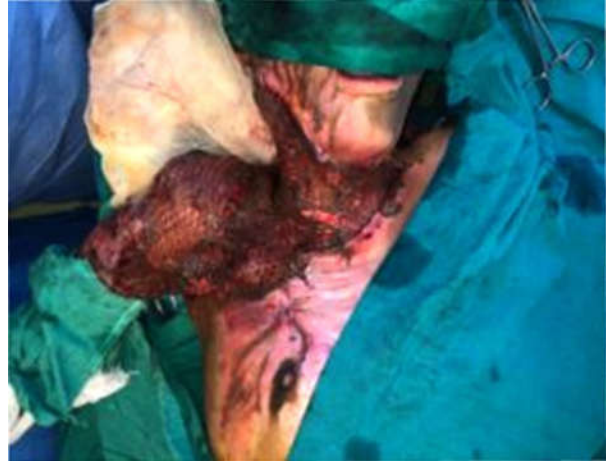

Fig. 5: Post Burn Contracture release and Skin grafting

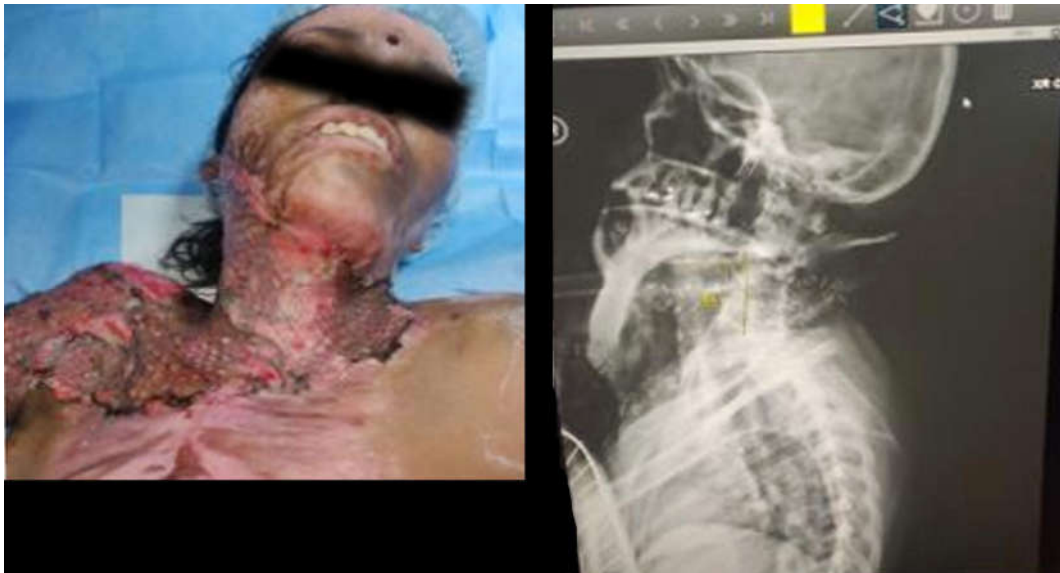

Fig. 6: Graft site assessment after 7 days and cervicomenal angle 84 degree extension

3 weeks Post Burn contracture release and split thickness skin grafting (Fig. 4) with APRP injection. Graft take good, cervicomenal angle improved to 84 degree at Postoperative day 7 (Fig. 6) and patient lost to follow up.

RESULTS

Graft take was good on Post Operative Day 7 (Fig. 6)

DISCUSSIONS

APRP is a biological product defined as a portion of the plasma fraction of autologous blood with a platelet concentration above the baseline.⁵ The

contents of the APRP are not only platelets, but also growth factors such as platelet derived growth factors, chemokines, clotting factors, and fibrin.

The concept and description of PRP started in the field of hematology.⁶ It was used for patients with thrombocytopenia. In the coming days, PRP has been used in various other fields such as musculoskeletal field in sports injuries, cardiac surgery, pediatric surgery, gynecology, urology, plastic surgery, and ophthalmology.

Owing to its contents, the use of APRP has been researched in the field of regenerative medicine in conditions such as alopecia, chronic wounds, and scar management.

The mainstay management of wounds is skin

grafting. The main part of the skin graft is the take of the graft, which is in three stages:

- Stage of imbibitions
- Stage of inosculation
- Stage of revascularization.

PRP aids in bridging the stages of skin graft take.

PRP functions as a tissue sealant and drug delivery system, with the platelets initiating wound repair by releasing locally acting growth factors via α -granules degranulation.⁷ The application of APRP to STSG application sites has been recently described and theorized to provide immediate skin graft anchorage as well as inosculation of the STSG with nutrient rich blood media.⁸ Some study on burns patients, have proven that PRP is safe and effective for fixation of skin grafts due to its adhesive nature, and its outcomes are better than securing skin graft to wound margins or bed with sutures, staples, or glue, hence it not only decreases the surgery time but also avoids the removal of sutures/staplers in postoperative period.⁹

Previous study conducted by Puttirutvong¹⁰ has evaluated the healing time of both meshed full-thickness skin grafts versus STSGs (i.e., 0.015-in thickness) in patients with diabetes. This study revealed a mean total healing time of 20.1 ± 7.3 days for the STSG group, with the primary factor affecting graft take being hematoma/seroma formation and infection. Vijayaraghavan et al.¹¹ showed that wounds treated with APRP therapy alone healed in 4–8 weeks. Wounds treated with APRP and split skin graft/flap cover healed in 3–6 weeks.

CONCLUSIONS

In our study we found that APRP was useful in promoting STSG uptake in a Post Burn Contracture Neck with raw area. The limitation of the study includes that it is a case report with a single centre study with no statistical analysis. Further randomised controlled studies are required to validate the efficacy of the APRP in the uptake of STSG post burn contracture.

REFERENCES

1. Franco D, Franco T, Schettino AM, Filho JM, Vendramin FS. Protocol for obtaining PRP for

- autologous use. *Aesthetic Plast Surg.* 2012;36:1254–9.
2. Pandey S, Chittoria RK, Friji MT, Mohapatra DP and Dinesh KS. Application of Autologous Platelet Rich Plasma (APRP) as an adjuvant therapy in plastic surgery. *International Journal of Clinical and Diagnostic Research.* 2016; 4(6):135-145.
3. Bharathi Mohan P, Gupta S, Chittoria RK, Aggarwal A, Reddy CL, Pathan I, et al. Autologous platelet-rich plasma enriched pixel grafting. *J Cutan Aesthet Surg* 2020;13:340-3.
4. Li W, Enomoto M, Ukegawa M, Hirai T, Sotome S, Wakabayashi Y, et al. Subcutaneous injections of platelet-rich plasma. *Plast Reconstr Surg.* 2012;129:858–6.
5. Alves R, Grimalt R. Randomized placebo-controlled, double-blind, half-head study to assess the efficacy of platelet-rich plasma on the treatment of androgenetic alopecia. *Dermatol Surg.* 2016;42:491–7.
6. Andia I, Abate M. Platelet-rich plasma: underlying biology and clinical correlates. *Regen Med.* 2013;8:645–58.
7. Thimmanahalli G, Kumar M. Efficacy of autologous platelet rich plasma over conventional mechanical fixation methods in split thickness skin grafting. *Int Surg J.* 2018;6:108.
8. Schade VL, Roukis TS. Use of platelet-rich plasma with split-thickness skin grafts in the high-risk patient. *Foot Ankle Spec.* 2008;1:155–9.
9. Gibran N, Luterman A, Herndon D, Lozano D, Greenhalgh DG, Grubbs L, et al. Comparison of fibrin sealant and staples for attaching split-thickness autologous sheet grafts in patients with deep partial- or full-thickness burn wounds: a phase 1/2 clinical study. *J Burn Care Res.* 2007;28:401–8.
10. Puttirutvong P. Meshed skin graft versus split thickness skin graft in diabetic ulcer coverage. *J Med Assoc Thai.* 2004;87:66–72.
11. Vijayaraghavan N, Mohapatra DP, Friji MT, Arjun A, Bibilash BS, Pandey S, et al. Role of autologous platelet rich plasma (APRP) in wound healing. *J Soc Wound Care Res.* 2014;7:23–8.

