

# Role of Centella Asiatica Extract in Scald Burns

Gnaneshvar Manivannan<sup>1</sup>, Ravi Kumar Chittoria<sup>2</sup>, Neljo Thomas<sup>3</sup>

**Author's Affiliation:** <sup>1</sup>Junior Resident, Department of General Surgery, <sup>2</sup>Professor, Department of Plastic Surgery & Telemedicine, <sup>3</sup>Senior Resident, Department of Plastic Surgery, Jawaharlal Institute of Postgraduate Medical Education and Research, Puducherry 605006, India.

## How to cite this article:

Gnaneshvar Manivannan, Ravi Kumar Chittoria, Neljo Thomas / Role of Centella Asiatica Extract in Scald Burns / JBB Journal of Biochemistry and Biophysics. 2022;7(1):9-12

**Corresponding Author:** Ravi Kumar Chittoria, Professor, Department of Plastic Surgery & Telemedicine, Jawaharlal Institute of Postgraduate Medical Education and Research, Puducherry 605006, India.

**E-mail:** drchittoria@yahoo.com

**Received:** 16.07.2022

**Accepted:** 19.08.2022

## Abstract

In recent times, the research involving the use of medicinal plants in the modern medicine has increased all over the world. Many traditional medicinal plants have been incorporated into the modern medicine to aid in the process of wound healing. One such medicinal herb is Centella asiatica. Centella asiatica has been used in traditional medicine because of its ability to heal wounds and prevent scarring. Triterpenoid, saponins, the important constituents of Centella asiatica are mainly believed to be responsible for its therapeutic action. Apart from wound healing, the herb is recommended for the treatment of various skin conditions such as leprosy, lupus, varicose ulcers, eczema, psoriasis, diarrhea, fever, amenorrhea, diseases of the female genitourinary tract and also for relieving anxiety and improving cognition. This article is about the role of Centella asiatica extract in scald burns.

**Keywords:** Centella asiatica, Wound, Scald burns.

## Introduction

Scald burns are one of the most common forms of non-accidental burn injuries. Scalds are a form of thermal burns resulting from contact of the skin with moist heat or heated fluids such as boiling water or steam. Usually in scald burns, due to the contact of the hot liquid with the epidermal layer of the skin, there is a superficial partial thickness loss of epidermis and part of the dermis. Hence most scalds are considered first or second degree burns. Healing of scald burns is a complicated process including inflammation, re-epithelialization,

granulation, neovascularization and wound contraction. Although several preparations are available for the management of scald burns there is still a necessity of researching for efficacious medicine. Epithelialization is the natural act of healing dermal tissue resulting in minimal or no scarring.<sup>5</sup> In most cases, scars occur if the depth reaches the dermis layer. When hypertrophic scar or keloid develops, it may induce itching, pain and even scar contracture.<sup>3</sup> A lot of agents have been used to improve scars such as onion extract, resveratrol in grape's skin, curcumin and

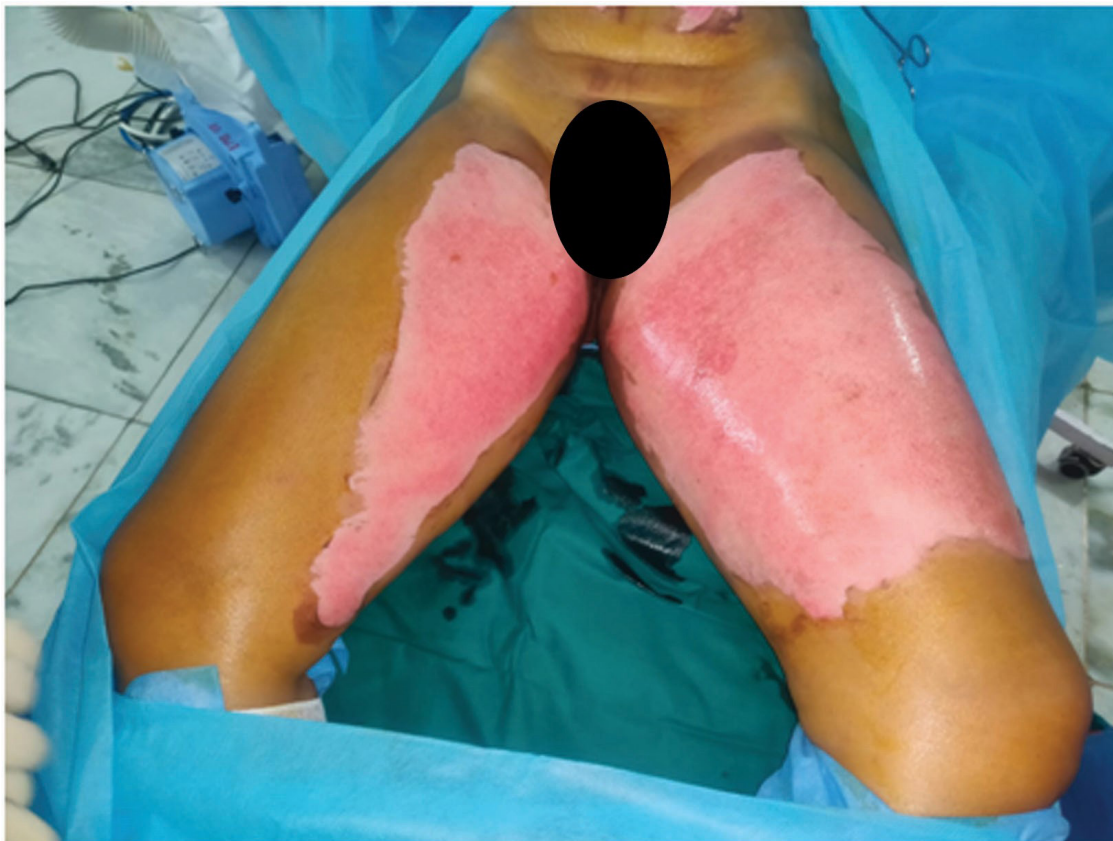

Fig. 1: A 45 year old female with first degree scald burns on her lower abdomen and anteromedial aspect of both thighs.

centella. In this article we discuss about the role of Centella asiatica extract in scald burns. The role of Centella asiatica extract in scald burns is due to its anti oxidant and anti inflammatory and collagen remodelling property.<sup>6</sup>

### Materials and Methods

This article is from the department of plastic surgery, JIPMER, Puducherry. After getting informed consent from the patient, clinical information and pictures are used in this article. A 45 year old female with no known comorbidities presented to the emergency department with alleged history sustaining scald burns by accidental spillage of hot water on her. Clinically her vitals were stable. She sustained first degree burns on her lower abdomen and anteromedial aspect of her both thighs (Figure 1). She was managed conservatively with daily cleaning and wound dressing with Cantella asiatica extract which is commercially available. Cantella asiatica extract was applied over the wound once in every 3 days for a period of 3 weeks (Figure 2 and 3)

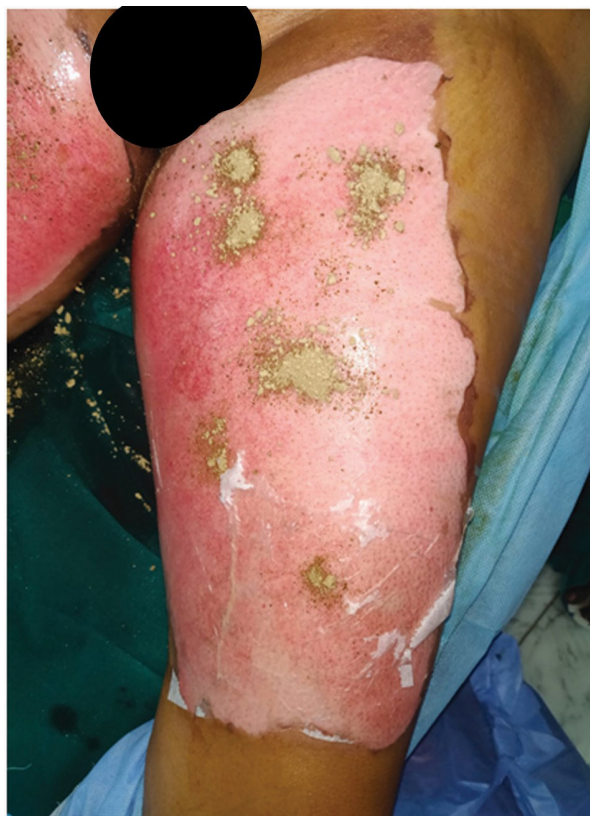

Fig. 2: Application of Centella asiatica on the wound over the anteromedial aspect of left thigh

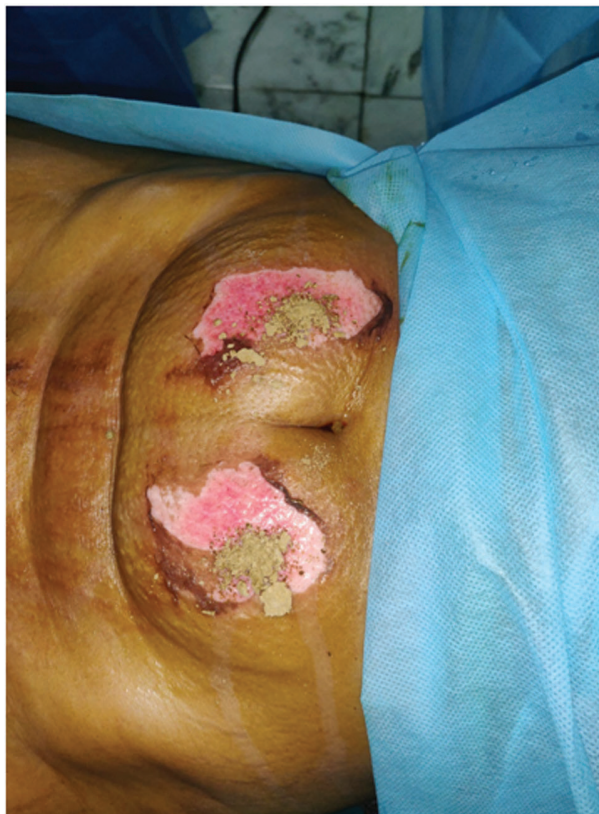

Fig. 3: Application of Centella asiatica on the wound over the lower abdomen

### Results

the scald burns wound bed preparation was done with Cantella asiatica extract and was found to be useful. It allowed for skin grafting and allowed for good uptake of the same. (figure 4-6)

### Discussion

The active compounds of Centella asiatica are pentacycliterpenes, including asiaticoside and madecassoside. In vitro studies demonstrated that asiaticoside decreases fibroblast proliferation in a dose-related manner and reduces the expression of both TGF-  $\beta$  I and TGF-  $\beta$  II at the level of transcription and translation.<sup>10</sup> Asiaticoside also slows down scar formation by increasing the activity process of SMAD 7 which is a negative regulator of TGF- $\beta$  signalling.<sup>11</sup> The other active composition, madecassoside acts by inhibiting the migration of fibroblasts.<sup>12</sup> Both active chemical substances promote C.asiatica to induce fibroblast proliferation and collagen synthesis. It involves the improvement of the tensile strength of newly formed skin and maturation of the scar by the

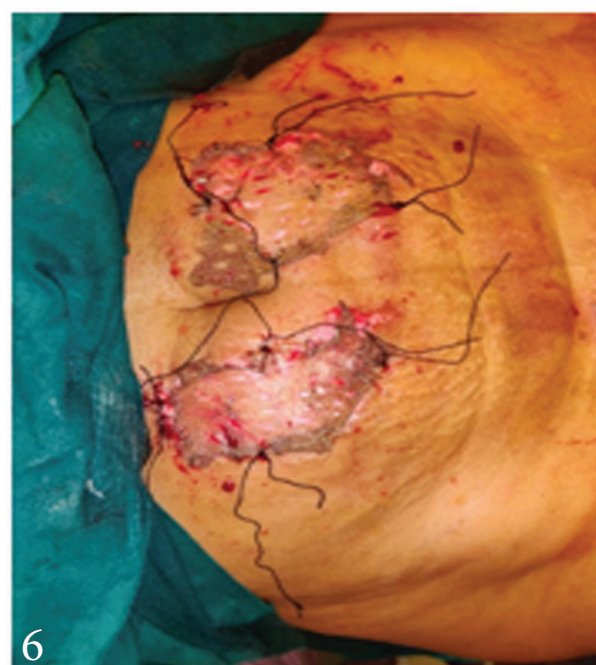
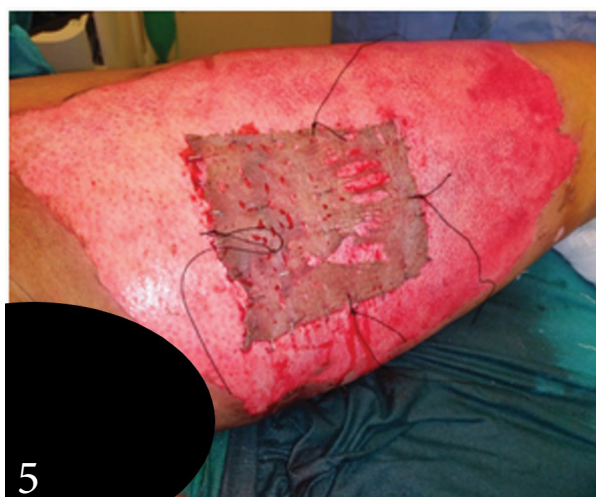
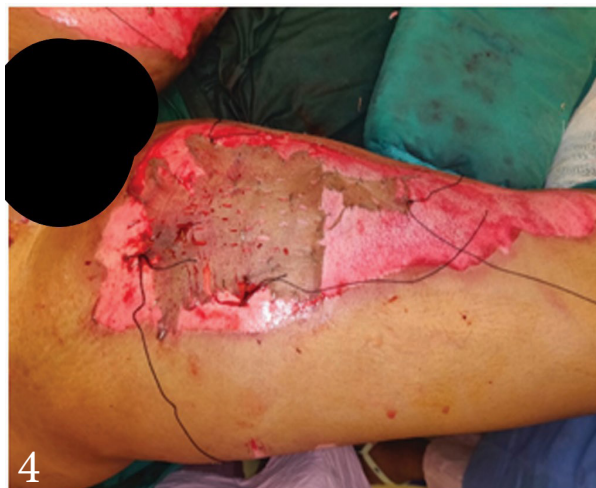
Fig. 4,5,6: Post skin grafting after using Centella for wound bed preparation

production of type I collagen.<sup>7</sup> Its advantages include that it has low adherence to the wound bed. It does not have skin irritating potential and has no effects on serum biochemical profile when applied dermally. There is limited or no scar formation.<sup>8,9</sup> However, it cannot be used in conditions like damage to skin caused by radiation therapy. It is safe when used for up to 10 weeks. It might cause itchiness and redness if used for longer period. Contact dermatitis<sup>13,14</sup> can occur sometimes. Prolonged usage has shown cause some damage to the liver. This is especially seen in people who already have a compromised liver function. Such people should avoid using Centella asiatica as it has the propensity to further impair liver function.

### Conclusion

Centella asiatica enhance wound bed preparation in patients with scald burns. Never the less, more large scale randomised control trials are needed ascertain the effects of C. asiatica extract on wound healing in patients with scald burns and its different parameters for use in clinical practice.

### References

1. Meo S. A., Al-Asiri S. A., Mahesar A. L., Ansari M. J. Role of honey in modern medicine. *Saudi Journal of Biological Sciences*. 2017;24(5):975-978.
2. Agyare C., Boakye Y. D., Bekoe E. O., Hensel A., Dapaah S. O., Appiah T. Review: African medicinal plants with wound healing properties. *Journal of Ethnopharmacology*. 2016;177:85-100.
3. van den Helder C. J. M., JorisHage J. Sense and nonsense of scar creams and gels. *Aesthetic Plastic Surgery*. 1994;18(3):307-313.
4. Somboonwong J., Kankaisre M., Tantisira B., Tantisira M. H. Wound healing activities of different extracts of Centella asiatica in incision and burn wound models: an experimental animal study. *BMC Complementary and Alternative Medicine*. 2012;12, article 103
5. Grossman A. J. A simplified technique for split-thickness skin graft donor-site care. *Plastic and Reconstructive Surgery*. 2004;113(2):796-797.
6. Bian D., Zhang J., Wu X., et al. Asiatic acid isolated from Centella asiatica inhibits TGF- $\beta$ 1-induced collagen expression in human keloid fibroblasts via PPAR- $\gamma$  activation. *International Journal of Biological Sciences*. 2013;9(10):1032-1042.
7. Dang C. M., Beanes S. R., Lee H., Zhang X., Soo C., Ting K. Scarless fetal wounds are associated with an increased matrix metalloproteinase-to-tissue-derived inhibitor of metalloproteinase ratio. *Plastic and Reconstructive Surgery*. 2003;111(7):2273-2285.
8. Ju-Lin X., Shao-Hai Q., Tian-Zeng L., et al. Effect of asiaticoside on hypertrophic scar in the rabbit ear model. *Journal of Cutaneous Pathology*. 2009;36(2):234-239.
9. Chuangsuwanich A., Arunakul S., Kamnerdnakta S. The efficacy of combined herbal extracts gel in reducing scar development at a split-thickness skin graft donor site. *Aesthetic Plastic Surgery*. 2013;37(4):770-777.
10. Tang B., Zhu B., Liang Y., et al. Asiaticoside suppresses collagen expression and TGF- $\beta$ /Smad signaling through inducing Smad7 and inhibiting TGF- $\beta$ RI and TGF- $\beta$ RII in keloid fibroblasts. *Archives of Dermatological Research*. 2011;303(8):563-572.
11. Qi S. H., Xie J.-L., Pan S., et al. Effects of asiaticoside on the expression of Smad protein by normal skin fibroblasts and hypertrophic scar fibroblasts. *Clinical and Experimental Dermatology*. 2008;33(2):171-175.
12. Wu F., Bian D., Xia Y., et al. Identification of Major Active Ingredients Responsible for Burn Wound Healing of Centella asiatica Herbs. *Evidence-Based Complementary and Alternative Medicine*. 2012;2012:13.
13. Gomes J., Pereira T., Vilarinho C., Duarte M. D. L., Brito C. Contact dermatitis due to Centella asiatica. *Contact Dermatitis*. 2010;62(1):54-55.
14. Hafeez F., Maibach H. An overview of parabens and allergic contact dermatitis. *Skin Therapy Letter*. 2013;18(5):5-7.

