

Application of Hybrid Reconstruction Ladder in Post Burn Contracture

Jacob Antony Chakiath¹, Ravi Kumar Chittoria²

How to cite this article:

Jacob Antony Chakiath, Ravi Kumar Chittoria/ Application of Hybrid Reconstruction Ladder in Post Burn Contracture/ RFP Journal of Dermatology 2022;7(2):61-66.

ABSTRACT

Multidisciplinary team has effectively adapted advanced reconstructive techniques merged with regenerative medicine modalities to improve outcomes. These treatments combine traditional reconstruction measures with regenerative medicine applications and has been termed 'hybrid reconstructions'. The hybrid reconstruction model aids in maximizing the function while minimizing the disability and morbidity associated with traditional reconstruction.

Keywords: Hybrid reconstructive ladder; Burns; Contracture.

INTRODUCTION

The reconstructive ladder is a concept familiar to all plastic surgeons. Although it has undergone gradual evolution over time, the basic concept of methods of reconstruction ranked by complexity has been preserved and propagated in multiple forms. Most descriptions start with closure by secondary intention, followed by direct closure, local flaps, and distant flaps. Various authors have made finer distinctions among local, regional, and free flaps, and inserting tissue expansion somewhere in the spectrum.

The complex injury pattern has initiated efforts to create new and innovative techniques in

tissue regeneration. Multidisciplinary team has effectively adapted advanced reconstructive techniques merged with regenerative medicine modalities to improve outcomes. These treatments combine traditional reconstruction measures with regenerative medicine applications and has been termed 'hybrid reconstructions'.¹

The hybrid reconstruction model aids in maximizing the function while minimizing the disability and morbidity associated with traditional reconstruction. In aim of this study is to apply the hybrid reconstructive mole in our patient with a non-healing wound in the left knee.

MATERIALS AND METHODS

The study was carried out in a tertiary care hospital in South India after receiving approval from departmental ethical committee. The subject was a 28 yr old female patient with a history of self-immolation by kerosene oneyears back sustained burn over neck, right upper limb, face and back. It involved 30% of total body surface area which was second degree both superficial and deep burn following which she developed a post burn contracture (Fig. 1). A hybrid reconstructive ladder

Author Affiliation: ¹Senior Resident, Department of Plastic Surgery, ²Professor & Head of IT Wing and Telemedicine, Department of Plastic Surgery & Telemedicine, Jawaharlal Institute of Postgraduate Medical Education and Research, Pondicherry 605006, India.

Corresponding Author: Ravi Kumar Chittoria, Professor & Head of IT Wing and Telemedicine, Jawaharlal Institute of Postgraduate Medical Education and Research, Pondicherry 605006, India.

Email: drchittoria@yahoo.com

Received on: 27.08.2022

Accepted on: 21.09.2022

approach was done which includes application of autologous platelet rich plasma (Fig. 2), low level

laser therapy (Fig. 3), post burn contracture release and skin grafting (Fig. 4).

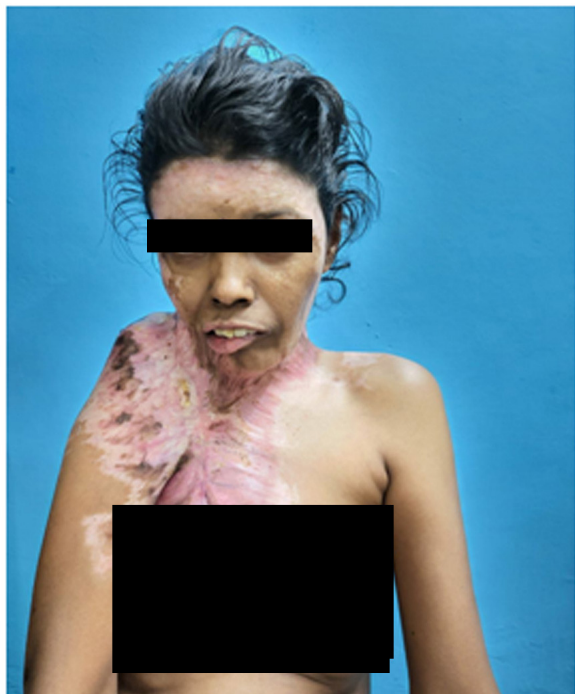


Fig. 1: Post burn contracture at the time of admission

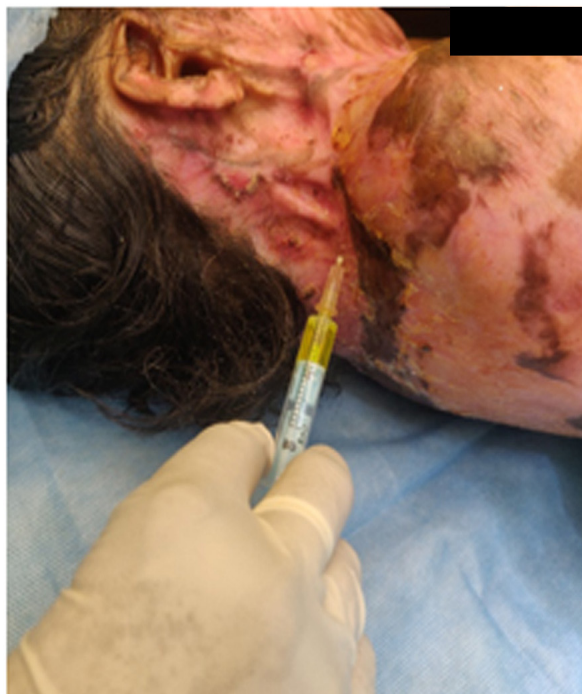

Fig. 2: Autologous platelet rich plasma

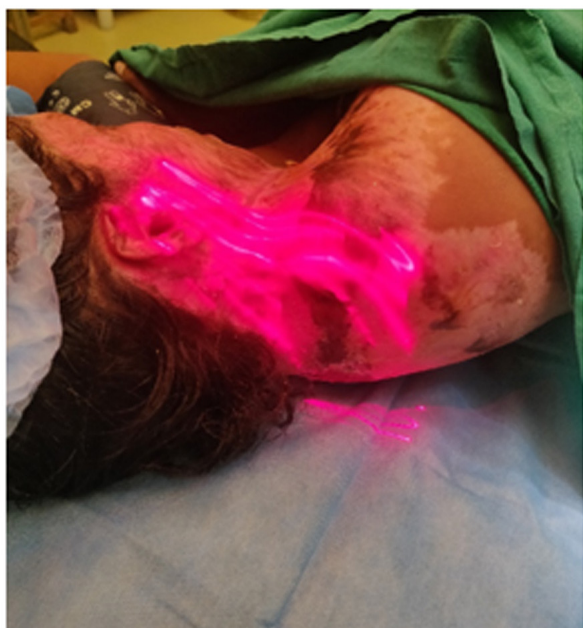

Fig. 3: Low level laser therapy

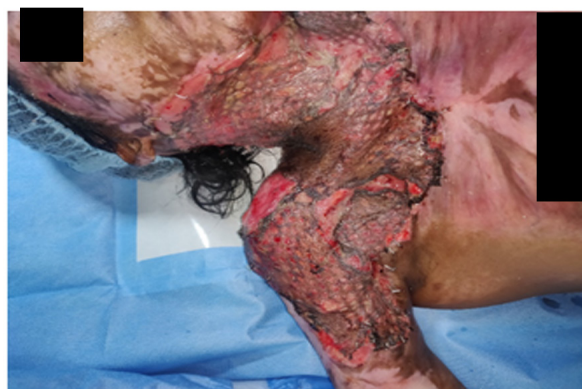


Fig. 4: Contracture release and skin grafting.

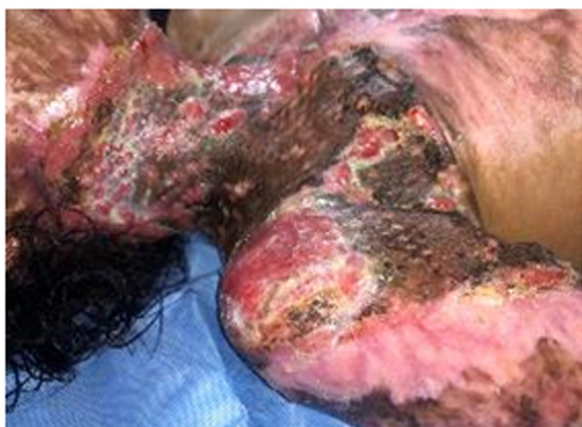

Fig. 5: Skin graft take after hybrid reconstruction ladder approach

RESULTS

In our patient, the hybrid reconstructive ladder approach helped in a good wound bed preparation, helped in good graft take (Fig. 5) and also helped to decrease the duration of the hospital stay.

DISCUSSION

The reconstructive ladder is an improper extension of a well-known and appropriate concept of a wound closure ladder. It has its own limitations. Although there is virtue in using the simplest solution to a given problem, at times more complex methods of reconstruction may be preferred, even when simpler methods can achieve wound closure. To address these concerns, several modifications to the reconstructive ladder have been proposed. Mathes and Nahai² suggested the “reconstructive triangle,” which consisted of tissue expansion, local flaps, and microsurgery.

Gottlieb and Krieger³ introduced the “reconstructive elevator” which, although still acknowledging the concept of increasing levels of complexity, suggests the freedom to ascend directly to the appropriate level if necessary.

Wong and Niranjana⁴ recommended that the rungs be thought of as stages in the development

of surgical skills, emphasizing that the difficulty of a reconstructive problem is related to the skill and training of the treating surgeon. Erba et al.⁵ integrated the concepts of surgical risk, technological complexity, and surgical complexity into a matrix to help organize the various reconstructive methods and provide a framework for further discussion.

The reconstructive grid⁶ is a dynamic construct that takes into account the multiple reconstructive options available to the plastic surgeon. It also takes into consideration factors that help the reconstructive surgeon determine the best possible option to achieve the three reconstruction goals, namely, form, function, and aesthetics. The factors that aid the judgment of a reconstruction specialist, including wound complexity, surgeon skill, resources (and technology) available, and patient requests, form the boundaries of the reconstructive grid.

		Surgeons' Skills						
Resources available	Bionengineered tissue	-	-	-	-	Supercirculotomy	-	Patient requests
	Oxygen therapy	-	-	-	-	Robotic Microsurgery	-	
	Extracellular matrix	-	-	Tissue expansion	-	Functional tissue transfer	-	
	External tissues expansion	-	-	Pectorator flaps	Islanded flaps	Perforator free flaps	Abdominal wall transplant	
	Cell therapy & Growth Factors	Gene therapy & Tissue Engineering	Composite graft	Keystone flaps	Composite flap	Composite free flap	Face transplant	
	NPWT	In-utero reconstruction	Corrponent graft	Dermal flaps	Corrponent flaps	Component free flap	Hard transplant	
	Secondary healing	Primary closure	Craft	Local flap	Distant flap	Free flap	Vascular Composite Allotransplant	
		Wound complexity						

Source @ Viewpoints-Reconstruction 2.0: Restructuring the Reconstructive Ladder in Journal on Plastic and Reconstructive Surgery

The bottom row of the reconstructive grid houses the traditional modalities of reconstruction that are available in the ladder and elevator and the newer reconstruction modality, vascular composite allotransplant which, though absent in the reconstructive ladder, is mentioned in the modified reconstructive elevator.⁷ The boxes above these primary reconstruction modalities show techniques available within each modality of reconstruction. The spatial nature of the reconstructive grid permits the specialist to select multiple options for a given defect. The reconstructive grid includes newer wound healing techniques such as bioengineered

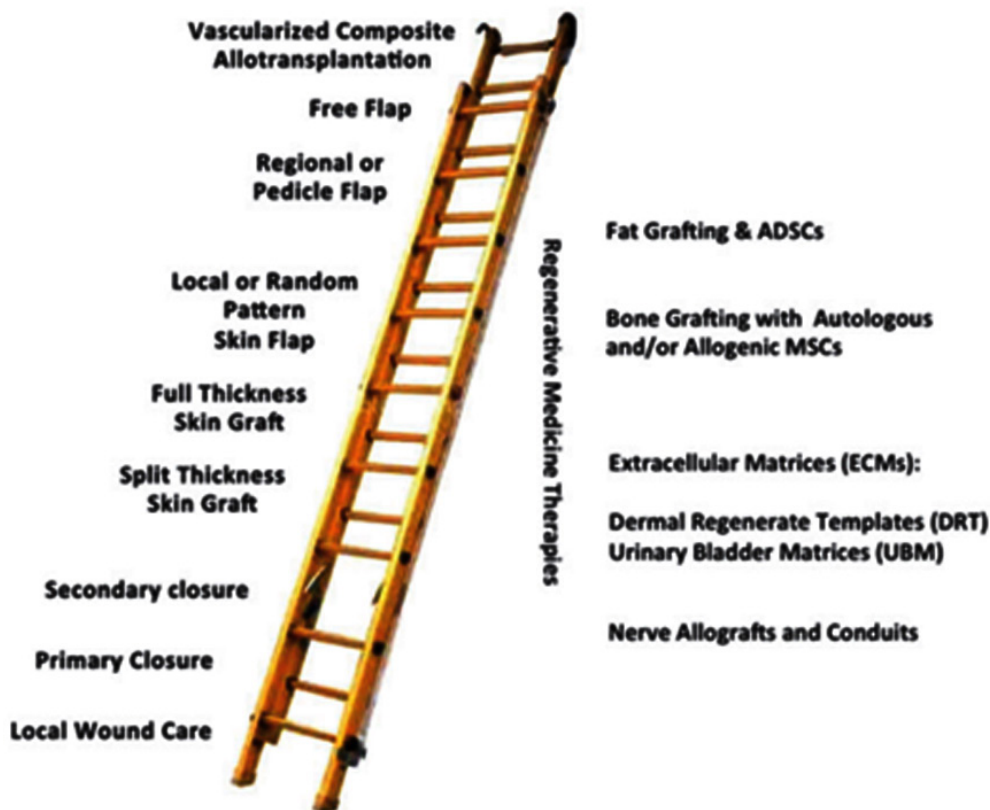skin, cell therapies (e.g., adipocyte derived stem cells), and also still developing reconstruction techniques including tissue engineering⁸ and gene therapies.⁹ The blank boxes represent available space to accommodate newer techniques as they arise, under each modality, thus making the grid future ready.

The standard treatments for extremity injuries with massive composite tissue loss (bone, skin, soft tissue, nerves) require a spectrum of therapies. These therapies include extremity amputation, limb shortening to assist in residual limb soft tissue coverage, free tissue transfers, pedicle flaps, local

flaps, skin grafting, bone reconstruction, nerve repair or reconstruction and vascular repair. The traditional therapies may subtract from an already decreased functional capacity and may result in significant donor site morbidity. Revised amputations may have non-pliable and/or nondurable surface areas prone to erosive wear with prosthetic use. Furthermore, the multiple limb injuries and amputations seen in combat casualties typically involve expanded zones of injury that

extend beyond the directly affected extremities that can complicate reconstructive efforts.⁷ Furthermore, in the multiple extremity injured service member, the common accepted donor sites for autologous tissues become increasingly limited.

Consequently, this has led to increased use of regenerative medicine modalities to enhance tissue regeneration and improve reconstructive outcomes. Hence the term "Hybrid Reconstruction Ladder". (Fig. 5)



Source @ Article Plastic Surgery Challenges in War Wounded II: Regenerative Medicine

The reconstructive ladder was a term coined by plastic and reconstructive surgeons to describe levels of increasingly complex management of soft tissue wounds.¹⁰ Theoretically, the surgeon would utilize the lowest rung of the ladder – that is, the simplest reconstruction technique – to address a clinical reconstructive problem.¹¹ The reconstructive surgeon would move up the ladder as a more complex or suitable method was required for a given reconstruction problem. A hybrid reconstructive ladder that augments the traditional reconstructive ladder with regenerative medicine modalities.¹² There were improved outcomes at each rung on the reconstruction ladder and these modalities may allow for the expansion

of indications for each rung on the reconstruction ladder.

The study effectively employed dermal regenerates, soft tissue regeneration techniques, biologic scaffolds, fat grafting techniques and adipose-derived stem cells in a number of reconstructions.¹³

Indications

The utilization of high concentration allogeneic mesenchymal stem cell (MSCs) for segmental and severely comminuted osseous deficits.¹⁴

The dermal regeneration templates for preparation and to improve the durability of wound beds for skin grafting.

The biologic scaffolds such as urinary bladder matrix to provide for soft tissue regeneration, surgical wound bed preparation and muscle regeneration.¹⁵

The decellularized allograft nerves to serve as nerve regeneration templates or conduits for segmental nerve defects in patients lacking adequate auto-graft nerve sources.

ADVANTAGES

The dermal regenerates have reduced skin erosion rates compared with those patients with skin grafting alone.

It has reduced wound healing issues surrounding the prosthetic wear sites by increasing durability.

Orthopedic union rates and nonunion rates have been reduced by adjunctive use of these measures when compared with traditional reconstructions without bony regenerates.¹⁶

These regenerative techniques have addressed bony healing and wound healing as well as salvage failed cases, which includes improving limb salvage rates, amputation preservation of length, and carefully selected cases.^{17,18}

Even in patients with limb loss and multiple extremity amputations, using these modalities has allowed residual limbs to be preserved at a length suitable for prosthetic fitting.¹⁹

It may be extracted to treat lesser severe injuries from trauma, burn or oncologic cases using hybrid reconstructions.^{20,21}

Disadvantages

High cost

Requirement of high infrastructure

Training to learn the skill.

CONCLUSION

Hybrid Reconstructive Ladder approach has a definitive role in post burn contracture. The hybrid reconstruction model aids in maximizing the function while minimizing the disability and morbidity associated with traditional reconstruction in post burn contracture.

Conflicts of interest: None

Financial support and sponsorship: None

REFERENCES

1. Fleming ME, Bharmal H, Valerio I. Regenerative medicine applications in combat casualty care. *Regen Med* 2014;9:179-190.
2. Mathes SJ, Nahai F. *Reconstructive Surgery: Principles, Anatomy & Technique*. Vol. 2. New York: Churchill Livingstone; St. Louis: Quality Medical; 1997.
3. Gottlieb LJ, Krieger LM. From the reconstructive ladder to the reconstructive elevator. *PlastReconstr Surg*. 1994;93:1503- 1504.
4. Wong CJ, Niranjana N. Reconstructive stages as an alternative to the reconstructive ladder. *PlastReconstr Surg*. 2008;121: 362e-363e.
5. Erba P, Ogawa R, Vyas R, Orgill D. The reconstructive matrix: A new paradigm in reconstructive plastic surgery. *PlastReconstr Surg*. 2010;126:492-298.
6. Mohapatra, Devi Prasad M.Ch.; Thiruvoth, Friji Meethale M.Ch. *Reconstruction 2.0: Restructuring the Reconstructive Ladder, Plastic and Reconstructive Surgery: March 2021-Volume 147 - Issue 3 - p 572e-573e*.
7. Vedder NB, Wei FC, Mardini S, eds. *Problem analysis in reconstructive surgery: Reconstructive ladders, elevators, and surgical judgment*. In: *Flaps and Reconstructive Surgery*. 2017;2nd ed. Toronto: Elsevier; 1-5.
8. Bernstein JL, Cohen BP, Lin A, Harper A, Bonassar LJ, Spector JA. Tissue engineering auricular cartilage using late passage human auricular chondrocytes. *Ann Plast Surg*. 2018;80(Suppl 4):S168-S173.
9. Roh DS, Li EB, Liao EC. CRISPR craft: DNA editing the reconstructive ladder. *PlastReconstr Surg*. 2018;142:1355-1364.
10. Owens BD, Kragh JF Jr, Macaitis J, Svoboda SJ, Wenke JC. Characterization of extremity wounds in Operation Iraqi Freedom and Operation Enduring Freedom. *J. Orthop. Trauma* 21(4), 254-257 (2007).
11. Fleming M, Waterman S, Dunne J, D'Alleyrand JC, Andersen RC. Dismounted complex blast injuries: patterns of injuries and resource utilization associated with the multiple extremity amputee. *J. Surg. Orthop. Adv.* 21(1), 32-37 (2012).
12. Masini BD, Waterman SM, Wenke JC, Owens BD, Hsu JR, Ficke JR. Resource utilization and disability outcome assessment of combat casualties from Operation Iraqi Freedom and Operation Enduring Freedom. *J. Orthop. Trauma* 23(4), 261-266 (2009).
13. Belmont PJ Jr, Thomas D, Goodman GP et al. Combat musculoskeletal wounds in a US Army Brigade Combat Team during operation Iraqi Freedom. *J. Trauma* 71(1), e1-e7 (2011).
14. Deal DN, Griffin JW, Hogan MV. Nerve conduits for nerve repair or reconstruction. *J. Am. Acad. Orthop. Surg.* 20(2), 63-68 (2012).

15. Hudson TW, Zawko S, Deister C et al. Optimized acellular nerve graft is immunologically tolerated and supports regeneration. *Tissue Eng.* 10(11-12), 1641-1651 (2004).
16. Whitlock EL, Tuffaha SH, Luciano JP et al. Processed allografts and type I collagen conduits for repair of peripheral nerve gaps. *Muscle Nerve* 39(6), 787-799 (2009).
17. Mackinnon SE, Doolabh VB, Novak CB, Trulock EP. Clinical outcome following nerve allograft transplantation. *Plast. Reconstr. Surg.* 107(6), 1419-1429 (2001).
18. Ficke JR, Obremskey WT, Gaines RJ et al. Reprioritization of research for combat casualty care. *J. Am. Acad. Orthop. Surg.* 20(Suppl. 1), S99-S102 (2012). • Discusses the research gaps and the need for reprioritization of research in combat casualty care.
19. Turner NJ, Badylak SF. Biologic scaffolds for musculotendinous tissue repair. *Eur. Cell Mater.* 25, 130-143 (2013).
20. Siemionow M, Uygur S, Ozturk C, Siemionow K. Techniques and materials for enhancement of peripheral nerve regeneration: a literature review. *Microsurgery* 33(4), 318-328 (2013).
21. Tenenhaus M, Rennekampff HO. Surgical advances in burn and reconstructive plastic surgery: new and emerging technologies. *Clin. Plast. Surg.* 39(4), 435-443 (2012).

