

Accessory Foramina Transversaria in Cervical Vertebrae: Surgico-Clinical Significance

Panchal Padamjeet*, Prasad Bheem*, Singh Shilpa**

Abstract

Introduction: The cervical vertebrae are cranially placed, moveable vertebrae in the human body. The characteristic feature of these vertebrae are the presence of a Foramen Transversarium (FT) in each lateral mass. A plexus of sympathetic nerves surrounding the Vertebral Artery (VA) and Vertebral Veins (VV) passes through the FT. The variable number and size of FT may lead to clinically significant conditions. It may be due to variable course of the VA which implicates an embryological basis. *Aims:* The objective of the present study is to find out the incidence of accessory FT in the cervical vertebrae and its morphological and clinical significance. *Material and Methods:* There were 117 dried cervical vertebrae available in the Department of Anatomy, AII India Institute of Medical Sciences, Patna, Bihar. They were macroscopically studied to find variations in the number of FT. *Results:* Out of 117 cervical vertebrae accessory FT were found in 25 vertebrae (21.3%). The accessory FT were unilateral in 15 vertebrae (12.8%) and bilateral in 10 vertebrae (8.7%). The unilateral foramina were more common than the bilateral one. The accessory FT were smaller and posteriorly placed compared to the regular FT. *Conclusions:* The accessory FT are of importance to radiologists and surgeons operating on the cervical spine.

Keywords: Cervical Vertebrae; Foramina Transversaria; Vertebral Artery; Vertebral Vein.

Introduction

The cervical vertebrae are identified by the presence of a Foramen Transversarium (FT) in each lateral process composed of fused costal elements with its true transverse process. The FT normally transmits second part of Vertebral Artery (VA), Vertebral Veins (VV) and sympathetic fibers from the cervicothoracic ganglion (vertebral nerve) [1]. The seventh cervical vertebrae have smaller FT which transmits only the VV. Sometimes, the vertebral vessels and nervous plexus may get trapped between these two parts, causing formation of accessory FT that may affect the normal course and size of VA [2]. The objective of the present study is to find out the incidence of accessory FT in

the cervical vertebrae and its morphological and clinical significance.

Material and Methods

The study included 117 dried human cervical vertebrae available in Department of Anatomy, AII India Institute of Medical Sciences, Patna, Bihar. Among them there were 69 typical cervical vertebrae and 48 atypical cervical vertebrae. Vertebrae with congenital anomalies and pathological changes were excluded from the study. The vertebrae were macroscopically examined to find out presence of accessory FT. Vertebrae having accessory FT were photographed. The data was compiled and analyzed using Microsoft Excel 2013 software.

Results

Accessory FT were observed in 25 vertebrae. Incidence was calculated to be 21.3%. The accessory FT were unilateral in 15 vertebrae (12.8%), present

Author's Affiliation: *Assistant Professor **Junior Resident, Department of Anatomy, AII India Institute of Medical Sciences, Phulwari Sharif, Patna, Bihar-801507, India.

Corresponding Author: Panchal Padamjeet, Assistant Professor, Department of Anatomy, AII India Institute of Medical Sciences, Phulwari Sharif, Patna, Bihar-801507.
E-mail: drpadamjeetp@aiimspatna.org

Received | 17.12.2016, Accepted | 28.12.2016

mostly on the left side. They were present bilaterally in 10 vertebrae (8.7%). Unilateral FT was more common than the bilateral FT. The accessory foramina were smaller compared to the regular foramina. The accessory foramina were mostly seen in the lower cervical vertebrae (C4, C5, C6 and C7) as shown in Table 1. The maximum number of FT were observed in cervical vertebrae C6. In atypical cervical vertebrae there were five C7 vertebrae showing double FT. All

the accessory foramen were posterior to the main FT. One of the vertebrae showing unilateral accessory FT had triple FT on the right side, one accessory foramina was posteriorly placed and the other accessory foramina was posterolaterally placed to the main FT. Incidence being 0.8%. In atlas and axis no accessory FT were found and no vertebra was found with bilateral triple accessory FT. Moreover, no vertebra were found with absence of FT.

Table 1: Incidence of double FT in various cervical vertebrae

Sr. No.	Type of vertebrae	Observed vertebrae	Double FT (U/L)		Double FT (B/L)
			Right	Left	
1	C1	16	0	0	0
2	C2	17	0	0	0
3	C3-C6	69	5	7	7
4	C7	15	0	2	3
5	TOTAL	117	5	9	10

C1: First Cervical vertebrae, C2: Second Cervical vertebrae, C3-C6: Third Cervical vertebrae to sixth cervical vertebrae, FT: Foramen Transversaria, U/L: unilateral, B/L: bilateral.

Table 2: Comparison between the various studies done on the accessory FT

Author(s)	Sample size (No.)	Accessory foramina (%)	Population
Taitz et al, 1978	480	7%	Indian
Nagar, 1999	1388	8.6%	Roman-Byzantine Jews
Das, 2005	132	1.5%	Indian
Sharma A, 2010	200	8%	Indian
Muralimanju BV, 2011	363	1.6%	Indian
Kaya, 2011	262	22.7%	Jewish
Chaudhary ML, 2013	133	23.15%	Indian
Yadav Y, 2014	120	6.6%	Indian
Gonsai V, 2015	200	20%	Indian
Sangari SK, 2015	71	24%	American
Dofe MY, 2015	60	41%	Indian
Nayak G, 2016	133	6%	Indian
Verma P, 2016	200	8%	Indian
Present study	117	21.3%	Indian

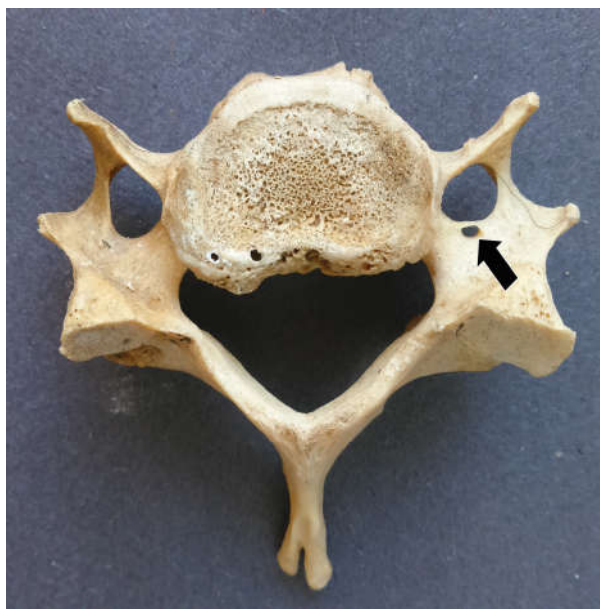

Fig. 1: Typical cervical vertebra showing unilateral double FT

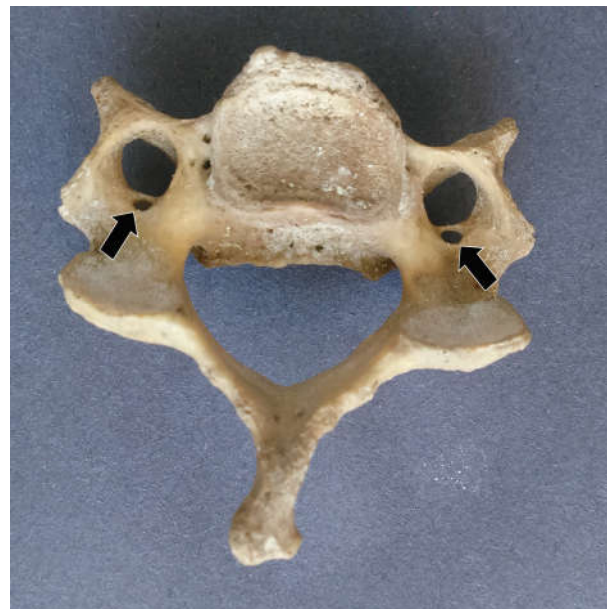

Fig. 2: Typical cervical vertebra showing bilateral double FT.

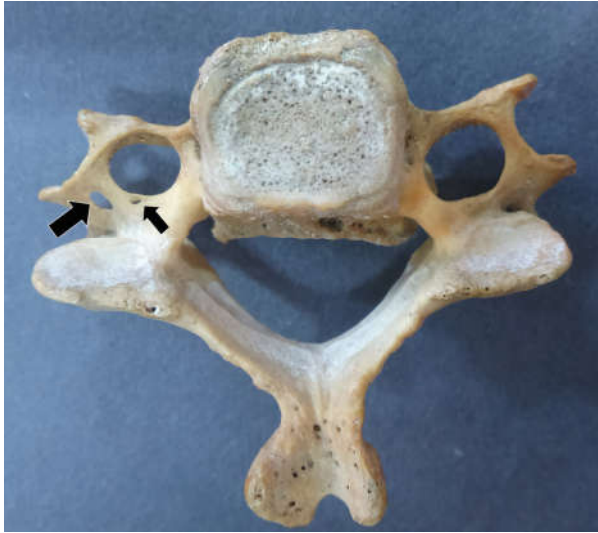

Fig. 3: Typical cervical vertebra (inferior aspect) showing triple FT.

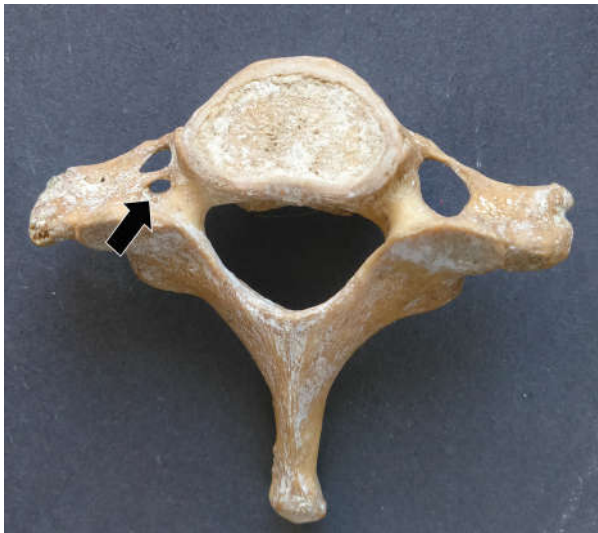

Fig. 5: Atypical cervical vertebra showing bilateral double FT.

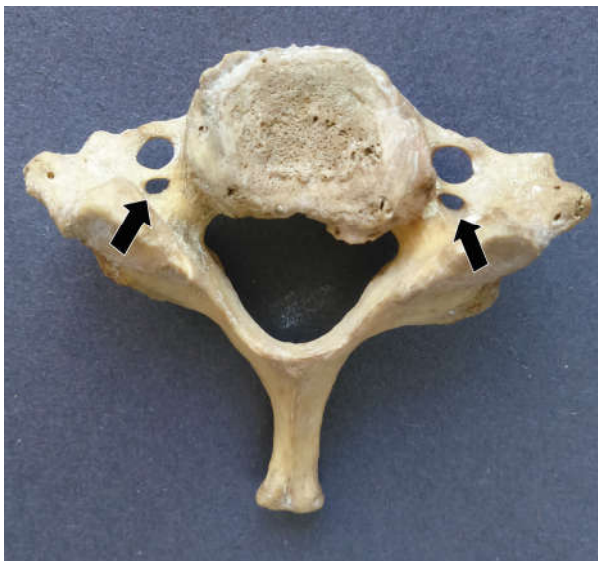


Fig. 4: Atypical cervical vertebra showing unilateral double FT.

Discussion

The VA constitute one of the vascular components of FT of the upper six cervical vertebrae. The VA is developed from the fusion of the longitudinal anastomoses that link the cervical intersegmental arteries which arises from the dorsal aorta. These inter segmental arteries regress except for the seventh intersegmental artery which persists and forms the proximal portion of the subclavian artery which gives rise to the VA [3]. Sim et al described that the persistence of a portion of the primitive dorsal aorta with two intersegmental arteries may give rise to VA duplication [4]. Taitz et al suggested that the vertebral vessels may be considered as one of the factors influencing the formation of FT. In contrast accessory FT can be useful in evaluating the variant vertebral vessels [2].

The anatomical variation of the FT is also very important to neurologists as the compression of VA may presents clinically with neurological symptoms. These variations can lead to the compression of the VA, particularly during movements of the head leading to vascular insufficiency. This can manifest clinically as headache and fainting attacks [5]. Compression of the VA may lead to hearing disturbances also as it supplies the internal ear as well [6].

In the present study accessory FT were found in 21.3% cases which is comparable to the findings of Kaya et al(2011), Chaudhari ML et al (2013) and Gonsai et al(2015) [7,8,9]. Sangari SK, 2015 examined only the typical cervical vertebrae and reported the presence of double FT in 24% cases of 71 typical cervical vertebrae [10]. Zibis et al (2016) also observed double foramina in 14 vertebrae (13.72 %). In seven vertebrae, the duplication was bilateral (6.86 %) [11].

Triple foramen is a very rare variation and seems to be the result of double rib bone element on the same side fusing to the original transverse process [12]. In the present study there was one typical cervical vertebrae with triple FT on the right side (0.8%). Taitz et al found one vertebra with a triple foramen on the left side [2]. Murlimanju et al. found one vertebrae with triplication of FT (0.3%) [13]. Zibia also found a triple FT among 102 vertebrae, with an incidence of 0.98% [11].

During cervical spine surgeries, while performing posterior cervical procedures which may involve instrumentation or screwing in the cervical spine, the VA intactness is highly important as minor lesions can lead to severe and fatal hemorrhage.

Therefore these findings should be kept in mind during surgical intervention. It is also important to the radiologists for the proper interpretation of X-ray and CT-scan [7].

Conclusion

In the present study 21.3% of cervical vertebrae showed accessory FT. Among them the unilateral accessory FT was more common than the bilateral variety. The accessory foramina were mostly observed in the lower cervical vertebrae. These anatomical variations and morphology of the FT is useful in the operations involving spine surgeries. It is also of great value to the radiologists in the interpretation of X-ray films and CT-scans.

Conflict of Interest

No conflict of interest.

References

- Susan Standring, Gray's Anatomy, 40th Ed., The anatomical basis of clinical practice, Churchill Livingstone, p.718.
- Taitz C, Nathan H and Arensburg B. Anatomical observation of the foramina transversaria. J. Neurol Neurosurg Psychiatr 1978; 41:170-176.
- Loneta C and Omojola MF. Angiographic demonstration of bilateral duplication of extra cranial vertebral artery unusual course and review of literature. Am J Neuroradiol. 2006; 27:1304-1306.
- Sim E, Vaccaro AR, Berzlanovich A, Thaler H and Ullrich CG. Fenestration of the extracranial vertebral artery: Review of the literature. Spine. 2001; 26: 139-142.
- Caovilla HH, Gananca MM, Munhoz MS and Silva ML. Síndrome Cervical Quadros Clínicos Otorrinolaringológicos Mais Comuns. Athenue, Sao Paulo, 2000; 3(11):95-100.
- Romanov VA, Miller LG and Gaevyi MD. The effect of the vertebral nerve on circulation in the inner ear (Cochlea). Biull Eksp Biol Med. 1973; 75:10-12.
- Kaya S, Yilmaz ND, Pusat S, Kural C, Krik A and Izei Y. Double foramen transversarium variation in ancient byzantine cervical vertebrae; Preliminary report of anthropological study. Turkish Neurosurgery. 2011; 21(4):1534-1538.
- Chaudhari ML, Maheria PB and Bachuwar SP. Double foramen transversarium in cervical vertebra: morphology and clinical importance. Indian J Basic Appl Med Res. 2013; 8:1084-1088.
- Gonsai V, Jadav J and Shah HR. Variations in Transverse Foramina of Cervical Vertebrae: Morphology & Clinical Importance. BJKines-NJBAS 2015; 7(2):6-9.
- Sangari SK, Dossous P, Heineman T and Mtui EP. Dimensions and Anatomical Variants of the Foramen Transversarium of Typical Cervical Vertebrae. Anatomy Research International. 2015; (2015):1-5.
- Zibis AH, Mitrousias V, Baxevanidou K, Hantes M, Karachalios T and Arvanitis D. Anatomical variations of the foramen transversarium in cervical vertebrae: findings, review of the literature, and clinical significance during cervical spine surgery. Eur Spine J. 2016; 25(12):4132-4139.
- Kimura K, Konishi M, Hu SY. Shape and size of the transverse foramina in Japanese. Okajimas Folia Anat Jpn. 1985; 62:123-132.
- Murlimanju BV, Prabhu LV, Shilpa K, Rai R, Dhananjaya KVN and Jiji PJ. Accessory transverse foramina in the cervical spine: incidence, embryological basis, morphology and surgical importance. Turk Neurosurg. 2011; 21:384-387.
- Nagar Y, Taitz C and Reich R. What can we make of these fragments? Excavation at "Mamilla" Cave, Byzantine Period, Jerusalem. Int J Osteoarcheol. 1999; 9:29-38.
- Das S, Suri R and Kapur V. Double Foramina Transversaria: An Osteological Study with Clinical Implications. Int Med J. 2005; 12:311-313.
- Sharma A, Singh K, Gupta V and Srivastara S. Double foramen transversarium in cervical vertebra an osteological study. J Anat Soc India. 2010; 59:229-231.
- Yadav Y, Goswami P and Bharihoke P. An Osteological study of Foramen Transversarium: Variations and Clinical Aspects. Journal of Evolution of Medical and Dental Sciences. 2014; 3(68): 14562-14566.
- Dofe MY, Kasote AP and Meshram MM. The Study of Cervical Vertebrae Showing Variational Presentation of Foramen Transversarium. Int J Anat Res. 2015; 3(2):1128-32.
- Nayak G, Mohanty BB, Baisakh P, Das SR, Panda SK and Chinara PK. Study of Accessory Foramina Transversaria in Cervical Vertebrae and Their Surgical and Morphological Importance. Research Journal of Pharmaceutical, Biological and Chemical Sciences. 2016; 7(3):1370-1373.
- Verma P, Seema and Piplani M. Study of Incidence of Accessory Foramina in Cervical Vertebrae in North Indian Population. Int J Anat Res. 2016; 4(2):2316-2319.