

A Morphometric Study of Infraorbital Foramen and Its Laterality in Dry Adult Skulls North Karnataka Population

Dnyaneshwar*, Vijaynath Itagi**, Sudhakara Babu Chelli***, Suresh P. Desai****

Abstract

Background: Infraorbital foramen is located in the maxilla and it conveys infraorbital vessels and nerves, the knowledge of its morphometry and variations is therefore mandatory to do therapeutic infraorbital nerve block or any surgical procedures. **Aims & Objective:** To study morphometry of infraorbital foramen and its laterality in dry adult skulls of north Karnataka population. **Materials and Methods:** In this study we examined 100 infraorbital foramina and measured its distance with bony features adjacent to it and the shape, presence of accessory foramina were observed. The infraorbital foramen was the landmark from which the distance between the following bony structures were examined; Nasion (NAS), Zygomatico-maxillary suture (ZMS), Anterior nasal spine (ANS), and the distance between the inferior orbital rim (IOR) to optic canal (OC), infraorbital foramen (IOF), inferior and superior orbital fissure (IF & SF). The average mean and standard deviation were calculated for every measurement. Paired t-test was used to compare the parameters between sides and gender for each measurement. **Results:** The most common shape of infraorbital foramen found in the present study is oval (39%) followed by semilunar (27%). Round shaped foramen was found in 22% of skulls, triangle shaped foramen was found in 12% and accessory foramina were present in 11% of the skulls. In the present study, we found triangle shaped foramen in 12% skulls and also the number of accessory foramina was found to be higher which emphasise the need to take ethnicity into account as triangle shaped foramen is unique in south Indian population as affirmed by previous authors. **Conclusion:** The results show significance with respect to gender and side which makes the knowledge of its morphometry obligatory for surgical procedures.

Keywords: Infraorbital Foramen; Infraorbital Nerve Block; South north karnataka Population; Accessory Foramina.

Introduction

The infraorbital foramen lies bilaterally in the maxillary bone, below the edge of orbital cavity. The infraorbital nerves and vessels pass through this foramen. The infraorbital nerve is sensory and it lengthens the maxillary nerve, which crosses the infraorbital foramen and branches to supply the skin over the upper portion of the cheek, maxillary sinus

mucosa, maxillary incisor, canine, premolar teeth, adjacent gum portion, skin over the lower eye lid, conjunctiva, part of the nose, part of the skin and mucosa of the upper lip [1]. Its anatomy varies according to the location, shape, size, laterality and incidence of accessory foramina.

The study of the infraorbital foramen is significant in local anaesthesia procedures, in maxillofacial surgeries and consequently in protection against procedural neuro-vascular injuries. Therapeutic infraorbital nerve blocks are used in intractable and pharmacologically unresponsive trigeminal neuralgia. Knowledge of the precise anatomical location of the infraorbital foramen and its lateralization will invariably reduce the relative risks during surgical procedures. Gruber (1878) was the first person who evaluated the morphometric assessment of the infraorbital foramen and reported the presence of accessory supranumerarios foramina

Author's Affiliation: *Assistant Professor, ***Lecturer, Department of Anatomy, **Professor, Department of Physiology, Koppal Institute of Medical Sciences, Koppal, Karnataka-583231. ****Professor, Department of Anatomy, Jawaharlal Nehru Medical College, Belgaum, Karnataka-590010

Corresponding Author: Dnyaneshwar, Assistant Professor, Department of Anatomy, Koppal Institute of Medical Sciences, Koppal - 583 231 Karnataka.
E-mail: drdnyan83@gmail.com

which he propounded as an important variable in anaesthetic valuation [2].

Various authors including Rouviere (1961)[3], Hollinshead (1982)[4], Bolini & Del Sol (1990)[5], Berge & Bergman (2001)[6] compared the morphometry of the infraorbital and supraorbital foramen and found that the infraorbital foramen has a relatively large diameter and can vary in form and situation with the supraorbital foramen and also variations with respect to ethnicity were reported by Hindy AM, Abdel Raouf (1993)[7]. Mollieux, Navez and Baylot (1996)[8], Prabhu, Wig and Grewal (1999)[9] studied the sectional blockage of the infraorbital nerve and regarded it better than infiltration for facial anaesthesia, because it accounts for less local tissue edema during surgery, thus allowing for good intrasurgical conditions.

Materials and Methods

A total 50 skulls examined for 100 infraorbital foramina which are identifiable of their sex were examined. Foetal skulls and skulls with gross damages in the area of measurement were excluded. All the parameters were examined by a three observer using a divider, Vernier calliper and millimetre scale. three measurements were made for each parameter to get an average value.

The infraorbital foramen was the landmark from which the distance between the following bony structures were examined; Nasion (NAS), Zygomatico maxillary suture (ZMS), Anterior nasal spine (ANS), and the distance between the inferior orbital rim (IOR) to optic canal (OC), infraorbital foramen (IOF), inferior & superior orbital fissure (IF & SF) (Figure 1). The shape of the Infra-orbital foramen and the number of

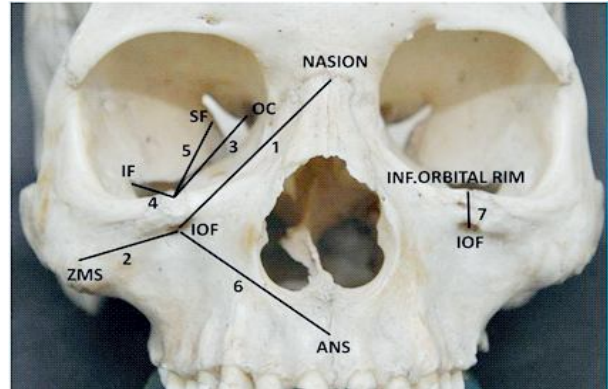


Fig. 1: Measurement of the parameters 1: Distance between infraorbital foramen to nasion; 2: Distance between infraorbital foramen to zygomatico-maxillary suture; 3: Distance between inferior orbital rim to optic canal; 4: Distance between inferior orbital rim to inferior orbital fissure; 5: Distance between inferior orbital rim to superior orbital fissure; 6: Distance between infraorbital foramen to anterior nasal spine; 7: Distance between inferior orbital rim to infraorbital foramen)

infraorbital foramina present were also examined in relation to the gender.

Results

In the present study, parameters were analysed with respect to gender and few of which showed statistical significance which are marked * in the tabular column.

The most common shape of infraorbital foramen found in the present study is oval (39%) followed by semilunar (27%). Round shaped foramen was found in 22% of skulls, triangle shaped foramen was found in 12% and accessory foramina were present in 11% of the skulls (Figure 2). The average mean and standard deviation were calculated for every measurement. Paired t – test was used to compare the parameters between sides and gender for each

Table 1: Measurements of the parameters

| Measurement | Male (n=50) | | Female (n=50) | |
|-------------------|---------------|---------------|---------------|---------------|
| | Right (n=25) | Left (n=25) | Right (n=25) | Left (n=25) |
| IOF – NASION (mm) | 38.45 ± 3.28 | 37.95 ± 3.33 | 32.86 ± 2.66* | 30.16 ± 2.06* |
| IOF – ZMS (mm) | 28.35 ± 8.57* | 27.40 ± 9.33* | 27.32 ± 7.50* | 27.31 ± 6.31* |
| IOR – OC (mm) | 47.60 ± 1.17* | 46.60 ± 1.84* | 44.52 ± 1.12* | 44.61 ± 1.14* |
| IOR – IF (mm) | 20.20 ± 2.39 | 19.50 ± 2.50 | 20.22 ± 2.31 | 19.12 ± 2.20 |
| IOR – SF (mm) | 43.30 ± 2.41 | 43.70 ± 2.67 | 41.32 ± 2.38* | 41.70 ± 2.61* |
| IOF – ANS (mm) | 36.30 ± 2.26 | 36.00 ± 2.36 | 34.31 ± 2.20 | 33.01 ± 2.31 |
| IOR – IOF (mm) | 7.60 ± 1.07* | 6.80 ± 0.42* | 7.11 ± 1.02 | 6.02 ± 0.41 |

measurement. The formula used for statistical analysis:

Statistically significant differences were reported when p – values were less than 0.05 (Table 1).

Data are presented in Means ± SD. * P < 0.05 which

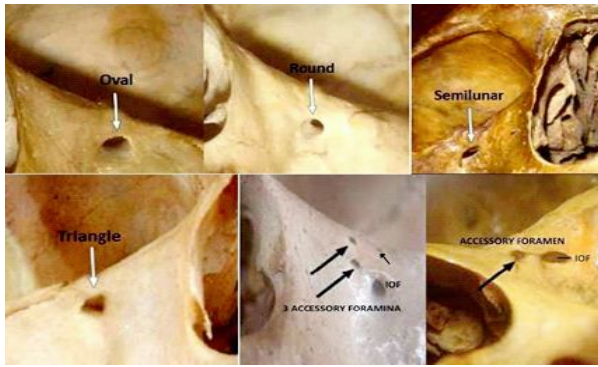


Fig. 2: Shapes of Infraorbital foramen

suggests statistical significance. IOF: Infraorbital foramen; ZMS: Zygomatico-maxillary suture; OC: Optic canal; IF: Inferior orbital fissure; SF: Superior orbital fissure; ANS: Anterior nasal septum. IOR: Inferior orbital rim

Discussion

The location of infraorbital foramen has become mandatory for different procedures to reduce the risk in orbital surgeries and Macedo et al^[10] observed the infraorbital rim to be the easier way to locate the foramen. He found the mean distance between the inferior orbital rim to the infraorbital foramen as 6.28 ± 1.79 mm on the right side and 6.45 ± 1.76 mm on the left side in a sample of 295 adult Brazilian skulls. Whereas in the present study the distance between the inferior orbital rim to the infraorbital foramen found to be 7.60 ± 1.07 mm on the right side and 6.80 ± 0.42 mm on the left side in males and for females it is found to be 7.11 ± 1.02 mm on the right side and 6.02 ± 0.41 mm on the left side. The observation in the present study signifies an increase of the distance in the south Indian population. The laterality of the infra-orbital foramen can be ascertained by measuring the distances from the Infraorbital foramen to the Nasion and found to be 38.45 ± 3.28 mm on the right side and 37.95 ± 3.33 mm on the left side in males and females the distance found was 32.86 ± 2.66 mm on the right side and 30.16 ± 2.06 mm on the left side, from which we can infer the laterality is more on the right side than the left. There is no other study available to compare the mean distance from the nasion to Infraorbital foramen and the present study will be more reliable as it has included many parameters.

Another parameter also proves to be of help in order to locate the infraorbital foramen, is the distance from Zygomatico-maxillary suture to the

infraorbital foramen, it is 28.35 ± 8.57 mm on the right side and 27.40 ± 9.33 mm on the left side in males and 27.32 ± 7.50 mm on the right side and 27.81 ± 6.51 mm on the left side in females. The values are similar to the observations by Isurani Ilayaperuma^[11] in Sri Lankan Tamil Population which is ethnically similar to north karnataka population. The mean horizontal distance in the present study is found to be 41.44 ± 2.08 mm on the right side and 40.56 ± 2.24 mm on the left side in males and 41.23 ± 2.04 mm on the right side and 40.04 ± 2.10 mm on the left side in females which shows significant increase in the distance in males that proves to be valuable in the orbital approaches.

The shape of the infraorbital foramen found to vary significantly among the ethnic groups and gender which were verified by various authors. The present study corresponds so closely to the observations by Boopathi et al^[12], because both the studies were done in the same south Indian population. In the present study the most common shape found was oval (39%) which is similar to all the studies done previously. The second most common shape found was semilunar (27%) which is similar to Boopathi et al^[12] (24%), Appinhasmit et al^[13] (29%) in Bangkok population. But authors like kazkayasi et al^[14] in Turkey population found round shape as the second most common type (38%).

More than all other shapes, in the present study we found Triangle shaped foremen in 12% skulls which is reported previously by Boopathi et al^[12] only, this shows the pivotal role of ethnicity, as this shape is found only in south Indian population. In addition to this, the number of accessory foramina also found to be high in the South Indian population, previously Hanihara and Ishida^[15] found the accessory foramina more commonly present in Northeast Asian skulls (16%). In the present study the accessory foramina were found in 11% skulls and it is 16.25% in the study done by Boopathi et al.^[12] This shows the higher incidence of accessory foramina in Asian skulls.

Conclusion

Although these were comparable to several studies, some considerable differences that may be of clinical importance were demonstrated. Moreover, the significant differences between the sides and gender in several measurements were also observed in the present study. Comparison of results from previous studies makes the large variation of the anatomical characteristics of the infraorbital foramen evident, not

only due to the diversity of the used parameters, but also due to the distinct investigated population. With a possibility of these characteristics being dependant on population groups, this study makes the morphometric study and laterality of the infraorbital foramen relevant.

Acknowledgement

I would like to express my profound gratitude to all the participants for their co-operation and for their immense faith they reposed in me.

References

1. Standring S. Gray's Anatomy. The Anatomical Basis of Clinical Practice, 39th Edition. Edinburgh: Elsevier Churchill Livingstone, 2005; p.699-700.
2. Gruber W. A hook shaped termed Fortsatzchen over and above the infraorbital foramen. [German] Arc Pathol Anat Physiol Klin Med. 1878; 72: 494-6.
3. Rouvière H. Anatomía humana descriptiva y topográfica. 8th ed. Madrid: Bailly-Bailliere; 1961.
4. Hollinshead WH, Rosse C. Textbook of anatomy. New. York: Harper & Row. 1985; p.890.
5. Bolini P, Del Sol M, Consideracos anatomicas sobre o canal e o sulco infra-orbital. Revista Brasileira de oftalmologia. 1990; 49: 113-6.
6. Berge JK, Bergman RA. Variations in size and symmetry of foramina of the human skull. Clin Anat. 2001; 14: 406-13.
7. Hindy AM, Abdel-Raouf F. A study of infraorbital foramen, canal and nerve in adult Egyptians. Egypt Dent J. 1993; 39: 573-80.
8. Molliex S, Navez M, Baylot D, Prades JM, Elkhoury Z, Auboyer C. Regional anaesthesia for outpatient nasal surgery. Br J Anaesth. 1996; 76: 151-3.
9. Goto F, Ishizaki K, Yoshikawa D, Obata H, Ariei H, Terada M. The long lasting effects of peripheral nerve blocks for trigeminal neuralgia using high concentration of tetracaine dissolved in bupivacaine. Pain. 1999; 79: 101-3.
10. Macedo VC, Cabrini RR, Faig-Leite H. Infraorbital foramen location in dry human skulls. Braz J Morphol sci. 2009; 26: 35-8.
11. Ilayperuma I, Nanayakkara G, Palahepitiya N. Morphometric analysis of the infraorbital foramen in adult Sri Lankan population. Int J Morphol. 2010; 28: 777-82.
12. Boopathi S, Chakravarthy Marx S, Dhalapathy SL, Anupa S. Anthropometric analysis of the infraorbital foramen in south Indian Population. Singapore Med J. 2010; 51: 730-5.
13. Apinhasmit W, Chompoopong S, Methathrathip D, Sansuk R, Phetphunphiphat W. Supraorbital Notch/ Foramen, Infraorbital Foramen and Mental Foramen in Thais: anthropometric measurements and surgical relevance. J Med Assoc Thai. 2006; 89: 675-82.
14. Kazkayasi M, Ergin A, Ersoy M, Tekdemir I, Elhan A. Microscopic anatomy of the infraorbital canal, nerve, and foramen. Otolaryngol Head Neck Surg. 2003; 129: 692-7.
15. Hanihara T, Ishida H. Frequency variations of discrete cranial traits in major human populations. IV. Vessel and nerve related variations. J Anat. 2001; 199: 273-87.