

Variation in Carotid System Anatomy in Central India

Manisha B. Sinha*, Human Prasad Sinha**, Dhayanesh Sharma*, Mrithunjay Rathore*, Soumitra Trivedi*, Abu Ubaida Siddiqui*

Abstract

Introduction: The common carotid artery is an important artery of blood supply to head, neck and brain located in the carotid triangle. It is also the most important artery responsible for brain stroke. In this study we observed the branching level of common carotid artery and also whether it is bifurcation or trifurcation. **Method:** In the embalmed cadavers, after dissection of neck, we reached carotid sheath and carotid triangle. Carotid system was then identified along with the vagus nerve. Superior thyroid artery which is a branch of external carotid artery (mentioned in standard text books of anatomy) was also noted. **Result:** Bifurcation of carotid artery was found equally distributed at the level of body of hyoid bone (32%) and superior border of thyroid bone (32%). In 50% cases superior thyroid artery arose from bifurcation of carotid artery. **Conclusion:** Terminology of bifurcation of common carotid artery is now invalid in our findings too. It is better to say trifurcation of common carotid artery. Superior thyroid artery is commonly a branch of common carotid artery. Level of bifurcation is also variable, hyoid must be considered for localizing the level.

Keywords: Common Carotid Artery; Bifurcation of carotid artery; Superior thyroid Artery.

Introduction

The Common carotid artery is one of the most important arteries of brain attack. Additionally, during neck surgeries and carotid angiography clinicians have to be very careful about the branches of carotid artery. Common carotid artery (CCA) gives no branch except two terminal branches in neck namely external carotid artery (ECA) and internal carotid artery (ICA). Bifurcation of CCA (CCAb) occurs at the level of superior border of thyroid cartilage [1]. Variability in level of origin of ECA and ICA is remarkable at regional level. Superior thyroid artery (STA) is known as a branch of ECA since long [2]. However, variation in origin of STA has been commonly reported recently [3]. STA may arise from

proximal part of CCA or at the level of CCAb. Carotid sinus (CS) is an important structure in close relation to CCAb, the position of which also keeps changing with variation in CCAb. Compression of CS during neck palpation might result in activation of parasympathetic system and inhibition of sympathetic nuclei which may lead to syncope [4,5].

Aim of our study is to note the variability of CCAb location, superior thyroid artery origin, position of carotid sinus, and relation of vagus nerve with carotid system in cadavers of Chhattisgarh region.

Material and Method

We took twenty eight hemi-sections of fourteen cadavers which were donated by family member for research and teaching purpose to Department of Anatomy, All India Institute of Medical Sciences, Raipur, Chhattisgarh. Proper consents were taken from the family members of donors. Out of twelve cadavers, three were females and nine were males, age ranged between 35-80years. After removal of skin, platysma, fascia of neck we reached anterior triangle. Sternocleidomastoid was pushed to one side. Level

Author's Affiliation: *Department of Anatomy, All India Institute of Medical Sciences (AIIMS), Tatibandh, GE Road, Raipur, Chhattisgarh 492099, India. **Department of Neurology, NH-MMI Narayana Multispecialty hospital Raipur, Chhattisgarh, India.

Corresponding Author: Manisha B. Sinha, Assistant Professor, Department of Anatomy, All India Institute of Medical Sciences, Raipur, Chhattisgarh, India-492099.
E-mail: manishab80@gmail.com

of bifurcation of common carotid, origin of superior thyroid artery, carotid sinus position, relation of vagus nerve to carotid system was traced.

enough sample size for comparison between male and female. Bifurcation of carotid was common at two levels: at the level of body of hyoid bone and at the level of superior border of thyroid cartilage. Superior thyroid artery originated commonly from bifurcation of CCA (CCAb).

Results

Results of the study is tabulated. We did not have

Table 1: Various level of bifurcation of common carotid artery in current study and comparing with other studies

S. N.	Position	Numbers (N=28)	Al- Rafiah et al	Ambali et al	Lo et al
1	At the body of hyoid bone	9(32.14%)	25%	42%	6%
2	At greater cornu of hyoid bone	2(7.14%)			15%
3	Above the greater cornu of hyoid bone	2(7.14%)	3.3%		-
4	Between hyoid bone and thyroid cartilage	2(7.14%)	18.3%		-
5	At superior border of thyroid cartilage	9(32.14%)	48.3%	57%	40
6	At the level of upper half of lamina of thyroid cartilage	4(14.28%)	5%	1%	39%

Table 2: Comparison of level of origin of superior thyroid artery from common carotid artery

S.N.	Study	Type I From CCAb	Type II From CCA	Type III From ECA	Type IV As a common trunk thyrolingual or thyrolinguofacial from ECA
1	Ozgun (2009)	40%	35%	25%	2.5%
2	Vazquez (2009) 216	49%	27%	23%	0.6%
3	Natsis (2011) 100	49%	12%	39%	3%
4	Al-Rafiah et al (2011)	76.7%	18.3%	3.3%	1.7%
5	Current Study	50%	25%	21.4%	3.6%

Table 3: Distribution of relation of vagus nerve with carotid system

S.N.	Relation of vagus with carotid system	Percentage %
1	Dorsolateral	64.28%
2	Dorsal	25%
3	Dorsomedial	10.7%

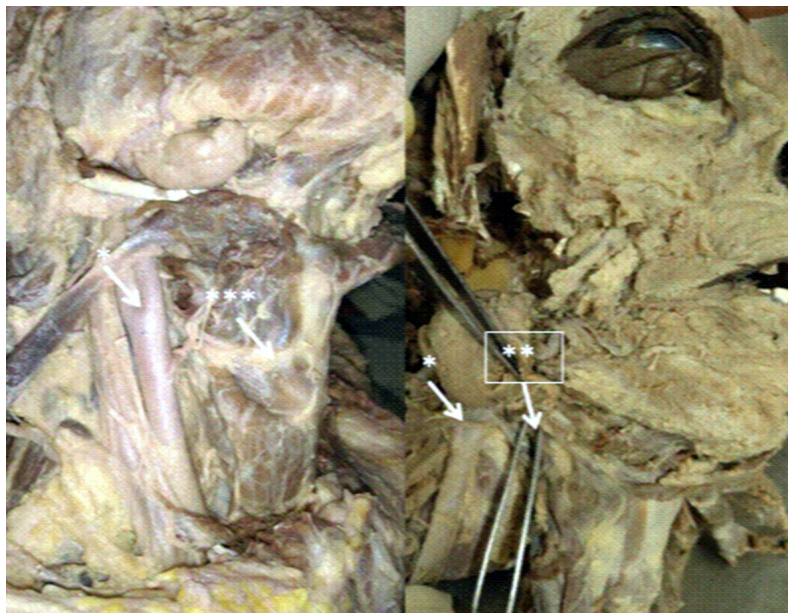


Fig. 1: Different levels of bifurcation of common carotid artery a. In between levels of thyroid cartilage and hyoid bone, b. At the level of hyoid bone; * bifurcation point, **level of hyoid bone, *** level of thyroid

Table 4: Distribution of situation of carotid sinus

S.N.	Presence of Carotid sinus	Percentage
1	At bifurcation	64.28%
2	At ICA	25%
3	At both ICA & Bifurcation	10.7%

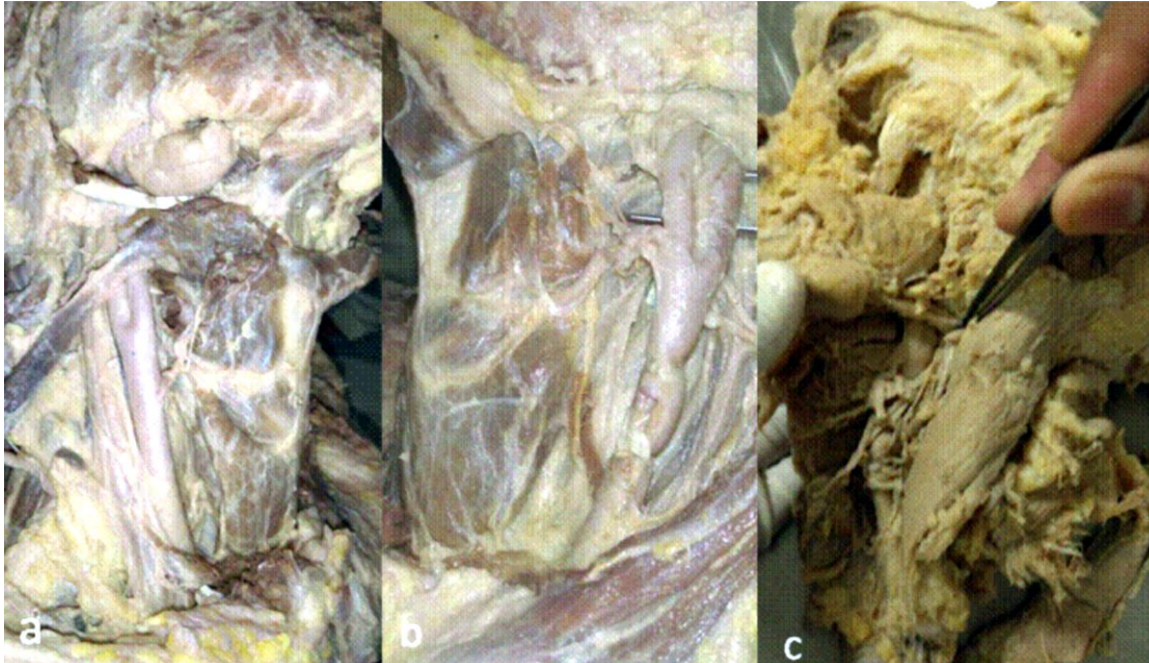


Fig. 2: Different levels of origin of superior thyroid artery a. from common carotid artery, b. from common carotid artery bifurcation as trifurcation, c. from external carotid artery

Discussion

Carotid system stroke is responsible for disabling paralysis in a significant number of patients. This is equally important in cadavers as embalming of cadavers through carotid system is one of the routinely used procedures. Hence, the level of division of CCA is of paramount significance as variation in level of CCAb may result in significant variation in related structures as well. The CCAb level has been discussed in Table 1. In our study, we observed level of CCAb to be both at the level of body of hyoid bone as well as at the level of superior border of thyroid cartilage in almost equal proportion of cases (Figure 1). It implies that the level of hyoid is also equally important while doing carotid angiography and carotid embalming. As per one of the previous studies, the incidence of higher level of bifurcation was relatively low in the south Indian population (11.25%)[6]. Al-Rafiah et al [7] also found the bifurcation above the level of thyroid cartilage in 46.6% cases. Out of which, 25% cases were located at the level of hyoid. Ambali et al [8] also reported nearly similar findings. Lo et al [9] also found bifurcation at the level of hyoid in 21% cases. In these cases,

bifurcation point is closely related to the hypoglossal nerve. An unusual case of bilateral intrathoracic bifurcation has also been described in a patient with Klippel-Feil anomaly by Gailloud et al (2000) [10]. These findings suggest that the older concept of CCA bifurcation level at the superior border of thyroid cartilage now needs revision. Now, it extends from thyroid cartilage to hyoid cartilage. The cause for this shift in branching level is still obscure. In current study branching level was noted above the superior border of thyroid in 53.56% cases.

In our study, in almost 50% cases the CCAs had trifurcation and superior thyroid artery was found to be arising from CCAb (Table 2, Figure 2). The findings of the current study was less than finding of Al-Rafiah et al, (76.07%) [7], Hayashi et al, (70%) [11] while it was more than the findings of Lucev et al (47.5%) [12] and Ozgur et al (40%) [13]. Vazquez et al [14] and Natsis et al [3] found the same in 49%. A new concept of trifurcation of common carotid is strongly evident in the present study as well as in the studies by Natsis et al, 2011[3], Al-Rafiah et al [7], Hayashi et al [10]. It may be because of regional variation. The STA origin from CCA was found in 10-48% of the cases [1, 12, 15]. In Indian study, STA was found to be a branch of

CCA including CCab in 21% by Anitha et al [16], 35.14% cases by Sanjeev et al [17]. This frequent variation in origin of STA must be kept in mind because it is ligated during thyroidectomy by surgeons. In current study, 64.28% cases were found to have classical relationship between carotid system and vagus in carotid sheath, dorsal in 25% cases and dorsomedial in 10.7% cases (Table 3). In current study presence of carotid sinus at bifurcation was in 64 % (Table 4). The CS extended to internal carotid artery in 11% cases or confined to ICA in 25%.

Conclusion

In current study we found the level of thyroid cartilage and hyoid bone equally important with respect to bifurcation of common carotid artery. Origin of superior thyroid artery is also variable and it arose commonly from common carotid artery in the neck as trifurcation which must be considered by surgeons and radiologists. We think that the standard textbooks need to include these findings as it has been confirmed by many studies.

References

- Hollinshead WH. Anatomy for surgeons. Vol. 1. Head and Neck. Hoeber Harper International, Philadelphia: 1966; p.564-76
- Standring S. Gray's anatomy: the anatomical basis of clinical practice. 39th Ed. Elsevier, Churchill Livingstone, Edinburgh, London, New York, Oxford, Philadelphia, Sydney, Toronto. 2005.
- Natsis K, Raikos A, Foundos I, Noussios G, Lazaridis N, Njau SN. Superior thyroid artery origin in Caucasian Greeks: A new classification proposal and review of the literature. *Clin Anat*. 2011; 24(6): 699-705. doi: 10.1002/ca.21181.
- Strickberger SA, Benson DW, Biaggioni I, Callans DJ, Cohen MI, Ellenbogen KA, Epstein AE, Friedman P, Goldberger J, Heidenreich PA, Klein GJ, Knight BP, Morillo CA, Myerburg RJ, Sila CA. Scientific statement on the evaluation of syncope. 2006; 113: 316-327.
- Folino AF. Cerebral auto-regulation and syncope: victim or executioner? *Heart* 2006; 92: 724-726
- Radha K. Bifurcation levels of the common carotid arteries: a cadaveric study in south indian population *Int j anat res*. 2014; 2(3): 511-14. ISSN 2321-4287
- Al-Rafiah, A.A. EL-Haggagy, I.H.A. Aal, A.I. Zaki. Anatomical study of the carotid bifurcation and origin variations of the ascending pharyngeal and superior thyroid arteries *Folia Morphol*. 2011; 70(1), 47-55.
- Ambali Manoj and Jadhav Surekha. Variations in Bifurcation Point and Branching Pattern of Common Carotid Arteries: A Cadaveric Study. *Journal of pharmaceutical and biomedical sciences*. 2012; 25(25): 147-151.
- Lo A, Oehley M, Bartlett A, Adams D, Blyth P, AL-ALI S. Anatomical variations of the common carotid artery bifurcation. *Anz J Surg*. 2006; 76: 970-972.
- Gailloud P, K. J. Murphy, and D. Rigamonti. Bilateral thoracic bifurcation of the common carotid artery associated with Klippel-Feil anomaly. *Am J Neuroradiol*. 2000; 21(5): 941-944.
- Hayashi N, Hori E et.al. Surgical anatomy of the cervical carotid artery for carotid endarterectomy. *Neurol Med Chir (Tokyo)*. 2005; 45: 25-9.
- Lucev N, Babinac D, Maric I, Drescik I. Variations of the great arteries in the carotid triangle. *Otolaryngol Head Neck Surg* 2000; 122: 590-1.
- Ozgur Z, Govsa F, Ozgur T. Anatomical evaluation of carotid artery bifurcation in cadavers: implications for open endovascular therapy. *Surg Radiol Anat*, 2008; 30: 475-480.
- Vazquez T, Cobiellar R, maranillo E, Valderrama FJ, Mc Hanwell S, Parkin I, Sanudo JR. Anatomical variations of the superior thyroid and superior laryngeal arteries. *Head and Neck*. 2009; 10: 1078-1085.
- Banna M, Lasjaunias P. The arteries of the lingual thyroid: Angiographic findings and anatomic variations. *Am J Neuroradiol*. 1990; 11: 730-2.
- Anitha T, Dombe D, Asha K, Kalbande S. Clinically relevant variations of the superior thyroid artery: An anatomic guide for neck surgeries. *Int J Pharm Biomed Sci*. 2011; 2: 51-4.
- Sanjeev IK, Anita H, Aswini M, Mahesh U, Rairam GB. Branching pattern of external carotid artery in humans. *J Clin Diagn Res* 2010; 4: 3128-33.