

# Multiple Techniques for Delay of Cross Leg Flap

Somala Prathuyusha<sup>1</sup>, Ravi Kumar Chittoria<sup>2</sup>, Barath Kumar Singh P<sup>3</sup>

**How to cite this article:**

Somala Prathuyusha, Ravi Kumar Chittoria, Barath Kumar Singh. P/ Multiple Techniques for Delay of Cross Leg Flap / International Physiology.2023;11(2):53-56.

**Author Affiliation:** <sup>1</sup>Junior Resident, Department of Plastic Surgery, <sup>2</sup>Professor, Head of IT Wing and Telemedicine, Department of Plastic Surgery & Telemedicine, <sup>3</sup>Senior Resident, Department of Plastic Surgery, Jawaharlal Institute of Postgraduate Medical Education and Research, Pondicherry 605006, India.

**Corresponding Author:** Ravi Kumar Chittoria, Professor, Head of IT Wing and Telemedicine, Department of Plastic Surgery & Telemedicine, Jawaharlal Institute of Postgraduate Medical Education and Research, Pondicherry 605006, India.

**E-mail:** drchittoria@yahoo.com

**Received on:** 15.11.2022

**Accepted on:** 23.12.2023

**Abstract**

Pedicled cross-extremity flaps for lower limb wound coverage have been replaced by free tissue transfer in the last two decades. However, there are certain difficult situations where the free flap cannot be employed and alternative methods are needed. Delay is defined as surgical interruption of a portion of the blood supply in a preliminary stage prior to tissue transfer in the pedicled flap. We describe our experience with cross leg flap for the reconstruction of lower limb defect.

**Keywords:** Scross Leg Flap; Lower Limb Defect; Pharmacological Delay; Mechanical Delay; Surgical Delay; Perforator Ligation.

**INTRODUCTION**

Cutaneous injuries of the lower third of the leg and dorsum of the foot represent a great challenge for orthopaedic and plastic surgeons. The poor vascularization and subsequent poor healing encountered in these regions demand detailed knowledge of the local anatomy to select the best surgical alternative for each patient. The free flaps are usually the first choice for soft tissue coverage in the distal leg.<sup>1</sup> There continue to be, however, some clinical situations in which local fascio-cutaneous and myo-cutaneous flaps are often not available. Occasionally, a free flap may also have failed

because of technical errors or damaged vasculature. In these situations, a cross-leg flap is the best choice. The cross-leg flap needs delay procedure before flap division and flap inset. In this case report, we discuss various flap delay techniques.

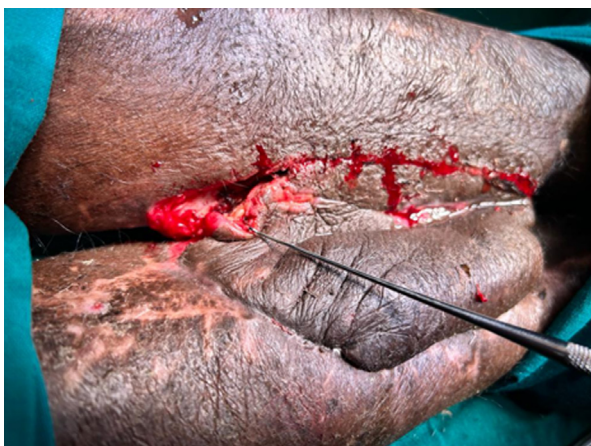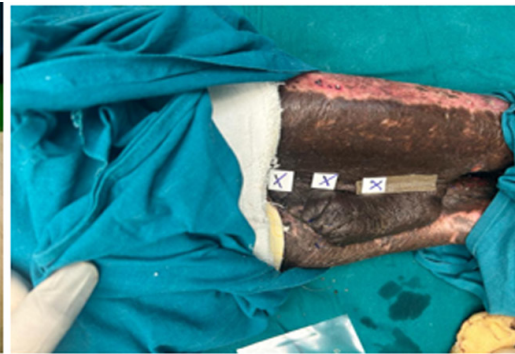
**MATERIALS AND METHODS**

This study was done at tertiary care hospital after obtaining approval of departmental scientific and ethical committee. Informed consent was obtained from the patient. This is a prospective descriptive non randomised case study about a 57 year old

male with post traumatic middle lower limb defect in the right side. On evaluation, Patient wound to have damaged lower limb vessels on angiogram. The surrounding skin was damaged and grafted where the bone defect was present. The local flap and free flap were not a possible option in this patient. Patient was planned on cross-leg flap for further management. After cross leg flap, patient was maintained in the appropriate position with the help of plaster of Paris cast. After three weeks, before flap division delay procedure was done.



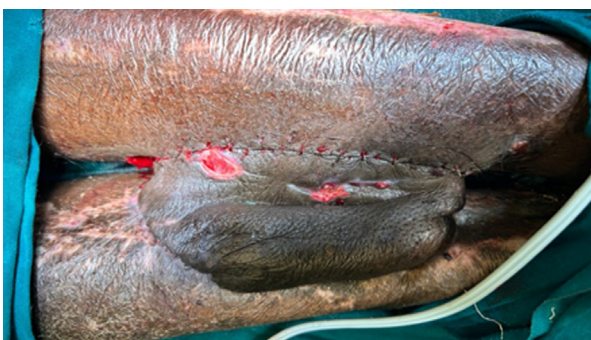**Fig. 1:** Identification of Perforator of the cross-leg flap by doppler



**Fig. 2:** Ligation of perforator

Skin, subcutaneous fat and fascia were cut layer by layer to induce the ischaemic preconditioning. (fig. 3).

*Pharmacological Delay:*



**Fig. 3:** Surgical delay by sequential cutting

We have tried various flap delay techniques in our case. The Surgical delay by perforator ligation, Pharmacological delay and Mechanical delay.

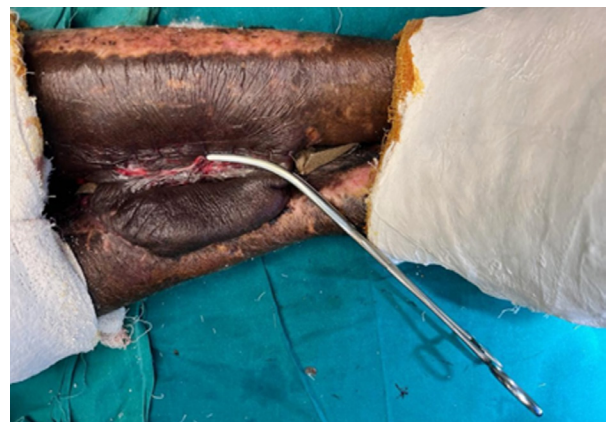*Surgical Delay by Perforator Ligation:*

Perforators were identified prior to surgery by hand held Doppler and are ligated sequentially to increase the length and enhance the survival of cross leg flap before it is divided (fig. 1-2).

*Surgical Delay by Sequential Cutting:*

First, observations made from the vasoactive drug actions in the vasculature of skin flaps can provide insight into the regulatory mechanism of cutaneous circulation and the pathophysiology of ischemic necrosis in skin flap surgery (fig. 4).

*Mechanical Delay:*

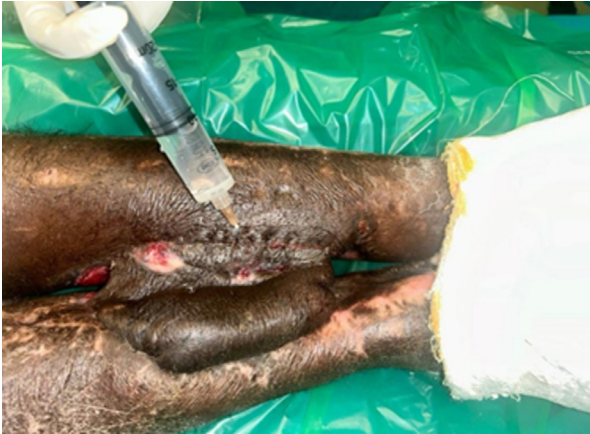

**Fig. 4:** Mechanical Clamping of the flap

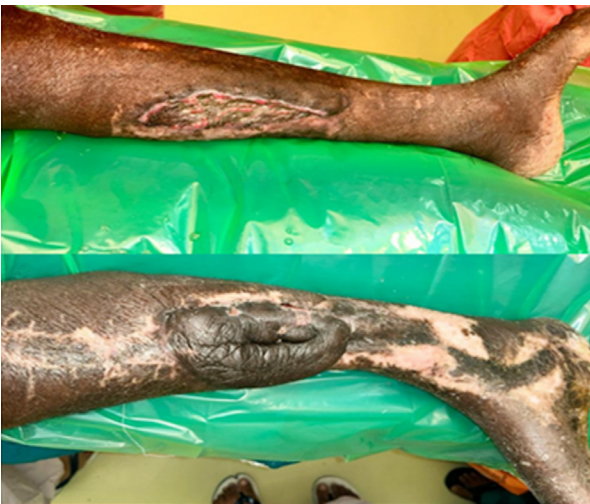Use of bowel clamp to clamp the vessels can be used as mechanical delay to further cause ischemia and improve the survival of flap (fig. 5).

## **RESULTS**

Flap delay procedures went uneventful. Patient compliance was good. Flap was divided successfully and in set done (fig. 6). No flap loss.



**Fig. 5:** Injection of adrenaline 1:10000 in the flap site  
No complications noted with above procedures.



**Fig. 6:** Cross leg flap after division

## **DISCUSSION**

The inclusion of fascia in the flap makes length-to-breadth ratio 3:1 perfectly safe. This allows much greater area of skin to be transferred with much more freedom of leg position. The flap provided stable coverage for different defects with few complications. Even should the flap fail, no significant bridges have been burnt and all the other surgical options remain viable. Traditionally, cross-leg flaps have been problematic because of difficulties with immobilization and positioning of the extremities from the time of initial coverage to detachment.<sup>1,2</sup> Surgical delay is a perfusion preconditioning technique in reconstructive soft tissue flap surgery. In this technique, the flap's vascular supply is partially disrupted in a separate procedure prior to a subsequent transfer procedure. The purpose of the technique is to allow for enhanced flap length and viability in

reconstruction. To enhance the length, 'delay' was necessary, which increased the number of procedures and there by hospitalization for several weeks.<sup>3</sup>

Surgical delay is a technique widely used to enhance the vascularity of an existing flap. It takes advantage of the tissue's ability to neovascularize under ischemic conditions, and manipulates the vascular supply to fit the appropriate pattern for flap design. It is especially useful in creating a strong axial blood supply where none previously existed. Clinical research demonstrated that vascular delay increases flap survival significantly and allows for earlier divisions of pedicle. Vascular delay affects the target tissue in two phases early and late. Early effects derive predominantly from transection of sympathetic fibres leading to dilation and reorientation of choke vessels.<sup>4</sup> The late phase effects lead to enhanced flap vascularity due to new vessel growth. The benefits of vascular delay are currently achieved with either the surgical or chemical or pharmacological or mechanical decrease of blood flow to the flap. Surgically, the major vessels supplying the proposed flap are ligated to increase peripheral vascularity or the perimeter of the flap is divided to bolster flow from the pedicle's base. The transverse rectus abdominis musculocutaneous (TRAM) flap serves as a common example where the delay phenomenon is employed. One surgical technique involves ligation of the superficial and deep inferior epigastric vessels two weeks prior to raising the flap for the proposed reconstruction, resulting in increased arterial pressure and decreased venous congestion in the flap. Blood flow restrictions can also be achieved via the selective embolization of the deep inferior epigastric arteries to similar improve perfusion of the TRAM flap. Chemical delay has also been described. The administration of human VEGF has been demonstrated to similarly induce angiogenesis in TRAM flaps prior to use in reconstruction.<sup>5</sup>

## **CONCLUSION**

The field of reconstructive surgery can benefit greatly from an understanding of the discoveries in ischemic preconditioning in other fields in the context of the delay phenomenon.

*Conflicts of Interest:* None.

*Authors' Contributions:* All authors made contributions to the research, is putatively expected to be useful article.

*Availability of data and materials:* Not applicable

*Financial support and sponsorship:* None

*Consent for publication:* Not applicable

## **REFERENCES**

1. Agarwal P, Raza HK. Cross-leg flap: its role in limb salvage. *Indian Journal of Orthopaedics*. 2008 Oct;42(4):439.
2. De Almeida OM, Monteiro Jr AA, Neves RI, De Lemos RG, Braz JC, Brechtbuhl ER, Gemperli R, Ferreira MC. Distally based fasciocutaneous flap of the calf for cutaneous coverage of the lower leg and dorsum of the foot. *Annals of plastic surgery*. 2000 Apr 1;44(4):367-74.
3. Chen HC, El-Gammal TA, Wei FC, Chen HH, Noordhoff MS, Tang YB. Cross-leg free flaps for difficult cases of leg defects: indications, pitfalls, and long-term results. *Journal of Trauma and Acute Care Surgery*. 1997 Sep 1;43(3):486-91.
4. Hamilton K, Wolfswinkel EM, Weathers WM, Xue AS, Hatef DA, Izaddoost S, Hollier Jr LH. The delay phenomenon: a compilation of knowledge across specialties. *Craniofacial Trauma & Reconstruction*. 2014 Jun;7(2):112-8.
5. Restifo RJ, Ahmed SS, Rosser J, Zahir K, Zink J, Lalikos JA, Thomson GJ. TRAM flap perforator ligation and the delay phenomenon: Development of an endoscopic/laparoscopic delay procedure. *Plastic and reconstructive surgery*. 1998 May 1;101(6):1503-11.

