

Frontal Sinus & Nasal Septum Patterns & Pneumatisation of Sphenoid Sinus: An Obscure Path for Personal Identification: A Retrospective Cone Beam Computed Tomography Study

Kalai Selvi Ravishankar¹, Saraswathi Gopal K², Mahesh Kumar P³

How to cite this article:

Kalai Selvi Ravishankar, Saraswathi Gopal. K, Mahesh Kumar. P/ Frontal Sinus & Nasal Septum Patterns & Pneumatisation of Sphenoid Sinus: An Obscure Path for Personal Identification: A Retrospective Cone Beam Computed Tomography Study/ Indian Journal of Forensic Odontology. 2023;16(1):9-17.

Abstract

Background: Identification of a body is the cornerstone of forensic investigation. If primary methods of identification are impossible (absence of comparative DNA samples, fingerprints, and teeth records), it can be performed using radiographic techniques, whenever antemortem images are available. Visual comparison of antemortem and postmortem images, such as frontal sinuses radiographics and CBCTs can allow identification. The uniqueness and reliability of frontal sinus and nasal septum patterns is used for human identification in forensic science. personal identification can also be done by assessment of pneumatisation of sphenoidal sinus.

Aim & Objectives: This study aims to evaluate the use of frontal sinus and nasal septum patterns and the pneumatisation of sphenoidal sinus for personal identification. To correlate all the parameters to find which is more accurate for identifying a person.

Materials & Method: *Study Design:* A Retrospective Study. *Study Population:* A study of 90 CBCT images, (45 males and 45 females) acquired from the archives that were generated using Planmeca Promax 3D MID Proface CBCT machine and assessed with Planmeca Romexis Software. *Sample size:* Sample of 90 CBCT images obtained from the archives. CBCT images of patients between 18 - 69 years of age.

Result: Pearson's Chi-Square test between gender for frontal sinus were $\chi^2=12.659$, $p=0.005<0.01$ which shows highly statistical significance between frontal sinus and gender, for nasal septum were $\chi^2=0.722$, $p=0.949>0.05$ which shows no statistical significance between nasal septum and gender, for sphenoid sinus were $\chi^2=9.574$, $p=0.008<0.01$ which shows highly statistical significance between sphenoid sinus and gender. But his study had individual variations in frontal sinus, nasal septum and sphenoid sinus for every person.

Conclusion: Imaging of the human body, especially the head and neck region, has been useful

Author's Affiliations: ¹Postgraduate, ²Head of the Department, ³Associate Professor, Department of Oral Medicine and Radiology, Meenakshi Ammal Dental College and Hospital, Chennai 600095, Tamil Nadu, India.

Corresponding Author: Saraswathi Gopal. K, Head of the Department, Department of Oral Medicine and Radiology, Meenakshi Ammal Dental College and Hospital, Chennai 600095, Tamil Nadu, India.

E-mail: dr.saraswathik@yahoo.in

Received on: 29-05-2023

Accepted on: 26.06.2023

in forensic dentistry for proving medicolegal cases and in human identifications during mass disasters.

Hence, this study determines the reliability and accuracy of frontal sinus, sphenoidal sinus and nasal septum pattern as a tool for personal identification.

Keywords: Frontal sinus; Nasal septum; Sphenoid sinus; Personal identification; CBCT.

INTRODUCTION

The study of anthropometry is of fundamental importance in identification of a person and plays a vital role in medico legal investigation of a dead person. Use of features unique to each human being helps in personal identification and is widely accepted in forensics. On comparing the ante-mortem reports recorded during life time and post-mortem records, a forensic odontologist can identify the age at time of death, race and even sex¹ by study of the skull's osteological features. Personal identification can be done using various body parts, the skull, the pelvis, the long bones, the foramen magnum and the paranasal sinuses.²

In any natural disaster, criminal case investigation or when the body is burnt or destroyed the body remains degraded and other biological tools such as DNA analysis, fingerprint etc., fail to assess the identification of the body, forensic radiology plays an important role in personal identification as well as gender determination.³ Identification of a body is the cornerstone of forensic investigation. If primary methods of identification⁴ are impossible (absence of comparative DNA samples, fingerprints, and teeth records,^{5,6} it can be performed using radiographic techniques, whenever antemortem images are available. Visual comparison of antemortem and postmortem images, such as CTs, Cone beam computed tomographies (CBCT)⁷ and frontal sinuses radiographs,⁸ can allow identification, if concordance of specific anatomical findings is established. If antemortem radiologic images are missing, the sex and/or the age of the corpse can be assessed using X-ray imaging of skull or postcranial elements.⁹⁻¹³

Structures in human skull such as frontal sinus, nasal septum, vascular groove patterns, sellaturcica etc., can act as useful indicators because of their uniqueness in every individual. Frontal sinus is a cavity which is lobulated. It is bilaterally situated in between the external and internal cortical surface of the frontal bone. It may vary person to person or even in monozygotic twins. The frontal sinuses are not even visible at the time of birth.^{14,15} They gradually develop at the age of two years and the development completes at the age of 20 years.

The nasal septum pattern is also useful and unique tool. In each individual many types of patterns present such as Straight (S'), Left deviated (L') or Right deviated (R'), Sigmoid type (Si), Reverse sigmoid type (RSi) and Others (O) (epsilon and reverse epsilon type; rare types).¹⁶

Severely damaged bodies can be difficult to identify, and various factors can delay the identification.^{17,18} In violent traumatic contexts, teeth and frontal sinuses can be missing, or separated into small pieces from the rest of the body, which limits their contribution to identification. Sphenoid sinuses, on the other hand, are better protected from traumatic degradation. They appear in the third year of life, contrary to frontal sinuses, which are not aerated before the age of 6 years.^{19,20} As they are deeply positioned in the center of the cranial base²¹ they are well protected from degradation resulting from external causes. Their pneumatization, well documented as extremely variable in degrees and directions²²⁻²⁵, could contribute to the radiologic identification of a dead person.²⁶

CBCT is today the reference imaging modality to study various pathologies and sinuses and it is frequently and increasingly prescribed in various countries. Unlike conventional radiography, CBCT allows an excellent visualization of the anatomical features of the frontal sinus, nasal septum and sphenoid sinuses. Sphenoid sinuses are therefore well protected, anatomically variable, and perfectly examinable on CBCT s. Their possible contribution to identification was reported, but to our knowledge, the accuracy of their forensic use has not yet been assessed. The aim of this study was to assess the frontal sinus and nasal septum patterns and the pneumatization of sphenoid sinus in personal identification.

AIM & OBJECTIVES

- This study aims to evaluate the frontal sinus and nasal patterns and pneumatization of sphenoidal sinus for personal identification.
- To identify an individual based on combined frontal sinus and nasal septum patterns.
- To identify an individual based on the sphenoidal sinus pneumatization.
- To correlate all the parameters to find which is more accurate for identifying a person.

MATERIALS AND METHOD

Institutional Ethical Committee of Meenakshi Ammal Dental College & Hospital, Maduravoyal, Chennai 600095, India, in its review online meeting held on 28.09.2021 at 9.00 a.m., reviewed and

discussed the study proposal with protocol number MADC/IC/III/70/2021 Entitled Significance of Frontal sinus and Nasal septum patterns and Pneumatisation of Sphenoidal sinus in personal identification: A Retrospective cone beam computed tomography study.

Full skull CBCT images of the patients reported to the institution for various dental problems taken in the time period between 2014 - 2021 were acquired from the dental archives. The scans were generated using the Planmeca Promax 3D MID Proface CBCT machine obtained at 90Kvp, 10mA and with large FOV 13x15 cm.

Study Design: A Retrospective Study.

Study Population: A study of 90 CBCT images, (45 males and 45 females) acquired from the archives that were generated using Planmeca Promax 3D MID Proface CBCT machine and assessed with Planmeca Romexis

Sample size: Sample of 90 CBCT images obtained from the archives. CBCT images of patients between 20-65 years of age.

Inclusion Criteria

- CBCT images having good resolution and image clarity.
- Patients in the age group of above 18 years of both the genders were included in the study.

Exclusion Criteria

- CBCT of patients younger than 18 are excluded.
- CBCT images with artifacts.
- Patients with maxillofacial, frontal bone and sphenoidal bone fractures and treated for the same.
- Patients diagnosed with tumors, or any pathology involving the sphenoid sinus, frontal and the nasal bone.

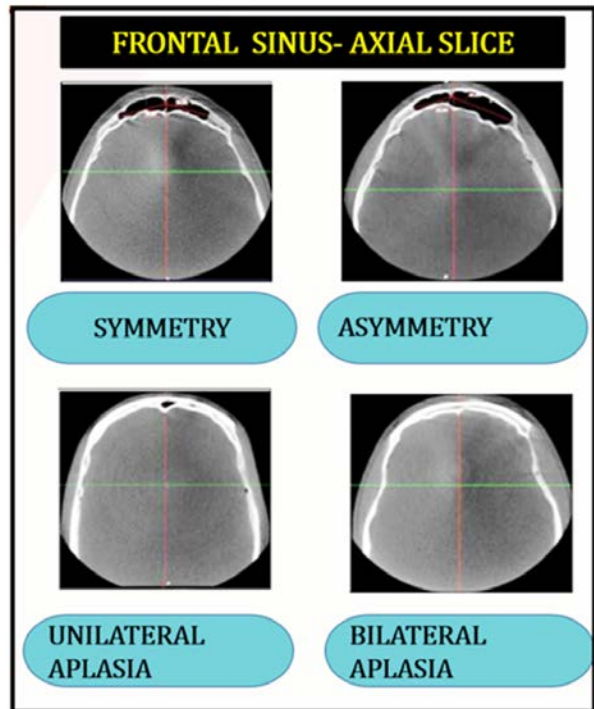
METHODOLOGY

Parameters to be Assessed

1. Frontal Sinus

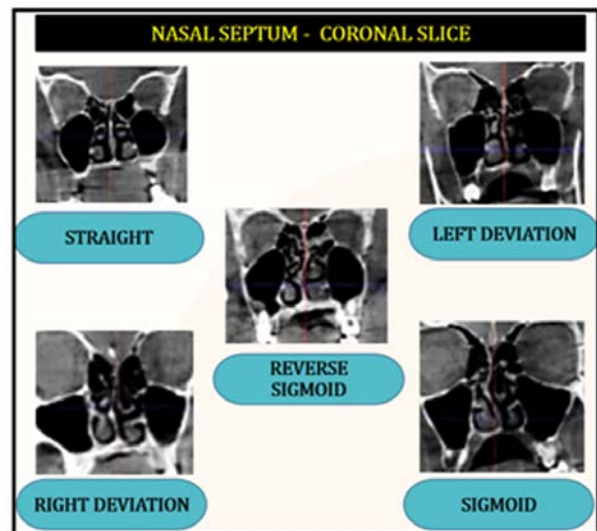
Frontal sinus in axial section. The different classification of frontal sinus was observed. The different types include: **Symmetry, Asymmetry,**

Unilateral aplasia, Bilateral aplasia.



2. Nasal Septum

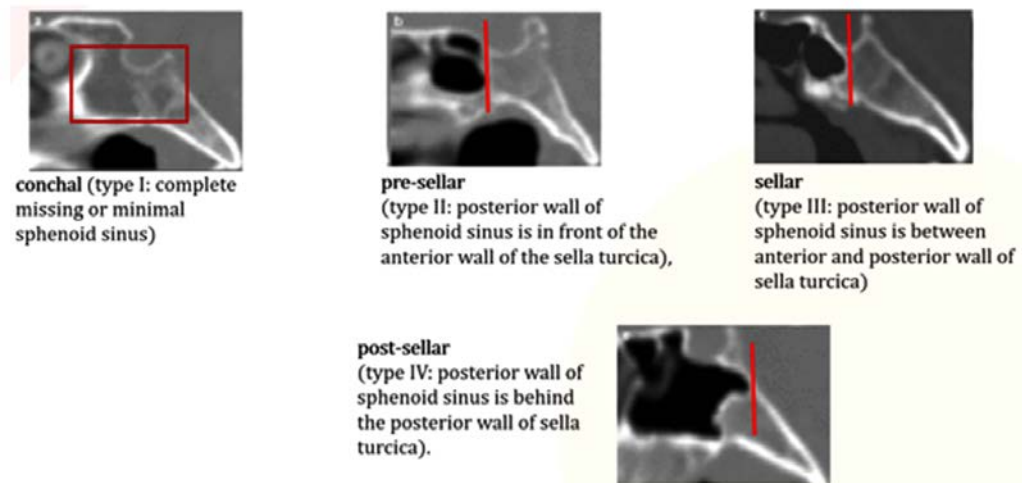
Nasal septum in coronal slice. The different patterns of nasal septum was observed. The various patterns include: Straight, Left deviation, Right deviation, Sigmoid, Reverse sigmoid.



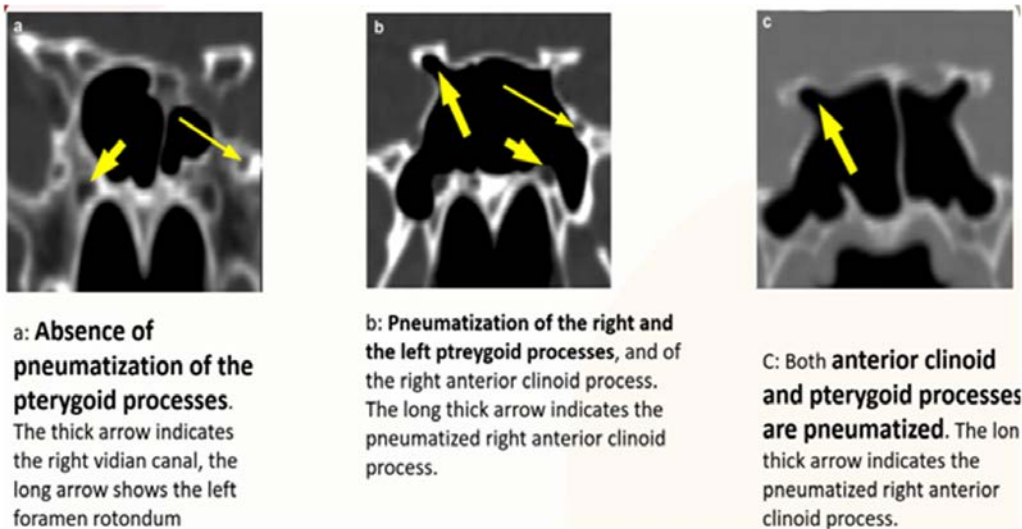
3. Sphenoid sinus

Sphenoid sinus was observed for its pneumatisation in sagittal and coronal section. In sagittal slices, the position of the posterior wall of the sphenoid sinuses was evaluated in relation with the anterior and posterior walls of the sellaturcica. Sinuses can be classed according to the following types: (Hammer and Radberg).

Conchal, pre-sellar, sellar, post-sellar



In coronal slice, coronal slice through sphenoid sinus with pneumatisation of pterygoid and clinoid process was observed.³¹



RESULTS

The collected data from the study were analysed with IBM SPSS Statistics for Windows, Version 23.0. (Armonk, NY: IBM Corp). To describe about the data descriptive statistics frequency analysis, percentage analysis were used for categorical variables and the mean & S.D were used for continuous variables. To find the significant difference between the bivariate samples in Independent groups the Unpaired sample t-test was used. To find the significance in categorical data Chi-Square test was used. In all the above statistical tools the probability value .05 is considered as significant level. In this study the frontal sinus, nasal septum and sphenoid sinus had individual variations for every person which aids us in identifying a person in a crucial hour of forensic investigation.

The Gender distribution were Female is 50.0%, Male is 50.0%. The Frontal Sinus distribution were Ia is 60.0%, Ib is 21.1%, Ic is 5.6%, Id is 13.3%. The Frontal Sinus between Gender by Pearson’s Chi-Square test were $2=12.659$, $p=0.005 < 0.01$ which shows highly statistical significance between Frontal Sinus and Gender. The Nasal Septum distribution were IIa is 42.2%, IIb is 15.6%, IIc is 20.0%, IID is 13.3%, IIE is 8.9%. The Nasal Septum between Gender by Pearson’s Chi-Square test were $2=0.722$, $p=0.949 > 0.05$ which shows no statistical significance between Nasal Septum and Gender. The Sphenoid Sinus distributions (In sagittal slices) were Type I is 3.3%, Type II is 26.7%, Type III is 25.6%, Type IV is 44.4%. The Sphenoid Sinus between Gender by Pearson’s Chi-Square test were $2=2.991$, $p=0.393 > 0.05$ which shows no statistical significance between Sphenoid Sinus and Gender. The Sphenoid Sinus distribution (In axial slices)

were II a is 67.8%, II b is 18.9%, II c is 13.3%. The Sphenoid Sinus between Gender by Pearson's Chi-Square test were $\chi^2=9.574$, $p=0.008<0.01$ which shows highly statistical significance between Sphenoid Sinus and Gender.

Table 1: Comparison of Frontal Sinus between Gender by Pearson's Chi-Square test

-			Gender		Total	2 - value	p-value
			Male	Female			
Frontal Sinus	Symmetry (I a)	Count	32	22	54	12.659	0.005 **
		%	71.10%	48.90%	60.00%		
	Asymmetry (I b)	Count	11	8	19		
		%	24.40%	17.80%	21.10%		
	Unilateral aplasia (I c)	Count	0	5	5		
		%	0.00%	11.10%	5.60%		
	Bilateral aplasia (I d)	Count	2	10	12		
		%	4.40%	22.20%	13.30%		
Total	Count	45	45	90			
	%	100.00%	100.00%	100.00%			

** Highly Statistical Significance at $p < 0.01$ level

Table 2: Comparison of Nasal Septum between Gender by Pearson's Chi-Square test

-			Gender		Total	2 - value	p-value
			Male	Female			
Nasal Septum	Straight (II a)	Count	19	19	38	0.722	0.949 #
		%	42.20%	42.20%	42.20%		
	Right deviation (II b)	Count	7	7	14		
		%	15.60%	15.60%	15.60%		
	Left deviation (II c)	Count	8	10	18		
		%	17.80%	22.20%	20.00%		
	Sigmoid (II d)	Count	6	6	12		
		%	13.30%	13.30%	13.30%		
	Reverse sigmoid (II e)	Count	5	3	8		
		%	11.10%	6.70%	8.90%		
Total	Count	45	45	90			
	%	100.00%	100.00%	100.00%			

No Statistical Significance at $p > 0.05$ level

Table 3: Comparison of Sphenoid Sinus between Gender by Pearson's Chi-Square test

-			Gender		Total	2 - value	p-value
			Male	Female			
Sphenoid Sinus	Presellar (Type I)	Count	2	1	3	2.991	0.393 #
		%	4.40%	2.20%	3.30%		
	Sellar (Type II)	Count	14	10	24		
		%	31.10%	22.20%	26.70%		
	Post sellar (Type III)	Count	13	10	23		
		%	28.90%	22.20%	25.60%		
	Most posterior (Type IV)	Count	16	24	40		
		%	35.60%	53.30%	44.40%		
Total	Count	45	45	90			
	%	100.00%	100.00%	100.00%			

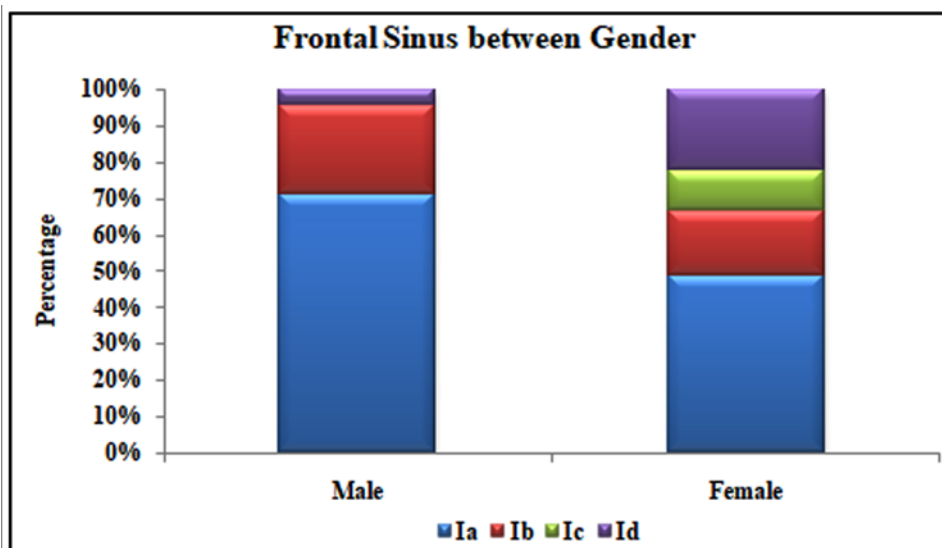
No Statistical Significance at $p > 0.05$ level

Table 4: Comparison of Sphenoid Sinus between Gender by Pearson’s Chi-Square test

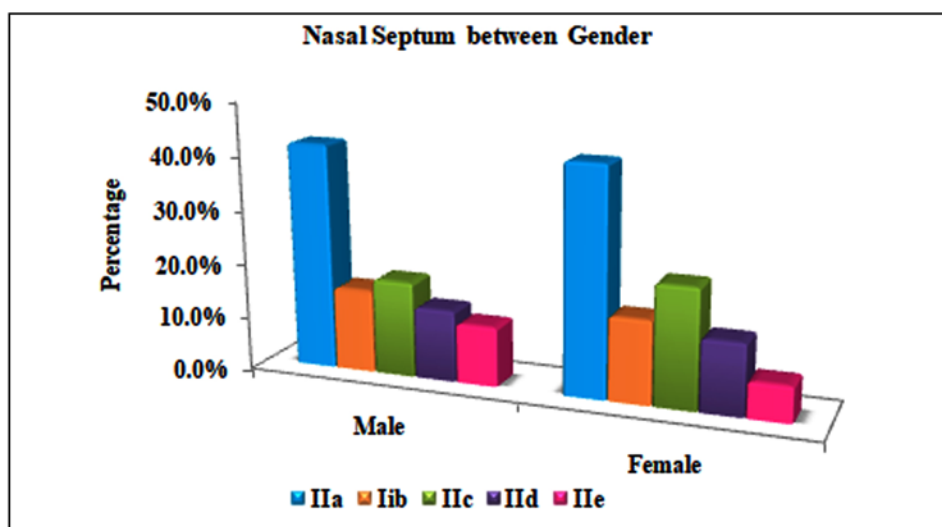
-			Gender		Total	2 - value	p-value
			Male	Female			
Sphenoid Sinus	III a	Count	37	24	61	9.574	0.008 **
		%	82.20%	53.30%	67.80%		
	III b	Count	6	11	17		
		%	13.30%	24.40%	18.90%		
	III c	Count	2	10	12		
		%	4.40%	22.20%	13.30%		
Total	Count	45	45	90			
	%	100.00%	100.00%	100.00%			

** Highly Statistical Significance at p < 0.01 level

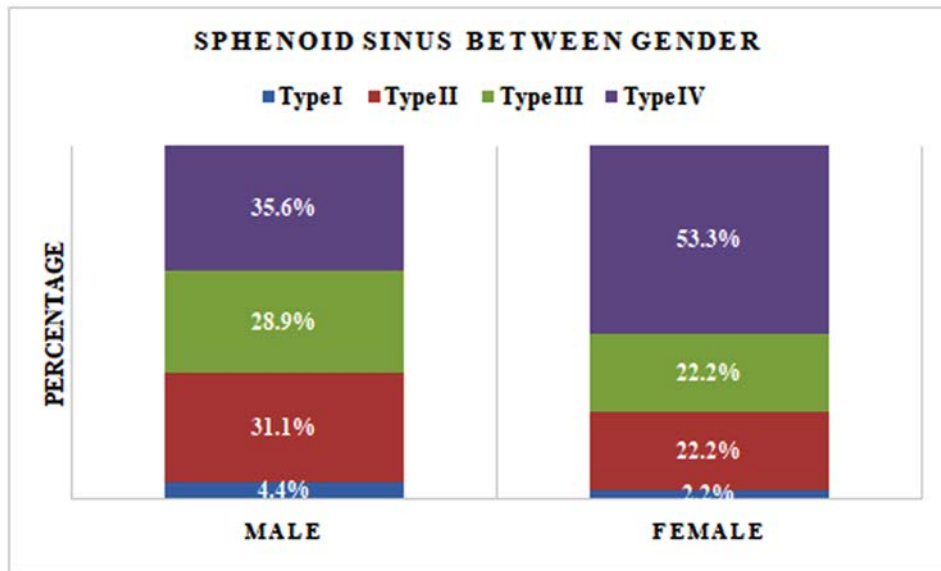
Graphs



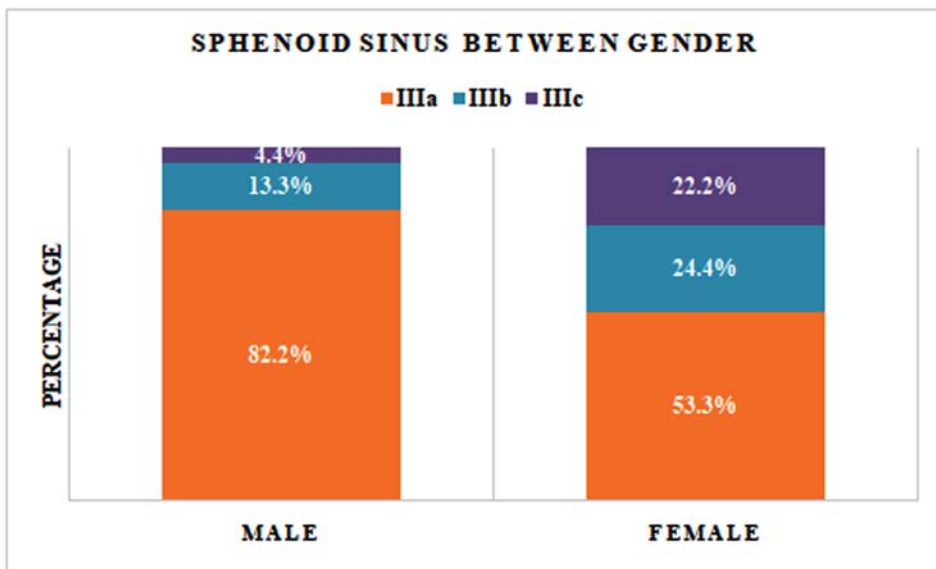
Graph 1: Comparison of frontal sinus between gender by pearson’s chi-square test



Graph 2: Comparison of nasal septum between gender by pearson’s chi-square test



Graph 3: Comparison of sphenoid sinus (sagittal slice) between gender by pearson’s chi-square test



Graph 4: Comparison of sphenoid sinus (axial slice) between gender by pearson’s chi-square test

DISCUSSION

Personal identification is defined as establishing the identity of an individual. The need for personal identification arises in natural mass disasters like earth quakes, tsunamis, landslides, floods etc., and in man-made disasters such as terrorist attacks, bomb blasts, mass murders, and in cases when the body is highly decomposed or dismembered to deliberately conceal the identity of the individual.²⁷ Identification using structures in the skull remains

the most widely used method for personal identification. Moreover, examination of the skull becomes the only tool for identification in burnt bodies and when the skull is the only found remain. The complexity of the skull anatomy allows for analysis of many structures like nasal cavity, paranasal sinuses, sellaturcica, zygomatic processes and mandible. In the present study, CBCT was utilized for skull imaging. The methodology applied for frontal sinus, nasal septum and sphenoid sinus examination was simple, easy and reproducible.

The results of the present study the Frontal Sinus

distribution were Symmetry is 60.0%, Asymmetry is 21.1%, Unilateral aplasia is 5.6%, Bilateral aplasia is 13.3%. Nasal Septum distribution were Straight is 42.2%, Right deviation is 15.6%, Left deviation is 20.0%, Sigmoid is 13.3%, Reverse sigmoid is 8.9%. Sphenoid Sinus distribution were conchal is 3.3%, presellar is 26.7%, sellar is 25.6%, post sellar is 44.4%. Sphenoid Sinus distribution were Absence of pneumatization of the pterygoid processes is 67.8%, Pneumatization of the right and the left pterygoid processes, and of the right anterior clinoid process is 18.9% and Both anterior clinoid and pterygoid processes are pneumatized is 13.3%. Characteristic individual variations have been noted in all the parameters which can be a useful tool for personal identification.

Taniguchi M, *et al.* 2003²⁸ suggested use of frontal sinus and nasal septum in personal identification and reported 204 different types of classification with high efficacy in identification with 95% probability. 43% symmetry in Japanese population, 56.6% asymmetry. Nasal septum straight in 13.4%, right deviation in 35.3%, left deviation in 37.6%, sigmoid in 6%, reverse sigmoid in 6.3%, other patterns in 1.4% which is in concordance with our study. Gopal KS, *et al.*²⁹ 2016 used CBCT images to establish pattern of frontal sinus and nasal septum and reported its possible applications for personal identification. Frontal sinus symmetry was observed in 43.75% individuals and asymmetry in 48.75%. Bilateral aplasia in 5% and Unilateral aplasia was seen in 2.5%. Straight nasal septum was seen in 33.75%, right deviation in 30%, and left deviation in 22.5% individuals. Sigmoid was seen in 5%, reverse sigmoid in 8.75%. which was in concordance with our study. MP David & Saxena, *et al.*³⁰ 2010 reported use of frontal sinus and nasal septum for personal identification. Out of 50 cases 9 cases were found to have identical pattern with 82% probability of positive personal identification.

CONCLUSION

This study demonstrated that CBCT visualization of anatomical aspects and the pneumatization of sphenoid sinuses can be used for personal identification. In our study, we observed that the frontal sinus and nasal septum patterns and sphenoid sinus had considerable individual variations and thus this study can be more reliable for personal identification. The usage of these parameters as seen in a full skull CBCT image can be used as one of the aids in personal identification. All three may vary person to person or even in

monozygotic twins. Severely damaged bodies can be difficult to identify, and various factors can delay the identification. In violent traumatic contexts, teeth and frontal sinuses can be missing, which limits their contribution to identification. Sphenoid sinuses, on the other hand, are better protected from traumatic degradation as they are deeply positioned in the center of the cranial base. Their pneumatization, well documented as extremely variable in degrees and directions, could contribute to the radiologic identification of a dead person.

REFERENCES

1. Pramod JB, Marya AV, Sharma V. Role of forensic odontologist in post mortem person identification. *Dental research journal.* 2013 May 1; 9(5).
2. Sidhu R, Chandra S, Devi P, Taneja N, Sah K, Kaur N. Forensic importance of maxillary sinus in gender determination: a morphometric analysis from Western Uttar Pradesh, India. *European Journal of General Dentistry.* 2014 Jan 1; 3(1):53.
3. David MP, Saxena R. Use of frontal sinus and nasal septum patterns as an aid in personal identification: A digital radiographic pilot study. *J Forensic Dent Sci.* 2010;2(2):77-80.
4. Disaster Victim Identification guide. Interpol 2014; 2014 [http://www.interpol.int/en/Internet/Interpol-expertise/Forensics/DVI].
5. Brown KA. Dental identification of unknown bodies. *Ann Acad Med Singapore* 1984;13(1):3–7.
6. Lorkiewicz-Muszynska D, Łabecka M, Zaba C, *et al.* Trudnośc identyfikacji zwłokiszczonek ludzkich w oparciu o dokumentację i badania stomatologiczne [Difficulties in identification of human corpses and skeletal remains on the basis of dental records and examinations]. *Arch Med Sadowej Kryminol* 2009;59(3):218–24.
7. Thali MJ, Markwalder T, Jackowski C, Sonnenschein M, Dirnhofer R. Dental CT imaging as a screening tool for dental profiling: advantages and limitations. *J Forensic Sci* 2006;51(1):113–9.
8. Pfaeffli M, Vock P, Dirnhofer R, *et al.* Post-mortem radiological CT identification based on classical ante-mortem X-ray examinations. *Forensic Sci Int* 2007;171(2–3):111–7.
9. Kanthem RK, Guttikonda VR, Yeluri S, Kumari G. Sex determination using maxillary sinus. *J Forensic Dent Sci* 2015;7(2):163–7.
10. Pasquier E, De Saint Martin Pernot L, Burdin V, Mounayer C, Le Rest C, Colin D, *et al.* Determination of age at death: assessment of an algorithm of age prediction using numerical three-dimensional CT data from pubic bones. *Am J Phys Anthropol* 1999;108(3):261–8.

11. Mehta M, Saini V, Nath S, Menon SK. CT scan images for sex discrimination – a preliminary study on Gujarati population. *J Forensic Radiol Imaging* 2015;3(1):43–8.
12. Štokovič N, Trkulja V, Dumić-Culeš I, Cukovič Bagič I, Lauc T, Vukičević S, *et al.* Sphenoid sinus types, dimensions and relationship with surrounding structures. *Ann Anat* 2016;203:69–76.
13. Vidya CS, Shamsundar NM. Computerized tomographic study of frontal sinus patterns in skulls of south Indian population. *Int J of Sci and Research Pub.* 2014;4(9):1-5.
14. Vidya CS, Shamsundar NM. Computerized tomographic study of frontal sinus patterns in skulls of south Indian population. *Int J of Sci and Research Pub.* 2014;4(9):1-5
15. Belaldavar C, Kotrashetti VS, Hallikerimath SR, Kale AD. Assessment of frontal sinus dimensions to determine sexual dimorphism among Indian adults. *J Forensic Dent Sci.* 2014;6(1):25-30
16. Taniguchi M, Sakoda S, Kano T, Zhu BL, Kamikodai Y, Fujita MQ, *et al.* Possible use of nasal septum and frontal sinus patterns to radiographic identification of unknown human remains. *Osaka City Med J.* 2003;49(1):31-38.
17. Dawidson I. Case reports and background: difficulties with identification—Sweden. *J Forensic Odontostomatol* 2011;29(1):44–50.
18. Byard RW, Gilbert JD, Kostakis C, Heath KJ. Circumstances of death and diagnostic difficulties in brushfire fatalities. *J Forensic Sci* 2012;57(4):969–72.
19. Barghouth G, Prior JO, Lepori D, *et al.* Paranasal sinuses in children: size evaluation of maxillary, sphenoid, and frontal sinuses by magnetic resonance imaging and proposal of volume index percentile curves. *EurRadiol* 2002;12(6):1451–8.
20. Scuderi AJ, Harnsberger HR, Boyer RS. Pneumatization of the paranasal sinuses: normal features of importance to the accurate interpretation of CT scans and MR images. *AJR Am J Roentgenol* 1993;160(5):1101–4.
21. Casselman JW. Le sphénoïde: anatomie. *J Neuroradiol* 2003;30(4):201–10.
22. Peele JC. Unusual anatomical variations of the sphenoid sinuses. *Laryngoscope* 1957;67(3):208–37.
23. Kazkayasi M, Karadeniz Y, Arikan OK. Anatomic variations of the sphenoid sinus on computed tomography. *Rhinology* 2005;43(2):109–14.
24. Sirikci A, Bayazit YA, Bayram M, *et al.* Variations of sphenoid and related structures. *EurRadiol* 2000;10(5):844–8.
25. Güldner C, Pistorius SM, Diogo I, *et al.* Analysis of pneumatization and neurovascular structures of the sphenoid sinus using cone-beam tomography (CBT). *ActaRadiol* 2012;53(2): 214–9.
26. Hatch GM, Dedouit F, Christensen AM, Thali MJ, Ruder TD. RADid: a pictorial review of radiologic identification using postmortem CT. *J Forensic Radiol Imaging* 2014;2:52–9, <http://dx.doi.org/10.1016/j.jofri.2014.02.039>
27. Modi JP (2011) *A Textbook of Medical Jurisprudence and Toxicology*, 24th Edn, LexisNexis Butterworths, Nodia
28. Taniguchi M, Sakoda S, Kano T, Zhu BL, Kamikodai Y, Fujita MQ, *et al.* Possible use of nasal septum and frontal sinus patterns to radiographic identification of unknown human remains. *Osaka City Med J.* 2003; 49: 31-8.
29. Gopal KS, Vijayan BP. Significance of Frontal Sinus and Nasal Septum Patterns in Personal Identification in Forensics: A Retrospective CBCT Study. *Int J Oral Health Med Res.* 2016; 2: 57-61
30. MP David, Saxena R. Use of Frontal sinus and nasal septum as an aid in personal identification: A digital radiographic pilot study. *J Forensic Dent Sci.* 2010; 2: 77-80
31. Auffret M, *et al.* Contribution of the computed tomography of the anatomical aspects of the sphenoid sinuses to forensic identification. *J Neuroradiol* (2016), <http://dx.doi.org/10.1016/j.neurad.2016.03.007>

